

Original article

Acute invasive fungal rhinosinusitis in pediatric patients with oncohematological diseases



Lorrane Caroline Braga Rodrigues , Alessandro Fernandes Guimaraes ,
Isamara Simas de Oliveira , Pedro Henrique Medici de Sousa ,
Roberta Maia de Castro Romanelli , Fabiana Maria Kakehasi ,
Karla Emília de Sá Rodrigues *

Hospital das Clínicas da Universidade Federal Minas Gerais (HC UFMG), Belo Horizonte, MG, Brazil

ARTICLE INFO

Article history:

Received 3 July 2020

Accepted 21 August 2020

Available online 9 November 2020

Keywords:

Pediatrics

Hematologic diseases

Febrile neutropenia

Invasive fungal infection

Fusarium

ABSTRACT

Introduction: Invasive fungal diseases represent important causes of morbidity and mortality among pediatric oncohematological patients. Acute invasive fungal rhinosinusitis is a rare and aggressive disease that occurs mainly in immunocompromised patients. The mortality rate is high and therefore, accurate and early diagnosis is essential.

Objectives: The aim of this study was to describe the frequency of acute invasive fungal rhinosinusitis among pediatric oncohematological patients and characterize them with confirmed diagnoses.

Methods: This was a retrospective study that analyzed the medical records of pediatric patients diagnosed with oncohematological diseases and suspected fungal infections, who were included after obtaining informed consent, from January to December 2017, in the pediatric unit of a tertiary university hospital. Data collected from medical record analysis included the following: underlying diagnosis, absolute neutrophil count, clinical presentation, culture and biopsy results, surgical procedures performed, survival and mortality.

Results: A total of 27 patients were evaluated, with three suspected cases of acute invasive fungal rhinosinusitis. Histopathological and microbiological analyses confirmed two cases. In both cases, the pathogen isolated in the culture was *Fusarium* sp. The two confirmed cases were female, aged 12 and 14 years, both with an absolute neutrophil count of 10 cells/ μ L. The underlying disease of the first patient was acute myeloid leukemia (subtype M5), whereas the second patient presented idiopathic bone marrow aplasia.

Conclusion: Both confirmed cases of acute invasive fungal rhinosinusitis presented with constitutional symptoms and signs of nasal and sinusitis inflammation. This demonstrates the importance of fever as a symptom in immunocompromised patients and it should prompt otorhinolaryngological investigation.

© 2020 Associação Brasileira de Hematologia, Hemoterapia e Terapia Celular. Published by Elsevier Editora Ltda. This is an open access article under the CC BY-NC-ND license (<http://creativecommons.org/licenses/by-nc-nd/4.0/>).

* Corresponding author at: Hospital das Clínicas da Universidade Federal Minas Gerais (HC UFMG), Belo Horizonte, MG, Brazil.

E-mail address: karlaemilia@ufmg.br (K.E. de Sá Rodrigues).

<https://doi.org/10.1016/j.htct.2020.08.016>

2531-1379/© 2020 Associação Brasileira de Hematologia, Hemoterapia e Terapia Celular. Published by Elsevier Editora Ltda. This is an open access article under the CC BY-NC-ND license (<http://creativecommons.org/licenses/by-nc-nd/4.0/>).

Introduction

Invasive fungal diseases (IFDs) represent important causes of morbidity and mortality among pediatric oncohematological patients. Early diagnosis and treatment of an IFD is associated with a better outcome and this requires the use of fast and precise methods that can support clinicians in its management.¹

Fungal rhinosinusitis (FRS) can be classified as invasive or noninvasive, based on the histopathological evidence of tissue invasion by the fungus, which results in necrosis and local tissue destruction. This invasive disease is subdivided into acute invasive FRS (AIFRS), granulomatous invasive FRS and chronic invasive FRS.^{2–4}

AIFRS is a rare and aggressive disease that occurs mainly in immunocompromised patients, particularly in those with neutropenia, with oncohematological diseases representing a major predisposing factor.^{4,5} Infection is characterized by fungal invasion of the nasal or paranasal cavity, which may affect adjacent organs, such as the orbits and intracranial structures.⁶ Numerous fungi can cause invasive infection, however, the most commonly identified fungi in AIFRS are *Aspergillus* and *Zygomycetes* (*Rhizopus*, *Mucor*, *Rhizomucor*).^{2,7–10}

The diagnosis is challenging and fever is often the only presenting symptom. Other signs and symptoms may be very slight due to the reduced local inflammatory response capacity, which is a consequence of neutropenia. The complications include delayed chemotherapy treatment that may result in cancer recurrence, bone erosion, orbital invasion, brain abscess, meningitis, hematogenous spread and death. The mortality rate is high, ranging from 20 to 80% and therefore, accurate and early diagnosis is essential.^{5,7,11–13}

The aim of this study was to assess the frequency of AIFRS among pediatric oncohematological patients evaluated by the otorhinolaryngology service and determine the characteristics of patients with confirmed diagnoses.

Methods

The study was approved by the Institutional Research Ethics Committee (number 1.425.036) and participants were included after proxy informed consent was obtained from the children's guardians.

Patients diagnosed with malignant neoplasia or aplastic anemia from January to December 2017 were included.

Inclusion criteria were patients aged less than 18 years, hospitalized for the treatment of oncohematological diseases and who exhibited indications for otorhinolaryngological evaluation and possible infection, as well as neutropenia (a neutrophil count of $<500/\mu\text{L}$ or $<1,000/\mu\text{L}$, with a tendency to undergo further decrease), fever (axillary temperature $\geq 37,8^\circ\text{C}$) and/or nasosinus symptoms.

Medical record analysis collected the following data: underlying diagnosis, absolute neutrophil count, clinical presentation, culture and biopsy results, surgical procedure performed and clinical outcome.

The medical records were reviewed and the data were collected by a multidisciplinary team responsible for the routine

care of oncohematological patients. In this period, the team met regularly to discuss and standardize data registration in a previously prepared form. All study members were trained in data collection and regular meetings were held to discuss methodology and findings.

Results

In total, 27 patients were evaluated and among three suspected cases of AIFRS, two cases (7.41% 95% CI: 0.9–24.3) were confirmed with histopathological and microbiological evidence of fungal infection (Table 1). The unconfirmed patient died before undergoing the surgical approach.

The two confirmed cases of AIFRS were female, aged 12 and 14 years, and both had an absolute neutrophil count of $10\text{ cells}/\mu\text{L}$. The first patient (P1) had acute myeloid leukemia (subtype M5) as an underlying disease and was in the induction phase of the treatment, with an interval of 15 days between the beginning of chemotherapy and the first otorhinolaryngological evaluation. The second patient (P2) was diagnosed with severe aplastic anemia.

Fever, hyaline rhinorrhea and nasal crusting were the symptoms observed in the two patients with confirmed diagnoses. Patient P1 presented with fever recurrence after 12 days of being afebrile under meropenem treatment for 14 days. Patient P2 presented with persistent fever for 23 days, despite the use of meropenem, polymyxin, liposomal amphotericin, linezolid and micafungin (Table 1).

In both cases, the sites of nasal involvement were the anterior septum, associated with a lesion in the left inferior turbinate or right middle turbinate, with direct examination revealing adhered crusts and pale mucosa. However, patient P2 had evolved to necrosis at the time of surgery. Only patient P1 underwent sinus computed tomography, which revealed nonspecific findings of mucosal thickening of the maxillary, frontal and sphenoid sinuses.

Both patients received treatment with a systemic antifungal (liposomal amphotericin and liposomal amphotericin associated with micafungin) and surgical debridement. No granulocyte colony-stimulating factor was used. The surgical samples removed were sent for histopathological examination and culture. In both cases, the pathogen isolated in the cultures was *Fusarium* sp. Histopathological evaluation revealed respiratory mucosa with areas of necrosis and the presence of numerous filamentous fungi with hyaline, acute-branching septate hyphae.

Weekly postoperative follow-up was performed, with nasosinus endoscopy in P1, until neutrophil recovery. Recurrent infection or post-operative complications, such as pain, vomiting, bleeding, infection, abscess, or synechiae were not observed. Patient P2 died 6 days after surgery with septic shock and multiple-organ failure.

Discussion

AIFRS is a severe opportunistic infection with high morbidity and mortality that usually occurs in immunosuppressed patients. Risk factors include hematologic malignancies and aplastic anemia, which lead to the reduction in, and dysfunc-

Table 1 – Clinical/laboratory data of patients in a retrospective cohort of immunocompromised patients at a cancer reference center.

Patient	Age	Sex	Diagnosis	Number of ORL evaluations	Main reason for the evaluation	ORL symptoms	ORL evaluation findings	CRP mg/L	Absolute neutrophil count (cells × 10 ³ /μL)	Platelet count (× 10 ³ /μL)	GMN ^a at the ORL evaluation	Outcome
1	12	Female	AML; AIFRS	11	Fever persistence or recurrence and ORL symptoms	Rhinorrhea	Paleness and crusting of septum and middle turbinate	135	0,01	63	NP	Infection resolved
2	14	Female	BMA; AIFRS	3	Fever persistence or recurrence and ORL symptoms	Crusting	Paleness, Crusting, and Necrosis of Septum and Inferior turbinate	414	0,01	29	4.12	Death
3	1	Male	AML	1	Fever persistence or recurrence	No	Normal	170.72	0,03	15	0,13	Discharged by the ORL clinic
4	16	Male	NHL	2	ORL symptoms	Rhinorrhea, posterior nasal discharge and cough	Normal	NP	6,170	177	NP	Discharged by the ORL clinic
5	8	Male	NHL	4	Fever persistence or recurrence	No	Paleness of the middle turbinate	89.36	0	36	0.39	Discharged by the ORL clinic
6	5	Male	RMS	2	Fever persistence or recurrence	No	NP	34.97	0,06	355	NP	Discharged by the ORL clinic
7	10	Female	RMS	2	Fever persistence or recurrence	No	Normal	NP	0,13	416	0.5	Discharged by the ORL clinic
8	14	Male	ALL	2	Fever persistence or recurrence and ORL symptoms	Cough	Paleness of the middle turbinate and nasal septum	383.41	0,01	8	NP	Death
9	12	Male	Fanconi's anemia	1	Fever persistence or recurrence and ORL symptoms	Rhinorrhea, nasal congestion and nasal sinus pain	NP	NP	8,33	16	NP	Discharged by the ORL clinic

– Table 1 (Continued)

Patient	Age	Sex	Diagnosis	Number of ORL evaluations	Main reason for the evaluation	ORL symptoms	ORL evaluation findings	CRP mg/L	Absolute neutrophil count (cells × 10 ³ /μL)	Platelet count (×10 ³ /μL)	GMN ^a at the ORL evaluation	Outcome
10	15	Male	ALL	1	Fever persistence or recurrence	No	NP	168.19	0	37	NP	Infection resolved
11	13	Male	AML	1	ORL symptoms	Cough	Normal	NP	0,98	324	NP	Discharged by the ORL clinic
12	7	Female	MDS	1	ORL symptoms	Rhinorrhea, nasal congestion, cough and nasal sinus pain	Normal	NP	0,280	27	NP	Discharged by the ORL clinic
13	7	Male	ALL	3	Fever persistence or recurrence and ORL symptoms	Rhinorrhea, cough and headache	Hyalin secretion on nasal floor	321.51	0,050	31	0.09	Discharged by the ORL clinic
14	8	Male	ALL	5	Fever persistence or recurrence and ORL symptoms	Rhinorrhea, nasal congestion and cough	Bilateral mucoid crusts On the left nasal septum	226.15	0,020	29	3.2	Death
15	15	Female	MDS	1	Fever persistence or recurrence and ORL symptoms	Rhinorrhea, nasal congestion and nasal sinus pain	Mucosal edema and hyalin secretion on nasal floor	87.03	1,740	97	NP	Discharged by the ORL clinic
16	5	Male	ALL	1	Fever persistence or recurrence and ORL symptoms	Rhinorrhea and cough	Hyalin secretion on nasal floor and congestion of the inferior turbinate	187.19	0,550	240	0.33	Discharged by the ORL clinic
17	5	Female	MDS	1	Fever persistence or recurrence and ORL symptoms	Rhinorrhea, cough and headache	Hyalin secretion on the middle turbinate	46.68	0,038	429	NP	Discharged by the ORL clinic
18	10	Female	NBL	1	Fever persistence or recurrence and ORL symptoms	Rhinorrhea and cough	NP	43.45	0,01	22	NP	Discharged by the ORL clinic

– Table 1 (Continued)

Patient	Age	Sex	Diagnosis	Number of ORL evaluations	Main reason for the evaluation	ORL symptoms	ORL evaluation findings	CRP mg/L	Absolute neutrophil count (cells × 10 ³ /μL)	Platelet count (×10 ³ /μL)	GMN ^a at the ORL evaluation	Outcome
19	14	Female	ALL	1	Fever persistence or recurrence and ORL symptoms	No	Normal	NP	0,19	34	NP	Discharged by the ORL clinic
20	14	Male	NHL	1	ORL symptoms	Rhinorrhea, nasal congestion, cough, nasal sinus pain and sneezing	Hyalin secretion on nasal floor and congestion of the Inferior turbinate	78.07	4,7	371	NP	Discharged by the ORL clinic
21	12	Male	AML	1	ORL symptoms	Rhinorrhea and cough	Hyalin secretion on the middle meatus and congestion of the inferior turbinate	NP	0,470	20	NR	Discharged by the ORL clinic
22	13	Female	Fanconi's anemia	2	Fever persistence or recurrence and ORL symptoms	Cough	NP	168.67	0,06	1	NP	Death
23	7	Female	AML	2	Fever persistence or recurrence and ORL symptoms	Nasal congestion, cough, nasal sinus pain	Normal	248.7	0,05	13	0,13	Discharged by the ORL clinic
24	10	Female	BMA	7	Fever persistence or recurrence and ORL symptoms	Cough	Normal	147.42	0	7	0.11	Discharged by the ORL clinic
25	14	Female	AML	12	Fever persistence or recurrence and ORL symptoms; previous RSFIA	Nasal bleeding	Diffuse pallor, hematic crust on nasal floor	NP	0,02	36	NP	Discharged by the ORL clinic
26	16	Female	LNH	2	ORL symptoms	Rhinorrhea, posterior nasal Discharge and sneezing	Purulent secretion in right middle meatus	20.83	2,470	248	NP	Discharged by the ORL clinic
27	3	Male	BMA	1	Fever persistence or recurrence	No	Normal	155.67	0,07	16	NP	Discharged by the ORL clinic

AML: acute myeloid leukemia; AIFRS: acute invasive fungal rhinosinusitis; ORL: otorhinolaryngology; BMA: bone marrow aplasia; NHL: non-Hodgkin' lymphoma; RMS: rhabdomyosarcoma; ALL: acute lymphoblastic leukemia; MDS: myelodysplastic syndrome; NBL: neuroblastoma; CRP: C-reactive protein, PLAT: platelets, NP: not performed.

^a GALACTOMANNAN, ANTIGENO ASPERGILLUS, Method: Enzyme Immunoassay (ELISA), REFERENCE VALUES: NEGATIVE SERUM: less than 0.5.

tion of, neutrophils.²⁻⁵ As in adults, the most important risk factor in pediatric patients is hematologic neoplasia, probably due to the long periods of intense neutropenia that these patients often experience during their treatment.^{6,7}

Upper airway fungal infection should be investigated whenever a neutropenic patient continues to exhibit persistent or recurrent fever after 4–7 days of broad-spectrum antibiotic therapy or exhibits signs and symptoms suggestive of airway infection, such as persistent cough, rhinorrhea and nasal obstruction.¹⁴

The most common initial symptoms of AIFRS are fever, nasal discharge, facial pain, rhinorrhea and nasal congestion.^{11,15,16} Similarly, we observed nonspecific early symptoms including fever, hyaline rhinorrhea and nasal crust formation. Visual and neurological symptoms, such as ophthalmoplegia, proptosis, orbital cellulitis, visual loss, changes in mental status and palate erosion, are signs of an extensive disease and indicate orbital or intracranial invasion.¹⁷⁻¹⁹

The presence of such symptoms in immunocompromised patients is the condition requiring mandatory nasal endoscopy, which can be performed with a flexible nasofibroscope or a rigid endoscope. Suggestive findings include discoloration or blackening (a sign of ischemia), edema, ulcerations, granulation and crusting of the mucosa, vestibule or columella. In cases of suspected extra-sinusal extension of the disease, paranasal sinus computed tomography is the appropriate tool for proper surgical planning. However, it reveals nonspecific changes in the early phase of the disease, such as unilateral thickening of the nasal cavity or paranasal sinuses. If orbital or cranial invasion is suspected, nuclear magnetic resonance becomes essential.^{3,11}

The definitive diagnosis of AIFRS is established by culture and histopathological evaluation, which can reveal tissue invasion by hyphae.² Whenever possible, treatment consists of reversing immunosuppression, discontinuing chemotherapy and using granulocyte colony-stimulating factor, combined with antifungal therapy and urgent surgical intervention, which involves aggressive debridement and resection of the entire affected area.^{3,7}

First symptoms of AIFRS are often nonspecific, which contributes to the difficulty in making an early diagnosis, especially among children who are not able to describe their symptoms in detail.^{2,8} In this study, the two cases occurred in adolescents, both showing increased inflammatory marker C-reactive protein (444 and 135 mg/dL) and thrombocytopenia (29,000 and 63,000 platelets/ μ L). The galactomannan test was only performed on patient P2 (4,12) and, despite decreasing, it remained altered and positive until death.

The main etiological agent described for AIFRS in oncologic and hematological patients is *Aspergillus*. These microorganisms are saprophytes that are found in decomposed substances, soil and fruits, as well as in the throat, nasal cavities and feces of healthy individuals, but can become pathogenic in immunocompromised patients.^{2,9} In this report, samples from both cases were sent for culture and the infectious agent *Fusarium* sp. was identified in both cases. This was also the most commonly isolated fungus in a pediatric series of AIFRS reported by Park et al. and Vinh et al.^{15,20} However, Ardeshirpour et al. identified *Alternaria* as the causative agent,

whereas Tarkan et al. identified *Mucor* as the causative agent in eight out of 13 pediatric oncohematological patients.^{21,22} A similar report by Yakirevitch et al. examined 13 children and identified *Mucor* (in five patients), *Aspergillus* (in five patients), *Mucor* and *Aspergillus* (in one patient), *Exserohilum rostratum* (in one patient) and *Fusarium* (in one patient).²³

Fusarium species have emerged as responsible for a broad spectrum of infections, including superficial, locally invasive and disseminated ones, especially in the hospital environment, where reservoirs of infectious species have been reported, especially in the plumbing and water systems.²⁴⁻²⁷

Fusariosis in immunocompromised patients, mainly children, is usually an invasive and frequently serious disseminated disease, which is the most frequent and challenging clinical form of this infection, accounting for approximately 70% all cases.²⁴ The upper respiratory tract is the main entrance for *Fusarium* spp., followed by the skin mucosal membranes. Various organs can be affected, including nasal cavities, sinuses, lungs, joints, retina, liver, spleen and kidneys.^{28,29}

The incidence of invasive fusariosis in immunosuppressed patients is variable. An epidemiologic study conducted at eight Brazilian centers between 2007 and 2009 reported a 1-year cumulative incidence of 5.2% among allogeneic hematopoietic cell transplant recipients and of 3.8% in patients with acute myeloid leukemia.³⁰ Incidence of invasive fusariosis here seems higher than that reported in other regions of the world and it is not clear why.

Acute leukemia and T-cell immunodeficiency, in addition to prolonged and deep neutropenia, is one of the main risk factors for invasive fusariosis.³¹ In our study, the underlying disease was acute myeloid leukemia and severe aplastic anemia and all of the patients presented febrile neutropenia.

Gillespie et al. described the most frequently affected locations as follows (in order of frequency): the middle concha, septum, hard palate, and inferior turbinate.¹¹ Here, discoloration, crusting or granulation were more common findings than ulcerations. Similarly, the most commonly affected locations found by Tarkan et al. were the middle concha and the septum.²² In the present study, the most affected locations were the nasal septum, middle turbinate and inferior turbinate.

A study by Vinh et al. examined all causes of mortality and demonstrated a survival rate of 59% at 30 days and 41% at 6 months.²⁰ Gillespie et al. observed 25 patients, of whom 10 recovered, 9 died due to the disease and 6 died due to other causes.¹¹ On the contrary, Ardeshirpour et al. reported a cure of all 11 patients (100%) without relapse, but three patients eventually died from unrelated causes.²¹ In our case series, one patient with acute myeloid leukemia was considered cured, with no evidence of recurrent fungal infection after one year of follow-up. The clinical outcome of the patient diagnosed with aplastic anemia was death due to other causes besides RSFIA.

It is recommended that after surgery and while neutropenia is still present, a nasosinusal endoscopic follow-up of AIFRS patients be performed weekly. After neutrophil count recovery, such a follow-up should be performed monthly for

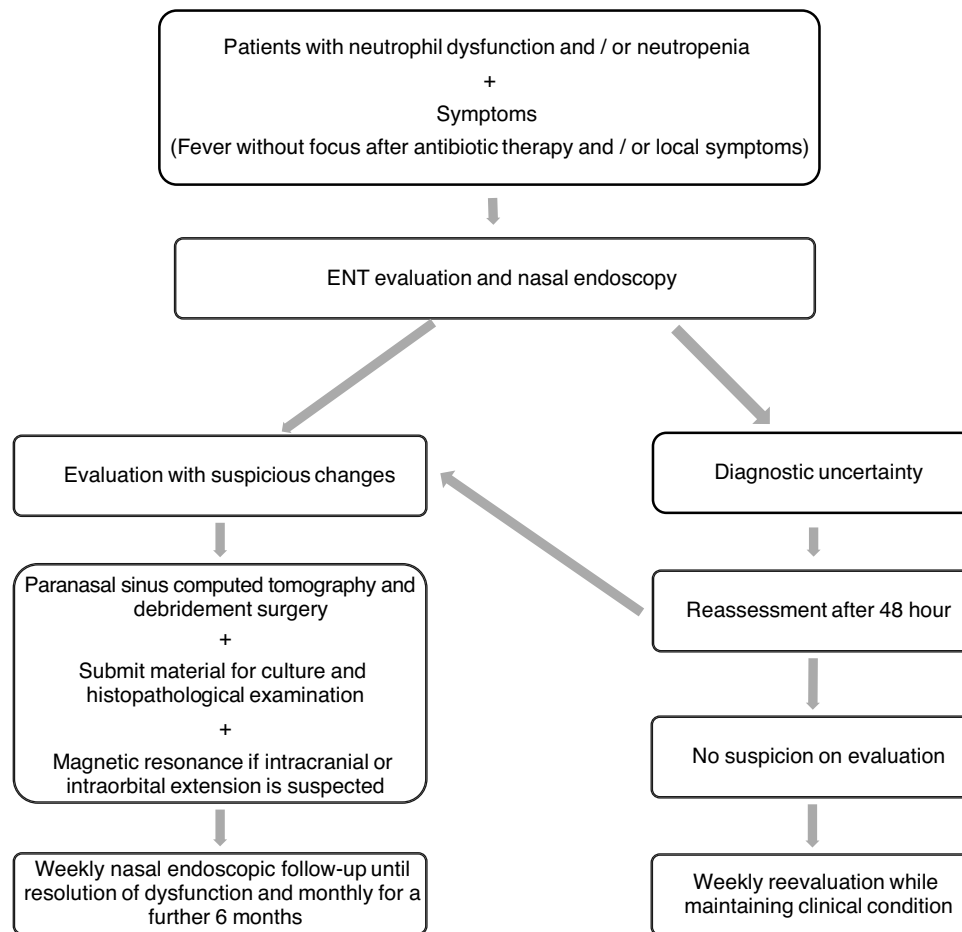


Figure 1 – Flowchart for management of neutropenic patients suspected of invasive fungal infection.

an additional six months.³¹ At our service, this follow-up protocol is performed by the pediatrician and the oncologist who administers the associated systemic antifungal therapy. This study helped define the management protocol that will be followed at this service (Figure 1).

Conclusion

In this chart review, AIFRS was observed in 7.4% of onco-hematological pediatric patients assessed with suspected fungal infection at our hospital. They presented with minor local signs of nasal and sinusitis inflammation, as well as constitutional signs and symptoms. This demonstrates the importance of fever as a symptom and that it should prompt otorhinolaryngological investigation in immunocompromised patients, especially considering they have a higher potential of fungal infection. Prompt assessment and management are crucial to decrease morbidity and mortality. AIFRS should be considered in all patients with an immunosuppressive disease with fever or nasosinusitis symptoms, especially in the presence of septal mucosa and turbinate changes, such as discoloration or blackening, edema, ulcerations, granulation and crusting. We are currently expanding the study population for future studies.

Conflicts of interest

The authors declare no conflicts of interest.

Acknowledgments

We would like to thank Editage (www.editage.com) for English language editing.

REFERENCES

1. Saffioti C, Mesini A, Bandettini R, Castagnola E. Diagnosis of invasive fungal disease in children: a narrative review. *Expert Rev Anti Infect Ther.* 2019;13:1-15.
2. deShazo RD, O'Brien M, Chapin K, Soto-Aguilar M, Gardner L, Swain R. A new classification and diagnostic criteria for invasive fungal sinusitis. *Arch Otolaryngol Head Neck Surg.* 1997;123:1181-8.
3. Pignatari SSN, Anselmo-Lima WT. *Otorhinolaryngology treaty.* Rio de Janeiro: Elsevier; 2018.
4. Wiley A, Schell MS. Histopathology of fungal rhinosinusitis. *Otolaryngol Clin North Am.* 2000;33, 251-27.
5. Chen CY, Sheng WH, Cheng A, Chen CY, Tsay W, Tang JL, et al. Invasive fungal sinusitis in patients with hematological

- malignancy: 15 years experience in a single university hospital in Taiwan. *BMC Infect Dis.* 2011;11:250–9.
6. Drakos PE, Nagler A, Or R, Naparstek E, Kapelushnik J, Engelhard D, et al. Invasive fungal sinusitis in patients undergoing bone marrow transplantation. *Bone Marrow Transplant.* 1993;12:203–8.
 7. Turner JH, Soudry E, Nayak JV, Hwang PH. Survival outcomes in acute invasive fungal sinusitis: a systematic review and quantitative synthesis of published evidence. *Laryngoscope.* 2013;123:1112–8.
 8. Rhizopus, Rhizomucor, Absidia, and other agents of systemic and subcutaneous zygomycosis. Richardson MD, Koukila-Kähkölä P, Murray PR, Baron EJ, Jorgensen JH, Landry ML, et al., editors. *Manual of clinical microbiology.* 9th ed. Washington: ASM Press; 2007.
 9. Brandwein M. Histopathology of sinonasal fungal disease. *Otolaryngol Clin North Am.* 1993;26:949–81.
 10. Monroe MM, McLean M, Sautter N, Wax MK, Andersen PE, Smith TL, et al. Invasive fungal rhinosinusitis: a 15-year experience with 29 patients. *Laryngoscope.* 2013;123:1583–7.
 11. Gillespie MB, O'Malley BW, Francis HW. An approach to fulminant invasive fungal rhinosinusitis in the immunocompromised host. *Arch Otolaryngol Head Neck Surg.* 1998;124:520–6.
 12. Kennedy CA, Adams GL, Neglia JP, Giebink GS. Impact of surgical treatment on paranasal fungal infections in bone marrow transplant patients. *Otolaryngol Head Neck Surg.* 1997;116:610–6.
 13. Del Gaudio JM, Clemson LA. An early detection protocol for invasive fungal sinusitis in neutropenic patients successfully reduces extent of disease at presentation and long-term morbidity. *Laryngoscope.* 2009;119:180–3.
 14. Rejin K, Hande K. Febrile neutropenia in children with cancer: approach to diagnosis and treatment. *Curr Pediatr Rev.* 2018;14:204–9.
 15. Park AH, Muntz HR, Smith ME, Afify Z, Pysker T, Pavia A. Pediatric invasive fungal rhinosinusitis in immunocompromised children with cancer. *Otolaryngol Head Neck Surg.* 2005;133:411–6.
 16. Kasapoglu F, Coskun H, Ozmen OA, Akalin H, Ener B. Acute invasive fungal rhinosinusitis: evaluation of 26 patients treated with endonasal or open surgical procedures. *Otolaryngol Head Neck Surg.* 2010;143:614–20.
 17. Gillespie MB, O'Malley BW. An algorithmic approach to the diagnosis and management of invasive fungal rhinosinusitis in the immunocompromised patient. *Otolaryngol Clin North Am.* 2000;33:323–34.
 18. Ketenci I, Unlü Y, Kaya H, Somdaş MA, Kondaş O, Oztürk M, et al. Rhinocerebral mucormycosis: experience in 14 patients. *J Laryngol Otol.* 2011;125:e3.
 19. Anselmo-Lima WT, Lopes RP, Valera FC, Demarco RC. Invasive fungal rhinosinusitis in immunocompromised patients. *Rhinology.* 2004;42:141–4.
 20. Vinh D, Yim M, Dutta A, Jones JK, Zhang W, Sittton M. Pediatric invasive fungal rhinosinusitis: an investigation of 17 patients. *Int J Pediatr Otorhinolaryngol.* 2017;99:111–6.
 21. Ardeshirpour F, Bohm LA, Belani KK, Sencer SF, Lander TA, Sidman JD. Surgery for pediatric invasive fungal sinonasal disease. *Laryngoscope.* 2014;124:1008–12.
 22. Tarkan O, Karagün B, Ozdemir S, Tuncer U, Sürmelioglu O, Cekiç E, et al. Endonasal treatment of acute invasive fungal rhinosinusitis in immunocompromised pediatric hematology–oncology patients. *Int J Pediatr Otorhinolaryngol.* 2012;76:1458–64.
 23. Yakirevitch A, Barg AA, Bedrin L, Primov-Fever A, Wolf M, Migirov L. Acute invasive fungal rhinosinusitis in children with hematologic malignancies: outcome of surgical treatment. *Pediatr Hematol Oncol.* 2015;32:568–75.
 24. Nucci M, Anaissie E. Fusarium infections in immunocompromised patients. *Clin Microbiol Rev.* 2007;20:695–704.
 25. Litvinov N, da Silva MT, van der Heijden IM, Graça MG, Marques de Oliveira L, Fu L, et al. An outbreak of invasive fusarium in a children's cancer hospital. *Clin Microbiol Infect.* 2015;21:1–7.
 26. Short DPG, O'Donnell K, Zhang N, Juba JH, Geiser DM. Widespread occurrence of diverse pathogenic types of the fungus *Fusarium* in bathroom plumbing drains. *J Clin Microbiol.* 2011;49:4264–72.
 27. Sautour M, Edel-Hermann V, Steinberg C, Sixt N, Laurent J, Dalle F, et al. *Fusarium* species recovered from the water distribution system of a French university hospital. *Int J Hyg Environ Health.* 2012;215:286–92.
 28. Arnoni MV, Paula CR, Auler ME, Simões CCN, Nakano S, Szesz MW, et al. Infections caused by *Fusarium* species in pediatric cancer patients and review of published literature. *Mycopathologia.* 2018;183:941–9.
 29. Nucci M, Anaissie EJ, Queiroz-Telles F, Martins CA, Trabasso P, Solza C, et al. Outcome predictors of 84 patients with hematologic malignancies and *Fusarium* infection. *Cancer.* 2003;98:315–9.
 30. Nucci M, Garnica M, Gloria AB, Lehugeur DS, Dias VCH, Palma LC, et al. Invasive fungal diseases in haematopoietic cell transplant recipients and in patients with acute myeloid leukemia or myelodysplasia in Brazil. *Clin Microbiol Infect.* 2013;19:745–51.
 31. Nucci M, Anaissie J. Cutaneous infection by *Fusarium* species in healthy and immunocompromised hosts: implications for diagnosis and management. *Clin Infect Dis J.* 2002;35:909–20.