

Synchronous Bilateral Warthin Tumors: A Case Report

Luiz Augusto Nascimento¹ Julia Alessandra Santos Ferreira² Raquel Baptista Pio²
Gustavo Henrique Soares Takano³ Hécio Luiz Miziera⁴

¹ Department of Otolaryngology Head and Neck Surgery, Hospital Universitário de Brasília (UnB), Brasília/DF, Brazil

² Student, Department of Medicine, Universidade Católica de Brasília, Brasília/DF, Brazil

³ Master Degree, Department of Medical Pathology, Hospital Universitário de Brasília, Brasília/DF, Brazil

⁴ Doctor Degree, Department of Medical Pathology, Universidade Católica de Brasília, Brasília/DF, Brazil

Address for correspondence Luiz Augusto Nascimento, MD, PhD, Hospital Universitário de Brasília, SGAN 605, Av. L2 Norte Brasília/DF, CEP 70840901, Brazil (e-mail: luizaugusto.hns@gmail.com).

Int Arch Otorhinolaryngol 2014;18:217–220.

Abstract

Introduction Warthin tumor is described as papillary cystadenoma lymphomatosum and is the second most common tumor of the parotid glands. Bilateral synchronous incidence is rare, occurring in 7 to 10% of the cases. It is more common in males between 60 and 70 years of age and is closely related to smoking. There is slow growth and the condition is a delimited nodule of regular outlines; it has low rates of malignant progression and recurrence.

Objective Report a case of synchronous bilateral Warthin tumor occurring in an elderly patient, and review incidence and peculiarities of this tumor.

Resumed Report A 78-year-old man who used to smoke had a history of mild pain in the topography of right parotid three weeks ago. Patient with hypertension, diabetes and a longtime smoker (smoking a pack per day for 32 years) noticed a progressive bulging in the right parotid region for about 2.5 years ago, and noticed another progressive bulging (although in the left parotid region), for about one year ago. Patient denied fever, redness, skin lesions and pain during this period until last three weeks, when he sought medical attention for a mild pain in the right facial region. The patient underwent cervical magnetic resonance imaging that showed tumor lesions in both parotids. Fine needle aspiration revealed a typical lesion of epithelial oxyphilic cells associated with reactive lymphoid proliferation, suggesting Warthin tumor. The patient underwent two superficial parotidectomies, and the histopathologic result from both tumors of parotid glands showed papillary cystadenoma lymphomatosum.

Conclusion The occurrence of synchronous bilateral Warthin tumor is extremely rare, and anamnesis and physical examination, as well as some complementary examinations, are important means for diagnostic evaluation. Confirmation of the diagnosis can only be obtained through a histopathologic study. A superficial or total parotidectomy is the recommended treatment for the disease.

Keywords

- ▶ cystadenoma
- ▶ papillary
- ▶ salivary glands
- ▶ neoplasms
- ▶ multiple primary

received
October 24, 2012
accepted
February 18, 2013

DOI <http://dx.doi.org/10.1055/s-0033-1351676>.
ISSN 1809-9777.

Copyright © 2014 by Thieme Publicações Ltda, Rio de Janeiro, Brazil

License terms



Introduction

Salivary gland tumors represent ~3% of all head and neck tumors.¹ Warthin tumor (papillary cystadenoma lymphomatousum) is the second most common benign tumor of the parotid gland, representing 5 to 12% of all tumors of the salivary glands.²⁻⁵ This tumor is more prevalent in men (10:1) in the sixth to seventh decades of life and is described predominantly in white subjects, less frequently in Oriental subjects, and rarely in black subjects.⁶ Its pathogenesis is not yet completely understood, but there is an intrinsic relationship with smoking.⁵⁻⁸ Generally, the patient starts the clinical picture with a complaint of a painless nodule that is slow-growing, but progressive, in the region of the angle of the mandible.

Warthin tumor may present as unilateral or bilateral, synchronous or metachronous. Bilateral tumors are more infrequent and occur in 7 to 10% of the cases, and multifocal tumors and recurrences occur in ~2% of the cases,² with rare malignant transformation. Most of the bilateral tumors are metachronous, with a few cases of synchronous bilateral tumors reported in the literature. The following case report describes the case of an individual of 78 years with a synchronous bilateral Warthin tumor.

Case Report

A 78-year-old man who used to smoke had a history of mild pain in the topography of right parotid three weeks ago; however, a painless bulge was noticed in the right parotid region 2.5 years previously and another painless bulge was noticed in left parotid region almost a year ago. The patient denied fever, redness, and skin lesions but complained of mild pain in the right facial region that started about 3 weeks ago. Physical examination revealed an ~2-cm mass near the right parotid and an ~2.5-cm mass near the left parotid, both of them smooth, mobile, slightly painful on palpation, not adhering to deep planes, well defined, and without associated cervical lymph nodes. The patient did not show facial nerve deficit or any other motor deficit. He was then subjected to fine needle aspiration (FNA) of the tumor of the right parotid gland, which indicated a cytopathologic result of lesion of typical oxyphilic epithelial cells, associated with reactive lymphoid proliferation (and being able to correspond to Warthin tumor).

Cervical magnetic resonance image (MRI) showed tumors in the right and left parotids measuring 2.0 cm and 2.5 cm, respectively, in their largest diameters (►Figs. 1, 2).

With an intention of carrying out a superficial parotidectomy, this procedure was performed first on the side with the larger tumor (left) and, after 4 months, a tumor resection was performed on the right side. Both surgical procedures were performed as superficial parotidectomies with preservation of the facial nerve and intraoperative neural monitoring (Viasys Endeavor CR monitor, with 16 channels).

In the immediate postoperative period of the first surgical procedure, there were no complications or facial nerve paresis in any of its branches. In the second postoperative surgical

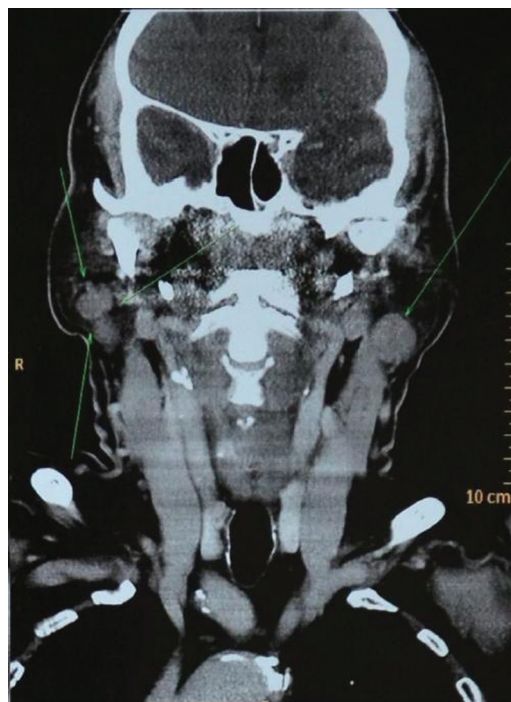


Fig. 1 Magnetic resonance image.

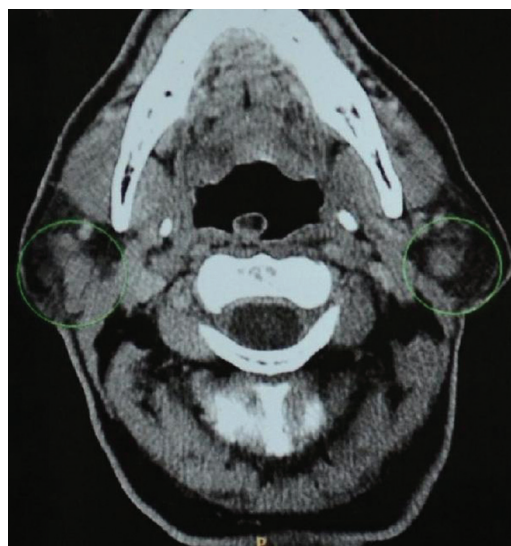

Fig. 2 Magnetic resonance image.

period (right side), the patient developed temporary paralysis grade II ocular and grade III marginal mandibular, according to the Blackman-House scale. The individual underwent motor rehabilitation exercises with total motor recovery in 6 months.

The histopathologic results showed papillary cystadenoma lymphomatousum in both parotid tumors (►Figs. 3, 4).

Discussion

Warthin tumor, today also known as *papillary cystadenoma lymphomatousum*, was first observed in 1895 by Hildebran,

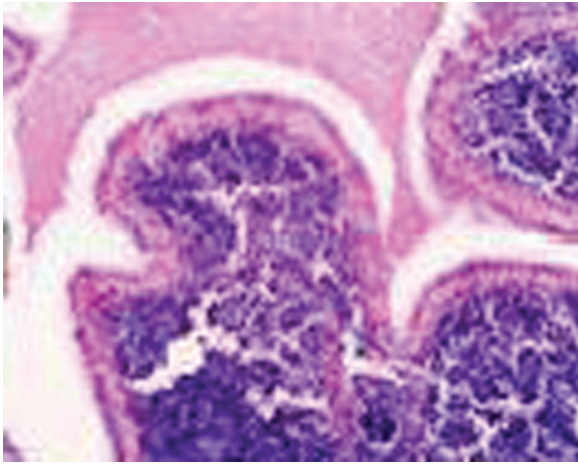


Fig. 3 Left parotid tumor. Papilla with lymphomatoid center and oncocytic coating ($20\times$, hematoxylin and eosin).

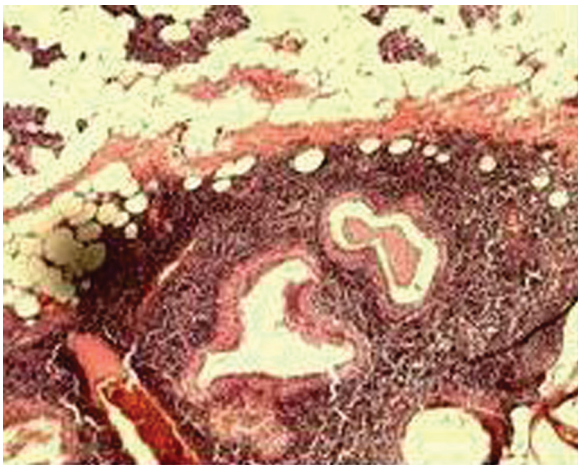


Fig. 4 Right parotid tumor. Papillary projections coated by oncocytic cells upon a lymphocytic stroma. These projections penetrate in cystic areas ($20\times$, hematoxylin and eosin).

who considered it a variant of a congenital cyst of the neck.² In 1929, Alfred Scott Warthin systematically reviewed all parotid tumors and brachial cervical cysts recorded over a period of 35 years at the University of Michigan. In two cases, which were called *papillary cystadenoma lymphomatous*, the condition was believed to be a rare form of parotid tumor, not only for their low incidence among the other tumors found in the review but also because there were no reports in the literature with similar characteristics. However, Warthin stated that these papilliferous cystadenomas with lymphoid stroma represent a grotesque development of the eustachian tube, which had been modified and grown slowly over the years and taken a late cancer trend. In 1944, Martin and Ehrlich¹⁴ reported 22 cases of papillary cystadenoma lymphomatous of the parotid gland and suggested the eponym of *Warthin's tumor* in honor of the first researcher who described it.³

Warthin tumor is the second most common cancer of the parotid glands—the most common is pleomorphic adeno-

ma^{1,5}—and represents ~2 to 15% of all epithelial neoplasms of the parotid, being bilateral in 7 to 10% and multifocal in 2%. Both recurrences as well as malignancies are rare.^{4,9} Warthin tumor can occur unilaterally or bilaterally, metachronously or synchronously. Most salivary gland neoplasms have unilateral presentation alone, and simultaneous and bilateral findings are unusual.¹⁰ There are a few reports of synchronous bilateral tumors in the literature. In a systematic review of Tveterås and Kristensen, only seven synchronous bilateral tumors were identified in the 71 cases reviewed. It is even rarer to find multiple synchronous bilateral Warthin tumors.¹¹

Most tumors occur in men (man-to-woman ratio of 10:1), although recent studies show a fall in this proportion, with a smaller distribution between the sexes.^{8,9} The condition usually occurs between sixth and seventh decades of life and is described predominantly in white subjects, less frequently in Oriental subjects, and rarely in black subjects.⁶

Smoking is an important risk factor for the development of Warthin tumor. Some authors report that the risk is closely related to the amount smoked and that smokers are eight times more likely to develop the tumor than nonsmokers.^{1,4,8} It is believed that this relationship is justified by the retrograde flow of substances in cigarette smoke to the salivary ducts or the excretion by the cigarette of noxious substances in the ducts.¹² The association with cigarettes is independent of sex and age.

Although there are some theories to explain the origin and development of the tumor, there is still controversy in the scientific world. Among the most well-accepted theories, one hypothesis relates that the tumor is an adenoma with concomitant lymphocytic infiltration; another hypothesis refers to the neoplastic proliferation of salivary ductal cells in its course of development near the lymph nodes and peri- and intraparotid, associated with the major salivary glands, especially the parotid, because this is encapsulated later in the submandibular and the sublingual glands.⁷ Some authors suggest that the tumor has a lymphocytic component with an immunologic reaction to the epithelial component, rather than the tumor being completely made up of lymphatic tissue.⁹ There are still countless theories against Warthin tumor being a true neoplasm. Honda et al¹⁶ have shown that the epithelial tumor components are polyclonal cellular populations—which exclude a pattern of malignant growth—and according to the World Health Organization, these lesions should be classified as tumorlike lesions.² Some features of Warthin tumor speak in favor of benignity, such as its slow growth, its well-defined nodule format with regular outlines, the unusual involvement of the facial nerve, and the low rates of malignant progression and recurrence.

The clinical history is usually a patient seeking medical attention for a nodular lesion that is painless or a bit painful, with slow growth, top of the parotid gland, near the angle of the mandible. The patient may also report buzzes and even deafness, although rare.⁵ The average size of the tumor at presentation varies from a few millimeters to centimeters, averaging 2 to 4 cm.^{5,7,9} A sudden increase of the tumor can

indicate secondary infection in the location or the need to add another diagnostic hypothesis.

A detailed clinical history and thorough physical examination can direct the diagnostic hypothesis toward Warthin tumor. Additional tests such as ultrasonography may be useful in elucidating the content of the lesion. Computed tomography and magnetic resonance imaging may be requested in special situations, such as multiple tumors, suspicion of other concomitant neoplasms, and cases of relapse.⁷ Although quite controversial in the scientific world, some studies have shown high sensitivity and specificity of Warthin tumor in fine FNA. Other authors report that the main goal of FNA in parotid nodes is the distinction between a malignant and a benign neoplasm, whereas the definitive diagnosis can only be given with histopathology after tumor excision.^{13,15}

Macroscopically, the tumor is cystic and filled with a brown gelatinous liquid. Cytologic findings of the tumor in FNA are epithelial parenchyma and lymphoid stroma, with amorphous cell groups and a mixture of lymphocytes, epithelial cells, oncocytes, and mast cells.⁷ The parenchymatous tissue is composed of tubules and dilated cystic spaces within the lumen from which thin papillary processes protrude like ribbons.³

The treatment recommended in the literature for Warthin tumor is superficial parotidectomy when the tumor occurs in a superficial lobe—90% of the cases—or total parotidectomy when the tumor is in a deep lobe or for recurrent tumors, with both procedures involving the identification and preservation of the facial nerve.^{1,5,7}

Postsurgical complications are uncommon, with low incidence and morbidity. The most important are facial nerve lesions, Frey syndrome, wound infections, dehiscence, hematomas, and seromas. Some studies report incidence of temporary facial paralysis in 16 to 47% and permanent facial paralysis in 0 to 9% of parotidectomies.⁵

Conclusion

This article reports an extremely rare case of bilateral and synchronous Warthin tumor as well as presents a literary review on the incidence and etiology of this lesion in the population. Recent studies imply that this is not a true neoplasm tumor and therefore can be reclassified as a tumorlike lesion. The standard recommended treatment is

either a superficial or total parotidectomy, depending on the extent and location of the tumor in the gland. We believe that more clinical and histopathologic studies are needed to clarify its synchronous occurrence.

References

- 1 Ascani G, Pieramici T, Rubini C, Messi M, Balercia P. Synchronous bilateral Warthin's tumours of the parotid glands: a case report. *Acta Otorhinolaryngol Ital* 2010;30:310–312
- 2 Naujoks C, Sproll C, Singh DD, et al. Bilateral multifocal Warthin's tumors in upper neck lymph nodes. Report of a case and brief review of the literature. *Head Face Med* 2012;8:11
- 3 Viveros ALM, Sánchez MJF. Tumor de Warthin. *Anales médicos de la Asociación del Hospital ABC* 2001;46(2):88–91
- 4 Alwan MH, Kirkwood S. Periparotid multifocal Warthin's tumour. *ANZ J Surg* 2011;81:183–184
- 5 Chedid HM, et al. Tumor de Warthin da glândula parótida: estudo de 70 casos. *Rev Col Bras Cir* 2011;38(2):090–094
- 6 Pinkston JA, Cole P. Cigarette smoking and Warthin's tumor. *Am J Epidemiol* 1996;144:183–187
- 7 Castro GA, et al. Tumor de Warthin de Glândula Parótida. *Int Arch Otorhinolaryngol* 2004;8(2):3–5
- 8 Lamelas J, Terry JH Jr, Alfonso AE. Warthin's tumor: multicentricity and increasing incidence in women. *Am J Surg* 1987;154:347–351
- 9 Hilton JM, Phillips JS, Hellquist HB, Premachandra DJ. Multifocal multi-site Warthin tumour. *Eur Arch Otorhinolaryngol* 2008;265:1573–1575
- 10 Gnepp DR, Schroeder W, Heffner D. Synchronous tumors arising in a single major salivary gland. *Cancer* 1989;63:1219–1224
- 11 Tveterås K, Kristensen S. Warthin's tumour with bilateral synchronous presentation. Survey of the literature and a new case. *J Laryngol Otol* 1986;100:487–492
- 12 Gallo O, Bocciolini C. Warthin's tumour associated with autoimmune diseases and tobacco use. *Acta Otolaryngol* 1997;117:623–627
- 13 Azua-Romeo J, et al. Synchronous salivary gland tumors with regard to two cases. *Rev Esp Cir Oral y Maxilofac* 2005;27(3):145–149
- 14 Martin H, Ehrlich HE. Papillary cystadenoma lymphomatosum (Warthin's tumor) of the parotid gland. *Surg Gynecol Obstet* 1944;79:611–623
- 15 Brennan PA, Davies B, Poller D, et al. Fine needle aspiration cytology (FNAC) of salivary gland tumours: repeat aspiration provides further information in cases with an unclear initial cytological diagnosis. *Br J Oral Maxillofac Surg* 2010;48:26–29
- 16 Honda K, Kashima K, Daa T, Yokoyama S, Nakayama I. Clonal analysis of the epithelial component of Warthin's tumor. *Hum Pathol* 2000;31:1377–1380