

Imaging Analysis of Onodi Cells on Cone-Beam Computed Tomography

Ibrahim K. Ali¹ Kaustubh Sansare¹ Freny Karjodkar¹ Mohd Saalim¹

¹Department of Oral Medicine and Radiology, Nair Hospital Dental College, Mumbai, India

Address for correspondence Ibrahim K. Ali, MDS, Department of Oral Medicine and Radiology, Nair Hospital Dental College, Mumbai, 400008, India (e-mail: ibrahimali2589@gmail.com).

Int Arch Otorhinolaryngol 2020;24(3):319–322.

Abstract

Introduction Onodi cells are the most posterior ethmoid air cells, and extend superolaterally to the sphenoid sinus. The identification of Onodi cells is essential to because they can have some significant anatomic variations and relationships to vital adjacent structures, like the optic canal, the sphenoid sinus, and the internal carotid artery.

Objective The present study aimed to assess the prevalence of Onodi cells and their position with respect to sphenoid sinus. To the authors' best knowledge, this is the first study that uses cone-beam computed tomography (CBCT) to assess the prevalence and position of Onodi cells.

Methods We collected CBCT scan records from November 1st, 2016, to July 31st, 2017; the patients who fulfilled the eligibility criteria were included in the present study. The CBCT scans were reviewed by two independent observers. The descriptive statistics was performed using the Statistical Package for the Social Sciences (SPSS, SPSS, Inc., Chicago IL, US) software, version 17.0. A cross-tabulation of gender with the presence and position of Onodi cells was evaluated using the Chi-squared (χ^2) test. The inter- and intraobserver agreements were evaluated using Kappa (κ) statistics.

Results Onodi cells were identified in 86 (42.8%) out of 201 patients. A subgroup analysis revealed that Onodi cells were present in 45 (43.3%) female and 41 (42.3%) male patients. The position of the Onodi cells was superior with respect to the sphenoid sinus in 43 (50%) of the patients, superolateral in 36 (41.9%), and lateral to the sphenoid sinus in 7 (8.1%) of the patients.

Conclusion The present study indicated a high prevalence of Onodi cells, with approximately equal distribution among males and females, and mostly superior in position in relation to the sphenoid sinus.

Keywords

- ▶ onodi cell
- ▶ optic neuritis
- ▶ cone-beam computed tomography
- ▶ endonasal transsphenoidal technique

Introduction

Dr. Adolfo Onodi described Onodi cells as the most posterior ethmoid air cells that extend superolaterally to the sphenoid sinus, and are intimately related to the optic nerve. During sinus surgeries, unrecognized Onodi cells can result in serious damage to the optic nerve.^{1,2} Currently, there has been more concern to define these cells and their variations as

they pertain to the endoscopic sinus and endonasal sellar surgery. The identification of Onodi cells is essential because they can have some significant anatomic variations and relationships to vital adjacent structures like the optic canal, the sphenoid sinus and the internal carotid artery. The endonasal transsphenoidal technique is the recent preferred approach for the resection of pituitary adenomas.³ This

received

April 16, 2018

accepted

September 8, 2019

published online

December 13, 2019

DOI <https://doi.org/>

10.1055/s-0039-1698779.

ISSN 1809-9777.

Copyright © 2020 by Thieme Revinter Publicações Ltda, Rio de Janeiro, Brazil

License terms



technique is chosen over the transcranial route due to its less invasive nature. As this procedure is gaining increasing popularity, it is imperative to unambiguously identify the surrounding anatomy to ensure a safe and precise dissection.⁴ During surgery, the identification of Onodi cells is crucial to maximize exposure and reduce the risk of injury to the surrounding structures.⁵ The prevalence of Onodi cells varies with different identification methods.

Driben et al⁶ reported Onodi cell prevalence on cadaveric endoscopic examinations and axial section of computed tomography (CT) examinations that was of 39% and 7% respectively. Weinberger et al⁷ reported 14% and 8% of prevalence on cadaveric endoscopic versus coronal CT examinations respectively. Yeoh and Tan⁸ and Thanaviratananich et al⁹ reported prevalences of 51% and 60% respectively on Asian cadavers by performing endoscopic examinations. These studies reveal that the prevalence by endoscopy is higher than that by radiography.

Arslan et al,¹⁰ Unal et al,¹¹ and Nitinavakarn et al¹² studied two views (axial and coronal) of CT scans and reported prevalences of 12%, 8% and 25% respectively. Bansberg et al¹³ and Batra et al¹⁴ reported a greater prevalence of Onodi cells when they examined three views of the CT in contrast with two views of the CT. Chmielik and Chmielik¹⁵ reported a prevalence of 39.8% of Onodi cells by examining three CT planes. The aforementioned studies reveal that when the scan data are viewed in all three planes, the radiographic prevalence improves. To overcome this low prevalence, the examination of these cells in different sections is recommended.

Cone-beam computed tomography (CBCT) is a recent imaging modality that enables the visualization of Onodi cells in different planes with various advantages over computed tomography (CT). The literature search did not reveal any study investigating the prevalence of Onodi cells using CBCT. To the authors' best knowledge, the present is the first study that uses CBCT to assess the prevalence and position of Onodi cells with respect to the sphenoid sinus.

Materials and Methods

The CBCT scan records from March 2015 to February 2016 were retrieved from the digital imaging and communications

in medicine archive folder of our institution. These scans had been used earlier in a study involving accessory maxillary ostium and Haller cells. The Z statistic was of 1.96 for the 95% confidence interval, 7% minimum allowable risk, power of 80% and the expected prevalence of 0.39 (39%) were taken from this previous study.¹⁵ The minimum sample size calculated was 189; therefore, we decided to include 201 CBCT scans from the archive folder that fulfilled the inclusion criteria.

The CBCT scans were reviewed by two independent observers (radiologists with a minimum of 5 years of experience in interpreting scans). The subjects who had had trauma or had history of surgery in the sinus region, or tumor causing distortion of the anatomy, were excluded from the present study. The CBCT scans were taken using the Kodak CS 9300 3D system (Carestream Health, Inc., Rochester, NY, US) with field of view of 17 × 13.5 cm, Voxel size of 250 × 250 × 250 μm, 10 mA, X-ray pulse time of 30 ms, and 70 kVp. A training session to precisely identify Onodi cells was planned for the observers before the beginning of the study. The CBCT images were evaluated using a three-dimensional imaging communication software (Carestream Health, Inc., Rochester, NY, US) on a workstation with a 19-inch HP Compaq LE1911 LCD monitor (Hewlett-Packard, Palo Alto, CA, US). The scans were independently analyzed by the two observers, who were allowed to use the contrast and zoom tools. A total of 50 scans were reviewed twice at an interval of 15 days by the same observers to calculate intraobserver agreement using Kappa (κ) statistics. The descriptive statistics was performed using the Statistical Package for the Social Sciences (SPSS, SPSS, Inc., Chicago IL, US) software, version 17.0. A cross-tabulation of gender with the presence and position of Onodi cells was evaluated using the Chi-squared (χ^2) test.

Results

The data of the 201 patients was included according to the eligibility criteria. Of these, 104 patients were female and 97 were male. Onodi cells (► Fig. 1) were identified in 86 patients (42.8%). The age ranged from 16 to 85 years (mean: 37 years). The descriptive analysis revealed that Onodi cells were present in 45 (43.3%) females and 41 (42.3%) males. Onodi cells were present superior in position

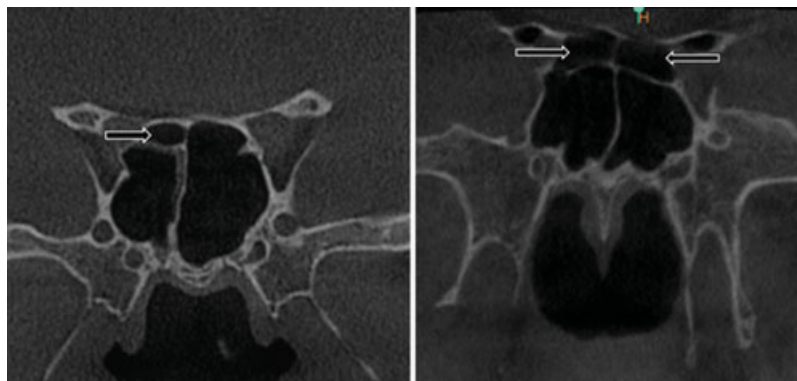


Fig. 1 Cone-beam computed tomography (CBCT) scan in coronal view showing Onodi cells (black arrows).

Table 1 Association of gender and the presence of Onodi cells (Chi-squared test)

Gender	Onodi cells		Total n (%)
	Present n (%)	Absent n (%)	
Male	41 (42.3)	56 (57.7)	97 (100)
Female	45 (43.3)	59 (56.7)	104 (100)
Total	86 (42.8)	115 (57.2)	201 (100)

Note: *p*-value: 0.886.

with respect to the sphenoid sinus in 43 (50%) of the patients, superolateral in 36 (41.9%), and lateral to the sphenoid sinus in 7 (8.1%) of the patients. No significant association was observed on the χ^2 test between gender and presence of Onodi cells (– **Table 1**), or regarding the position of the Onodi cells with respect to the sphenoid sinus (– **Table 2**). The κ score indicated almost perfect interobserver (0.854) and intraobserver (0.921) agreements.

Discussion

As endoscopic skull base and endoscopic transsphenoidal surgeries become common, it is essential to identify the intricate anatomy of the base of the skull. The Onodi cell is the most posterior ethmoid cell that pneumatizes superiorly and laterally to the sphenoid sinus, in close proximity to the optic nerve canal and internal carotid artery. Earlier studies on CT scans reported that the prevalence of Onodi cells ranges from 8% to 24%,^{6,16–19} whereas cadaveric studies showed an increased prevalence range of 42% to 60%.^{7,9,20,21} Shin et al²² analyzed 162 preoperative CT scans and intraoperative endoscopic endonasal results and reported an incidence of Onodi cells on the preoperative CT of 32.7%, and of 33.3% during transsphenoidal surgery, thus demonstrating a good correlation between CT and intraoperative findings. There has been a difference in the prevalence of Onodi cells in cadaveric and radiographic anatomical studies. This dilemma is essential to address, as preoperative planning is key to safe and successful surgical procedures.²³ The present study found a prevalence of 42.8% of Onodi cells, which is higher than the prevalence found in a recently reported study.¹⁵ The high percentage of Onodi cells in the present study may indicate the usefulness of the CBCT scan in the recognition of bony structures, as in paranasal sinus.^{24,25} The present study provides an evidence of the usefulness of the CBCT technique in the detailed imaging of bony structures of the paranasal sinus region at considerably low radiation doses in contrast to the CT. In the present study, we found an almost equal distribution of Onodi cells among male and female patients. This finding was consistent with that of the study by Tomovic et al.²³ In the current study, the superior position of Onodi cells was more prevalent; however, Chmielik and Chmielik¹⁵ reported that the superolateral position was more prevalent in their study. Because of the high prevalence of Onodi cells, it is important to find

Table 2 Association of gender and the position of Onodi cells (Chi-squared test)

Gender	Onodi cells			Total n (%)
	Superolateral n (%)	Superior n (%)	Lateral n (%)	
Male	17 (41.5)	20 (48.8)	4 (9.8)	41 (100)
Female	19 (42.2)	23 (51.1)	3 (6.7)	45 (100)
Total	36 (41.9)	43 (50)	7 (8.1)	86 (100)

Note: *p*-value: 0.870.

out their exact position and their relationship to the optic nerve, the internal carotid artery and the pituitary gland, because the optic nerve often presents with an Onodi cell. When there are large Onodi cells present, this may lead the surgeon to mistake it for the sphenoidal sinus, and this may result in the surgical excavation of the sinus, which may lead to life-threatening complications. The limitations of this observation are the lack of endoscopic examinations of the patients to confirm the presence and position of the Onodi cells. We advise the performance of a study on the prevalence of Onodi cells on CBCT and CT examinations with endoscopic examinations to compare the results of the two modalities in relation to the gold standard that is the endoscopic finding.

Conclusion

The present study suggested a high prevalence of Onodi cells, and the superior position was the most common followed by the superolateral position, with approximately equal prevalence among males and females. It is important to obtain CBCT images and review them in different planes before sinus surgeries to know the exact relation of the Onodi cells with important anatomic structures in order to prevent postoperative surgical complications.

Conflict of Interest

The authors have none to disclose.

References

- Ónodi A. The Optic Nerve and the Accessory Sinuses of the Nose. William Wood; 1910
- Stammlinger HR, Kennedy DW Anatomic Terminology Group. Paranasal sinuses:anatomic terminology and nomenclature. Ann Otol Rhinol Laryngol Suppl 1995;167:7–16
- Schwartz T, Anand V. Endoscopic Pituitary Surgery: Endocrine, Neuro-Ophthalmologic and Surgical Management. Thieme; 2011
- Kim DH, Hong YK, Jeun SS, et al. How to Expose the Entire Sella Floor With Minimal Manipulation During an Endoscopic Endonasal Transsphenoidal Approach. J Craniofac Surg 2017;28(04): 1005–1006
- Liu JK, Christiano LD, Patel SK, Tubbs RS, Eloy JA. Surgical nuances for removal of tuberculum sellae meningiomas with optic canal involvement using the endoscopic endonasal extended transsphenoidal transplanum transtuberulum approach. Neurosurg Focus 2011;30(05):E2

- 6 Driben JS, Bolger WE, Robles HA, Cable B, Zinreich SJ. The reliability of computerized tomographic detection of the Onodi (Sphenoethmoid) cell. *Am J Rhinol* 1998;12(02):105–111
- 7 Weinberger DG, Anand VK, Al-Rawi M, Cheng HI, Messina AV. Surgical anatomy and variations of the Onodi cell. *Am J Rhinol* 1996;10:365–370
- 8 Yeoh KH, Tan KK. The optic nerve in the posterior ethmoid in Asians. *Acta Otolaryngol* 1994;114(03):329–336
- 9 Thanaviratananich S, Chaisiwamongkol K, Kraitrakul S, Tangswad W. The prevalence of an Onodi cell in adult Thai cadavers. *Ear Nose Throat J* 2003;82(03):200–204
- 10 Arslan H, Aydinlioğlu A, Bozkurt M, Egeli E. Anatomic variations of the paranasal sinuses: CT examination for endoscopic sinus surgery. *Auris Nasus Larynx* 1999;26(01):39–48
- 11 Unal B, Bademci G, Bilgili YK, Batay F, Avci E. Risky anatomic variations of sphenoid sinus for surgery. *Surg Radiol Anat* 2006;28(02):195–201
- 12 Nitinavakarn B, Thanaviratananich S, Sangsilp N. Anatomical variations of the lateral nasal wall and paranasal sinuses: A CT study for endoscopic sinus surgery (ESS) in Thai patients. *J Med Assoc Thai* 2005;88(06):763–768
- 13 Bansberg SF, Harner SG, Forbes G. Relationship of the optic nerve to the paranasal sinuses as shown by computed tomography. *Otolaryngol Head Neck Surg* 1987;96(04):331–335
- 14 Batra PS, Citardi MJ, Gallivan RP, Roh HJ, Lanza DC. Software-enabled CT analysis of optic nerve position and paranasal sinus pneumatization patterns. *Otolaryngol Head Neck Surg* 2004;131(06):940–945
- 15 Chmielik LP, Chmielik A. The prevalence of the Onodi cell - Most suitable method of CT evaluation in its detection. *Int J Pediatr Otorhinolaryngol* 2017;97:202–205
- 16 Jones NS, Strobl A, Holland I. A study of the CT findings in 100 patients with rhinosinusitis and 100 controls. *Clin Otolaryngol Allied Sci* 1997;22(01):47–51
- 17 Keast A, Yelavich S, Dawes P, Lyons B. Anatomical variations of the paranasal sinuses in Polynesian and New Zealand European computerized tomography scans. *Otolaryngol Head Neck Surg* 2008;139(02):216–221
- 18 Tan KL, Harvinder S KLT. Prevalence of onodi cells in hospital raja permaisuri bainun, ipoh, malaysia. *Med J Malaysia* 2010;65(02):101–102
- 19 Perez P, Sabate J, Carmona A, Catalina-Herrera CJ, Jimenez-Castellanos J. Anatomical variations in the human paranasal sinus region studied by CT. *J Anat* 2000;197(pt 2):221–227
- 20 Kantarci M, Karasen RM, Alper F, Onbas O, Okur A, Karaman A. Remarkable anatomic variations in paranasal sinus region and their clinical importance. *Eur J Radiol* 2004;50(03):296–302
- 21 Yanagisawa E, Weaver EM, Ashikawa R. The Onodi (sphenoethmoid) cell. *Ear Nose Throat J* 1998;77(08):578–580
- 22 Shin JH, Kim SW, Hong YK, et al. The Onodi cell: an obstacle to sellar lesions with a transsphenoidal approach. *Otolaryngol Head Neck Surg* 2011;145(06):1040–1042
- 23 Tomovic S, Esmaeili A, Chan NJ, et al. High-resolution computed tomography analysis of the prevalence of Onodi cells. *Laryngoscope* 2012;122(07):1470–1473. DOI: 10.1002/lary.23346
- 24 Ali IK, Sansare K, Karjodkar FR, Vanga K, Salve P, Pawar AM. Cone-beam computed tomography analysis of accessory maxillary ostium and Haller cells: Prevalence and clinical significance. *Imaging Sci Dent* 2017;47(01):33–37. DOI: 10.5624/isd.2017.47.1.33
- 25 Ali IK, Sansare K, Karjodkar FR, Salve P. Cone Beam Computed Tomography Assessment of Accessory Infraorbital Foramen and Determination of Infraorbital Foramen Position. *J Craniofac Surg* 2018;29(02):e124–e126. DOI: 10.1097/SCS.0000000000004120