

The Impact of Narrow-band Imaging on the Pre- and Intra- operative Assessments of Neoplastic and Preneoplastic Laryngeal Lesions. A Systematic Review

Carmelo Saraniti¹  Enzo Chianetta¹  Giuseppe Greco¹  Norhafiza Mat Lazim²  Barbara Verro¹ 

¹ Department of Biomedicine, Neurosciences and Advanced Diagnostics, ENT Clinic, Università degli Studi di Palermo, Palermo, Italy

² Department of Otorhinolaryngology-Head and Neck Surgery, School of Medical Sciences, Universiti Sains Malaysia, Kubang Kerian, Kelantan, Malaysia

Address for correspondence Carmelo Saraniti, MD, PhD, Department of Biomedicine, Neurosciences and Advanced Diagnostics, ENT Clinic, Università degli Studi di Palermo, Via del Vespro, 129, Palermo, 90127, Italy (e-mail: carmelo.saraniti@unipa.it).

Int Arch Otorhinolaryngol 2021;25(3):e471–e478.

Abstract

Introduction Narrow-band imaging is an endoscopic diagnostic tool that, focusing on superficial vascular changes, is useful to detect suspicious laryngeal lesions, enabling their complete excision with safe and tailored resection margins.

Objectives To analyze the applications and benefits of narrow-band imaging in detecting premalignant and malignant laryngeal lesions through a comparison with white-light endoscopy.

Data Synthesis A literature search was performed in the PubMed, Scopus and Web of Science databases using strict keywords. Then, two authors independently analyzed the articles, read the titles and abstracts, and read completely only the relevant studies according to certain eligibility criteria. In total, 14 articles have been included in the present review; the sensitivity, specificity, positive and negative predictive values, and accuracy of pre- and/or intraoperative narrow-band imaging were analyzed. The analysis showed that narrow-band imaging is better than white-light endoscopy in terms of sensitivity, specificity, positive and negative predictive values, and accuracy regarding the ability to identify cancer and/or precancerous laryngeal lesions. Moreover, the intraoperative performance of narrow-band imaging resulted more effective than the in-office performance.

Conclusion Narrow-band imaging is an effective diagnostic tool to detect premalignant and malignant laryngeal lesions and to define proper resection margins. Moreover, narrow-band imaging is useful in cases of leukoplakia that may cover a possible malignant lesion and that cannot be easily assessed with white-light endoscopy. Finally, a shared, simple and practical classification of laryngeal lesions, such as that of the European Laryngological Society, is required to identify a shared lesion management strategy.

Keywords

- ▶ narrow-band imaging
- ▶ early diagnosis
- ▶ larynx cancer

received
June 5, 2020
accepted
September 27, 2020
published online
November 30, 2020

DOI <https://doi.org/10.1055/s-0040-1719119>.
ISSN 1809-9777.

© 2020. Fundação Otorrinolaringologia. All rights reserved.
This is an open access article published by Thieme under the terms of the Creative Commons Attribution-NonDerivative-NonCommercial-License, permitting copying and reproduction so long as the original work is given appropriate credit. Contents may not be used for commercial purposes, or adapted, remixed, transformed or built upon. (<https://creativecommons.org/licenses/by-nc-nd/4.0/>)
Thieme Revinter Publicações Ltda., Rua do Matoso 170, Rio de Janeiro, RJ, CEP 20270-135, Brazil

Key Points

Narrow-band imaging is useful in detecting suspicious laryngeal lesions and proper resection margins showing intraepithelial papillary capillary loops (IPCLs) that are considered a main cancer feature.

Narrow-band imaging is used both pre- and intraoperatively, but it provides more precise information if used during surgery.

Compared with white-light endoscopy, narrow-band imaging enables a better assessment of the lesions covered by a thick white plaque (such as in cases of leukoplakia)

The classification of the European Laryngological Society is the simplest and the most practical for the identification of various laryngeal lesions compared with other classifications.

Introduction

Laryngeal squamous cell carcinoma (LSCC) is one of the most frequent head and neck cancers. Early diagnosis and radical excision represent the main goals. Indeed, the challenge for laryngeal cancer is to perform its tailored resection with proper safe margins. Until now, transoral laser microsurgery (TLM) has been the gold standard for the treatment of early glottic cancer, since it enables a tailored and customized resection, ensuring functional preservation as well. Moreover, otolaryngologists can use a quite recent diagnostic tool to achieve this target: narrow-band imaging (NBI), which is an optical technique first used in gastroenterology and then introduced in laryngology in 2004.¹ This endoscopic tool is based on narrow-band optical filters with two ranges of wavelength that are significantly absorbed by hemoglobin. In particular, the first peak wavelength is of 415 nm (range: 400 nm to 430 nm) with blue light that enhances the visualization of capillary vessels on the superficial layer of the mucosa. The second narrow-band light has a peak wavelength of 540 nm (range: 525 nm to 555 nm), and it is a green light that ensures a better visualization of the submucosal vascular pattern. Actually, vascular changes and neoangiogenesis are the main cancer features that can be better detected with NBI endoscopy than with white-light (WL) endoscopy. In particular, according to the current literature, any well-demarcated brownish areas and/or thick dark spots and/or winding and hypertrophic vascular patterns can be considered suspicious NBI lesions.² However, a consensus classification based on intraepithelial papillary capillary loop (IPCL) patterns is required to properly assess these lesions. Therefore, NBI endoscopy represents the so-called “optical biopsy”,¹ because it provides a better distinction between benign and malignant laryngeal lesions, and, therefore, a more appropriate management of the patient, even before the biopsy and histological assessment, which are the gold standard for tumor diagnosis. Thus, NBI is a useful tool not only in the preoperative phase for early diagnosis, but also during surgery, for a proper and effective tumor resection, and during the follow-up for the early detection of a possible recurrence.

Therefore, the aim of the present review is to analyze the applications and advantages of NBI compared with WL endoscopy in cases of malignant laryngeal lesions, focusing

on sensitivity (SE), specificity (SP), positive and negative predictive values (PPVs and NPVs) and accuracy (ACC).

Review of the Literature

Search Methodology

Using the Preferred Reporting Items for Systematic Review and Meta-Analysis (PRISMA) guidelines, two independent authors (CS, BV) analyzed the literature published on the PubMed, Scopus and Web of Science databases (up to March 1st, 2020). The keywords “*narrow-band imaging*” or “*NBI*” and “*larynx cancer*” or “*glottic*” or “*larynx*” were used to detect the relevant articles. The two researchers independently selected articles by reading titles and abstracts; then, the included articles were read entirely. Moreover, some articles were extracted from references mentioned in the previously selected articles.

Eligibility Criteria

The inclusion criteria were original articles describing research that performed NBI in patients with larynx lesions; studies that reported accuracy, sensitivity, specificity, PPVs and NPVs; and studies published in English.

The exclusion criteria were studies that reported lesions involving sites other than larynx; reviews, editorials, commentaries, thesis and conference abstracts; studies that calculated statistical data of WL combined with NBI; studies that included less than 40 lesions.

Statistical Data Analysis

In the case of lack of statistical data in some articles,^{3–7} we have calculated them by using the Prism GraphPad software (GraphPad Software, San Diego, CA, US).

Study Selection and Characteristics

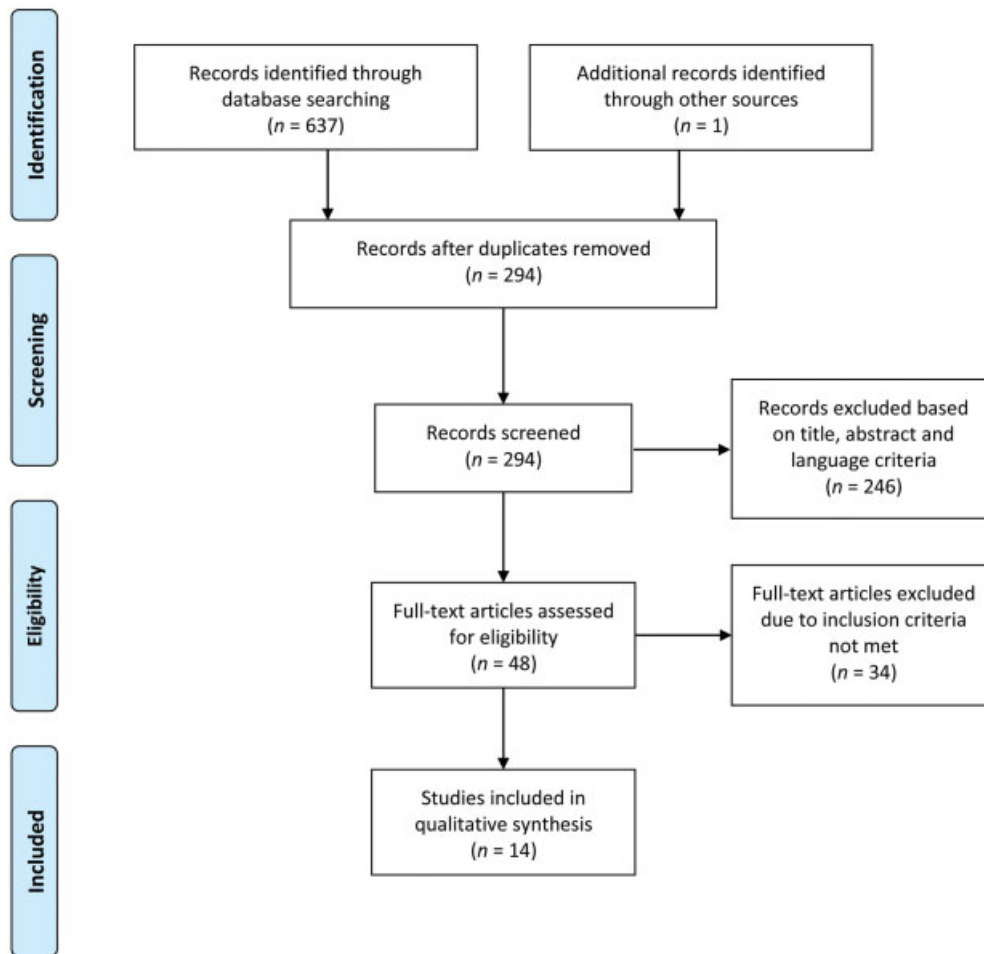
The process of selection of articles is shown in ►**Fig. 1**. In total, 638 articles were identified through the search in the databases and references. After removing the duplicates and reading titles and abstracts, 48 articles were selected. Then, according to eligibility criteria, only 14 of the full-text articles were included in the present review.

Preoperative Performance of NBI

Six of the selected articles reported the preoperative performance of NBI (►**Table 1**). These studies included patients affected by premalignant and malignant laryngeal lesions,



PRISMA 2009 Flow Diagram



From: Moher D, Liberati A, Tetzlaff J, Altman DG, The PRISMA Group (2009). Preferred Reporting Items for Systematic Reviews and Meta-Analyses: The PRISMA Statement. *PLoS Med* 6(7): e1000097. doi:10.1371/journal.pmed1000097

For more information, visit www.prisma-statement.org.

Fig. 1 PRISMA 2009 flow diagram of the selection process of articles from the current literature.

such as papilloma, leukoplakia and SCC, which were treated with TLM.

In these cases, the preoperative performance of NBI has ensured high sensitivity, specificity, accuracy, PPVs and NPVs in the diagnosis of malignancy.

In particular, Rzepakowska et al.⁸ reported 91 cases of vocal cord leukoplakia, and they demonstrated that the preoperative performance of NBI enabled the detection of 75/77 cases of benign lesions and all cases of malignant ones, with a PPV of 87.5% and an NPV of 100%. Moreover, in this study, NBI showed a sensitivity of 100%, a specificity of 97.4%, and an accuracy of 97.8% in predicting malignancy in cases of leukoplakia.

Staníková et al.⁶ included 63 cases of leukoplakia on the vocal cords in their article. Comparing the preoperative NBI assessments with the histological results, they achieved rates of SE, SP, ACC, PPVs and NPVs of NBI of 88%, 89.5%, 88.9%, 85% and 92% respectively.

Furthermore, other authors^{3,9-11} studied the preoperative performance of NBI in all laryngeal lesions, including benign ones. In particular, Šifrer et al.⁹ performed NBI endoscopy on 49 laryngeal lesions, 26 of which were benign, and 23 of which were malignant after the histological evaluation. In this study, the NBI showed an SE of 100%, an SP of 95%, a PPV of 88%, an NPV of 88% and an ACC of 96%. In

Table 1 Characteristics of the studies that analyzed the preoperative performance of NBI

Authors	Rzepakowska et al. ⁸	Rzepakowska et al. ¹⁰	Šifrer et al. ⁹	Volgger et al. ³	Staníková et al. ⁶	Hosono et al. ¹¹
Number of assessed lesions	91	105	49	41	63	166
Type of lesion	Leukoplakia	Laryngeal lesions	Laryngeal lesions	Laryngeal lesions	Leukoplakia	Laryngeal lesions
IPCL classification	Ni et al. ¹⁵	Ni et al. ¹⁵	ELS	Ni et al. ¹⁵	Ni et al. ¹⁵	None
SE of NBI (%)	100%	98.8%	100%	100%	88%	84.4%
SP of NBI (%)	97.4%	73.9%	95%	79.4%	89.5%	88.6%
PPV of NBI (%)	87.5%	93.1%	88%	50%	85%	91%
NPV of NBI (%)	100%	94.4%	100%	100%	92%	80.5%
ACC of NBI (%)	97.8%	93.3%	96%	82.9%	88.9%	86.1%

Abbreviations: ACC, accuracy; ELS, European Laryngological Society; IPCL, intraepithelial papillary capillary loop; NBI, narrow-band imaging; NPV, negative predictive value; PPV, positive predictive value; SE, sensitivity; SP, specificity.

Note: the number and type of assessed lesions were classified according to the IPCLs, the SE, the SP, the PPV, the NPV, and the ACC of NBI (the data calculated by the reviewers are reported in italics).

Table 2 Characteristics of the studies that analyzed the intraoperative performance of NBI

Authors	Šifrer et al. ¹²	Lukes et al. ⁷	Klimza et al. ⁵
Number of assessed lesions	191	78	90
Type of lesion	Laryngeal lesions	Laryngeal lesions	T1-T2 glottic cancer
IPCL classification	ELS	None	None
SE of NBI (%)	98%	100%	100%
SP of NBI (%)	95%	82%	0%
PPV of NBI (%)	88%	85%	85.7%
NPV of NBI (%)	99%	100%	<i>Not able to evaluate</i>
ACC of NBI (%)	95%	91%	85.7%

Abbreviations: ACC, accuracy; ELS, European Laryngological Society; IPCL, intraepithelial papillary capillary loop; NBI, narrow-band imaging; NPV, negative predictive value; PPV, positive predictive value; SE, sensitivity; SP, specificity.

Note: the number and type of assessed lesions were classified according to the IPCLs, the SE, the SP, the PPV, the NPV, and the ACC of NBI (the data calculated by the reviewers are reported in italics).

another article, Rzepakowska et al.¹⁰ analyzed 105 suspected laryngeal lesions with NBI to detect malignancy, and they found a high ability of the NBI to identify malignant lesions, with an SE of 98.8%, an SP of 73.9%, a PPV of 93.1%, an NPV of 94.4%, and an ACC of 93.3%.

Intraoperative Performance of NBI

Only a few authors^{5,7,12} analyzed the results of the performance of NBI during direct laryngoscopies (► **Table 2**).

In particular, Lukes et al.⁷ studied 78 laryngeal lesions, clearly excluding the benign ones. The intraoperative performance of NBI enabled the identification of 39 LSCCs and 32 papillomas which were then confirmed by the histological assessment. Thus, they found an SE of 100%, an SP of 82%, a

PPV of 85%, an NPV of 100%, and an ACC of 91%. Only seven lesions were found to be false positive.

Šifrer et al.¹² performed rigid NBI during direct laryngoscopy in 191 laryngeal lesions and achieved statistical values similar to those of Lukes et al.:⁷ SE of 98%, SP of 95%, PPV of 88%, NPV of 99%, and ACC of 95%. Actually, performing NBI during surgery, they detected 78 malignant lesions, 100 benign lesions, and 13 discrepancies between the NBI and the histology.

Preoperative NBI versus Intraoperative NBI

Two of the selected articles^{13,14} compared the results of in-office and intraoperative NBI in the evaluation of laryngeal lesions (► **Table 3**). De Vito et al.¹³ performed a prospective study on 73 vocal-cord lesions. Regarding the detection of premalignant and malignant lesions, the preoperative performance of NBI showed an SE of 97%, an SP of 92.5%, a PPV of 91.4%, an NPV of 97.4%, and an ACC of 94.5%. Meanwhile, the intraoperative NBI evaluation enabled the authors to achieve higher specificity (95%), PPV (94.1%) and accuracy (95.9%) compared with in-office NBI. On the other hand, the SE and NPV were similar for the pre- and intraoperative NBI.

Piazza et al.¹⁴ performed a similar study protocol on 279 lesions highly suspicious for carcinoma. Therefore, they performed NBI endoscopy before and during surgery, getting better statistical results in the latter case.

NBI versus WL

Five of the included studies^{4,5,14-16} compared the statistical results of WL and NBI (► **Table 4**). Klimza et al.⁵ analyzed 90 T1-T2 glottic cancers performing intraoperative WL and NBI. They found that NBI proved to have higher SE (100% versus 79.5%), PPV (85.7% versus 83.3%) and ACC (85.7% versus 71.1%) than WL regarding the endoscopic role to detect proper resection margins during TLM. The same trend of statistical results was observed in the article by Piazza et al.,¹⁴ in which they also made a comparison between intraoperative WL and NBI.

Table 3 Characteristics of the studies that compared the pre- and intraoperative performances of NBI

Authors	De Vito et al. ¹³	Piazza et al. ¹⁴
Number of assessed lesions	73	279
Type of lesion	Laryngeal lesions	Laryngeal lesions
IPCL classification	Ni et al. ¹⁵	None
SE of preoperative NBI (%)	97%	61%
SE of intraoperative NBI (%)	97%	98%
SE of WL (%)	–	33% (intraoperative)
SP of preoperative NBI (%)	92.5%	87%
SP of intraoperative NBI (%)	95%	90%
SP of WL (%)	–	95% (intraoperative)
PPV of preoperative NBI (%)	91.4%	83%
PPV of intraoperative NBI (%)	94.1%	86%
PPV of WL (%)	–	85% (intraoperative)
NPV of preoperative NBI (%)	97.4%	88%
NPV of intraoperative NBI (%)	97.4%	88%
NPV of WL (%)	–	100% (intraoperative)
ACC of preoperative NBI (%)	94.5%	76%
ACC of intraoperative NBI (%)	95.9%	92%
ACC of WL (%)	–	64% (intraoperative)

Abbreviations: ACC, accuracy; ELS, European Laryngological Society; IPCL, intraepithelial papillary capillary loop; NBI, narrow-band imaging; NPV, negative predictive value; PPV, positive predictive value; SE, sensitivity; SP, specificity; WL, white-light endoscopy.

Note: the number and type of assessed lesions were classified according to the IPCLs, the SE, the SP, the PPV, the NPV, and the ACC of NBI performed pre-operatively and intra-operatively.

Ni et al.^{15,16} performed two studies in which they compared the two endoscopic tools in the preoperative phase. In 2011, they studied premalignant and malignant laryngeal lesions,¹⁵ and, in 2018, they focused just on vocal-cord leukoplakia.¹⁶ In both studies, the authors reported better results of NBI with regards to SE, SP, PPV, NPV and ACC.

In the article written by Popek et al.,⁴ 333 laryngeal lesions, including benign ones, were analyzed in-office with both WL and NBI. They achieved higher values of SE (98.5% versus 95.4%), SP (98.5% versus 84.2%), PPV (97.7% versus 79.6%), NPV (99% versus 96.6%) and ACC (98.5% versus 88.3%) for the NBI in comparison with WL.

Discussion

Summary of the Main Results

Narrow-band imaging is a recent endoscopic tool used in laryngeal oncology to detect any suspicious lesion and to provide a customized tumor resection, focusing on superfi-

cial vascular changes (IPCLs). It is often described as “optical biopsy”,¹ since it is useful to differentiate various laryngeal lesions and to provide a very reliable diagnosis – almost like the histological assessment –, which enables a proper management of the lesion. Analyzing all the literature since its first use, dwelling on statistical results, we found the usefulness and benefits of NBI in the detection of precancerous and cancerous lesions, as well as in identifying the proper resection margins during surgery,^{13,14} as proven by its high SE, SP and ACC rates. In fact, due to its ability to highlight alterations in the mucosal vascularization, it enables physicians to define more precisely the limit between healthy and pathological tissue and perform a complete and tailored resection, which is more difficult to obtain with WL.³ In addition, based on this analysis, the intraoperative NBI results were better than the preoperative ones. Furthermore, some studies^{4,5,14–16} stressed not only the overall benefits of NBI, but also its remarkable advantages compared with WL.

Preoperative NBI versus Intraoperative NBI

As stated before, NBI is used not only in-office but also during surgery. In particular, the performance of preoperative NBI is useful in the screening and follow-up of suspicious laryngeal lesions, to reduce the number of patients who undergo surgery. In contrast, the intraoperative NBI results were useful especially in the detection of proper resection margins.^{5,14} Indeed, complete tumor excision in TLM represents one of the main issues that may impair the local control of the disease. Thus, intraoperative NBI could be useful because it enables the detection of the superficial spread of the cancer, as well as the performance of a proper and customized tumor resection.¹⁷ Thereby, as reported also by Klimza et al.,⁵ the need for a second-look procedure may be reduced by the systematic performance of intraoperative NBI.

Concerning this, referring to the selected articles, De Vito et al.¹³ reported a slightly better efficiency of intraoperative NBI compared with in-office NBI, although the results were not statistically significant. It is possible to interpret the result obtained by De Vito et al.¹³ by analyzing the differences between the pre- and intraoperative performance of NBI. In fact, in the first case, it is an in-office procedure that is repeatable, with minimal execution time and costs, but burdened by the persistence of oropharyngeal reflexes that can reduce the quality of the images. In contrast, intraoperative NBI has higher costs and execution time, but, at the same time, it enables a closer and magnified observation of the superficial spread thanks to general anesthesia and to the use of rigid telescopes with different angles of visualization. Furthermore, it is necessary to underline that all authors of the studies included in the review used a rigid endoscope in the intraoperative phase,^{5,7,12–14} while almost all of them used a flexible endoscope in the preoperative phase.^{3–6,8,10,13–16} However, in none of the included studies, the effectiveness of NBI in terms of SE, SP, PPV, NPV and ACC is analyzed according to the type of endoscope used (rigid or flexible).

Table 4 Characteristics of the studies that compared NBI and WL

Authors	Klimza et al. ⁵	Piazza et al. ¹⁴	Ni et al. ¹⁶	Ni et al. ¹⁵	Popek et al. ⁴
Number of assessed lesions	90	279	120	104	333
Type of lesion	T1-T2 glottic cancer	Laryngeal lesions	Leukoplakia	Laryngeal lesions	Laryngeal lesions
Pre- or intraoperative NBI	Preoperative	Intraoperative	Preoperative	Preoperative	Preoperative
IPCL classification	None	None	Ni et al. ¹⁵	Ni et al. ¹⁵	Ni et al. ¹⁵
SE of NBI (%)	100%	98%	82.6%	88.9%	98.5%
SE of WL (%)	79.5%	33%	60.8%	68.9%	95.4%
SP of NBI (%)	0%	90%	92.8%	93.2%	98.5%
SP of WL (%)	20%	95%	72.2%	89.8%	84.2%
PPV of NBI (%)	85.7%	86%	73.1%	90.9%	97.7%
PPV of WL (%)	83.3%	85%	34.1%	83.8%	79.6%
NPV of NBI (%)	<i>Not able to evaluate</i>	88%	95.7%	91.7%	99%
NPV of WL (%)	16.7%	100%	88.6%	79.1%	96.6%
ACC of NBI (%)	85.7%	92%	90.8%	90.4%	98.5%
ACC of WL (%)	71.1%	64%	70%	76.9%	88.3%

Abbreviations: ACC, accuracy; ELS, European Laryngological Society; IPCL, intraepithelial papillary capillary loop; NBI, narrow-band imaging; NPV, negative predictive value; PPV, positive predictive value; SE, sensitivity; SP, specificity; WL, white-light endoscopy.
 Note: the number and type of assessed lesions were classified according to the IPCLs, the SE, the SP, the PPV, the NPV, and the ACC of NBI and WL, by specifying if they were performed preoperatively and intraoperatively [the data calculated by the reviewers are reported in italics].

NBI versus WL

To date, WL endoscopy is the most widely used diagnostic tool in the assessment of premalignant lesions or cancer of the larynx. However, WL sometimes fails in identifying leukoplakia or early and slight mucosal changes in the vocal cords. Indeed, a thick white patch may cover an underlying malignant lesion and impair the diagnosis, leading to a false negative result.^{13,15} Moreover, neoangiogenesis and vascular changes represent one of the first alterations in carcinogenesis that WL laryngoscopy cannot identify.¹⁸ Thereby, in this scenario, NBI makes the difference in better identifying benign and malignant lesions. Actually, NBI enables the study of mucosal and submucosal vascular patterns and the classification of any changes in the IPCLs.^{10,16} Thus, regarding the issue of white mucosal thickening, the surrounding mucosa should be analyzed for any vascular abnormalities with NBI.^{5,15,19} Indeed, in the included studies^{4,5,14-16} reported that the SE and NPV of NBI were significantly greater than those of WL. In another study, Ni et al.¹⁶ reported that NBI was better than WL, especially concerning SP and PPV. These results are probably due to the fact that, in the latter study, the authors analyzed only one type of lesion, which is leukoplakia, proving mainly the ability of NBI to detect any malignant lesion covered by a white patch. On the contrary, the other studies examined various laryngeal lesions, and the authors demonstrated the usefulness of NBI in distinguishing benign and malignant lesions.

Therefore, NBI is a more effective diagnostic tool than WL, mainly in cases of detection of early cancer or leukoplakia.

NBI Classification of Laryngeal Lesions

As aforementioned, the efficiency of NBI is related to its ability to reveal IPCL changes on the mucosa and submuco-

sa. However, to provide a consensus assessment of various vascular patterns, a shared classification is required. Until now, the classification of the morphologic endoscopic characteristics of IPCLs developed by Ni et al.¹⁵ is the most widely used. This classification identifies five different types of IPCL changes. Thus, type I is characterized by thin, oblique and arborescent vessels without IPCLs. In type II, the IPCLs are not visible and, the oblique and arborescent vessels have larger diameters. Type III consists of white mucosa that covers the IPCLs preventing their visualization. In type IV, the IPCLs are visible as dark brown spots. Type V, in turn, is divided into three subtypes. In type Va, the IPCLs appear significantly enlarged, with brownish speckles and various shapes. In type Vb, the IPCLs have irregular and snake-like shapes. Type Vc is characterized by necrotic tissue on the surface of the lesion and by tortuous, irregular and line-like or brownish speckled IPCLs. According to this classification, type V corresponds to high-grade dysplasia and cancer, type IV suggests a suspicious lesion, whereas types I, II and III are related to benign lesions.

However, in 2015, the European Laryngological Society (ELS) proposed a new classification.²⁰ The main objective of the ELS was to provide a simpler and practical strategy. This new classification consists of only two vascular patterns: the longitudinal and perpendicular patterns. The former is characterized by vascular changes that remain in two dimensions (length and width) of the vocal folds, such as ectasia, increased vessel density or increased vessel branches, and it is related to benign lesions. Meanwhile, in the perpendicular pattern, the vessels grow in the third dimension, and represent the IPCLs. This pattern could correspond to recurrent respiratory papillomatosis (RRP) or premalignant or malignant lesions. Therefore, to

distinguish these lesions, the angle of the turning point of the IPCL should be evaluated. Indeed, turning points with wide angles are suggestive of RRP, whereas narrow angles are indicators of cancer.

Analyzing the included articles, only two of them^{9,12} evaluated vascular changes according to the ELS classification, and the other eight used the classification made by Ni et al.¹⁵ The remaining studies did not specify the classification used. Due to this gap in the number of articles which used one classification rather than the other one, we cannot include this topic as an evaluation criterion in the present review.

Study Limitations

The present review found some limitations in the analysis of the current literature. Even though we used narrow inclusion criteria, some selected studies showed heterogeneity regarding the number of enrolled patients, types of lesion assessed, study design, and number and level of experience of the endoscopists who performed NBI. At the beginning of the learning curve for NBI, the cases of positive lesions may be overestimated with a consequent increase in the number of false positives. This is mostly observed in the first six months of use.^{14,21} Indeed, regarding this issue, Zurek et al.²² showed that after 65 to 70 NBI examinations, the plateau of the learning process is reached. However, the included studies reported the ability of NBI to detect premalignant and malignant lesions as far as SE, SP, PPV, NPV, and ACC. Moreover, the SP of NBI is based only on outpatient evaluation, without a histological confirmation, since it is unfeasible and unethical to perform either random or systematic biopsies in “non-suspicious” NBI lesions.

Another limitation of the present review refers to the ACC of NBI and WL. Narrow-band imaging is usually performed after WL endoscopy; therefore, the former necessarily shows a higher ACC than the latter in detecting precancerous and cancerous lesions.

Furthermore, NBI is also used and recommended in the follow-up of patients after surgery or radiotherapy, as it enables an earlier detection of relapse than the evaluation with WL.^{14,23} Unfortunately, due to the limited bibliography on the efficacy of NBI in the follow-up, it has not been possible to study in details its benefits and advantages compared with WL.

Final Comments

The objective of the present review was to assess the applications and benefits of NBI by comparing them to those of WL. Therefore, based on the analysis of the current literature, the present study confirms that NBI is an effective diagnostic tool in detecting precancerous and cancerous lesions and in identifying proper surgical margins. Moreover, NBI is useful when laryngeal lesions cannot be easily assessed with WL, such as in the presence of a thick white patch. Therefore, it's important to develop a deep experience in the performance of NBI to interpret correctly and accurately laryngeal lesions, thus significantly reducing diagnos-

tic error. Finally, we would like to emphasize the need to use a shared, simple and practical classification for laryngeal lesions, such as the ELS classification, to identify a consensus lesion management strategy.

Further studies could investigate and evaluate the effectiveness of NBI in another important aspect of laryngeal cancer, namely during the follow-up care, for the early detection of potential recurrences.

References

- Piazza C, Del Bon F, Peretti G, Nicolai P. Narrow band imaging in endoscopic evaluation of the larynx. *Curr Opin Otolaryngol Head Neck Surg* 2012;20(06):472–476
- Lin YC, Watanabe A, Chen WC, Lee KF, Lee IL, Wang WH. Narrow-band imaging for early detection of malignant tumors and radiation effect after treatment of head and neck cancer. *Arch Otolaryngol Head Neck Surg* 2010;136(03):234–239
- Volgger V, Felicio A, Lohscheller J, et al. Evaluation of the combined use of narrow band imaging and high-speed imaging to discriminate laryngeal lesions. *Lasers Surg Med* 2017;49(06):609–618
- Popek B, Bojanowska-Poźniak K, Tomasik B, Fendler W, Jeruzal-Świątecka J, Pietruszewska W. Clinical experience of narrow band imaging (NBI) usage in diagnosis of laryngeal lesions. *Otolaryngol Pol* 2019;73(06):18–23
- Klimza H, Jackowska J, Piazza C, Banaszewski J, Wierzbička M. The role of intraoperative narrow-band imaging in transoral laser microsurgery for early and moderately advanced glottic cancer. *Rev Bras Otorrinolaringol (Engl Ed)* 2019;85(02):228–236
- Staničková L, Šatanková J, Kučová H, Walderová R, Zeleník K, Komínek P. The role of narrow-band imaging (NBI) endoscopy in optical biopsy of vocal cord leukoplakia. *Eur Arch Otorhinolaryngol* 2017;274(01):355–359
- Lukes P, Zabrodsky M, Lukesova E, et al. The role of NBI HDTV magnifying endoscopy in the prehistologic diagnosis of laryngeal papillomatosis and spinocellular cancer. *BioMed Res Int* 2014;2014:285486
- Rzepakowska A, Sielska-Badurek E, Żurek M, Osuch-Wójcikiewicz E, Niemczyk K. Narrow band imaging for risk stratification of glottic cancer within leukoplakia. *Head Neck* 2018;40(10):2149–2154
- Šifrer R, Rijken JA, Leemans CR, et al. Evaluation of vascular features of vocal cords proposed by the European Laryngological Society. *Eur Arch Otorhinolaryngol* 2018;275(01):147–151
- Rzepakowska A, Sielska-Badurek E, Cruz R, Sobol M, Osuch-Wójcikiewicz E, Niemczyk K. Narrow band imaging versus laryngovideostroboscopy in precancerous and malignant vocal fold lesions. *Head Neck* 2018;40(05):927–936
- Hosono H, Katada C, Okamoto T, et al. Usefulness of narrow band imaging with magnifying endoscopy for the differential diagnosis of cancerous and noncancerous laryngeal lesions. *Head Neck* 2019;41(08):2555–2560
- Šifrer R, Šereg-Bahar M, Gale N, Hočvar-Boltežar I. The diagnostic value of perpendicular vascular patterns of vocal cords defined by narrow-band imaging. *Eur Arch Otorhinolaryngol* 2020;277(06):1715–1723
- De Vito A, Meccariello G, Vicini C. Narrow band imaging as screening test for early detection of laryngeal cancer: a prospective study. *Clin Otolaryngol* 2017;42(02):347–353
- Piazza C, Cocco D, De Benedetto L, Del Bon F, Nicolai P, Peretti G. Narrow band imaging and high definition television in the assessment of laryngeal cancer: a prospective study on 279 patients. *Eur Arch Otorhinolaryngol* 2010;267(03):409–414
- Ni XG, He S, Xu ZG, et al. Endoscopic diagnosis of laryngeal cancer and precancerous lesions by narrow band imaging. *J Laryngol Otol* 2011;125(03):288–296

- 16 Ni XG, Zhu JQ, Zhang QQ, Zhang BG, Wang GQ. Diagnosis of vocal cord leukoplakia: The role of a novel narrow band imaging endoscopic classification. *Laryngoscope* 2019;129(02):429–434
- 17 Campo F, D'Aguanno V, Greco A, Ralli M, de Vincentiis M. The prognostic value of adding Narrow-Band Imaging in transoral laser microsurgery for early glottic cancer: a review. *Lasers Surg Med* 2019;52(04):301–306
- 18 Yang Y, Fang J, Zhong Q, et al. The value of narrow band imaging combined with stroboscopy for the detection of applanate indiscernible early-stage vocal cord cancer. *Acta Otolaryngol* 2018;138(04):400–406
- 19 Kraft M, Fostiropoulos K, Gürtler N, Arnoux A, Davaris N, Arens C. Value of narrow band imaging in the early diagnosis of laryngeal cancer. *Head Neck* 2016;38(01):15–20
- 20 Arens C, Piazza C, Andrea M, et al. Proposal for a descriptive guideline of vascular changes in lesions of the vocal folds by the committee on endoscopic laryngeal imaging of the European Laryngological Society. *Eur Arch Otorhinolaryngol* 2016;273(05):1207–1214
- 21 Piazza C, Cocco D, Del Bon F, Mangili S, Nicolai P, Peretti G. Narrow band imaging and high definition television in the endoscopic evaluation of upper aero-digestive tract cancer. *Acta Otorhinolaryngol Ital* 2011;31(02):70–75
- 22 Żurek M, Rzepakowska A, Osuch-Wójcikiewicz E, Niemczyk K. Learning curve for endoscopic evaluation of vocal folds lesions with narrow band imaging. *Rev Bras Otorrinolaringol (Engl Ed)* 2019;85(06):753–759
- 23 Lukes P, Zabrodsky M, Syba J, Lukesova E, Votava M, Plzak J. Efficacy of transnasal flexible videoendoscopy with narrow band imaging for follow-up of patients after transoral laser cordectomy. *Lasers Surg Med* 2020;52(04):333–340