






Mongolian Gerbils as a Model for the Study of Cholesteatoma: Otoendoscopic as a Diagnostic Tool

Jefferson André Bauer^{1,2}  Felipe da Costa Huve^{1,2}  Francine Hehn de Oliveira^{2,3} 
Maurício Noschang Lopes da Silva^{1,2}  Neil Sperling⁴  Sady Selaimen da Costa^{1,2} 

¹ Department of Otorhinolaryngology, Head and Neck Surgery, Hospital de Clínicas de Porto Alegre, Porto Alegre, RS, Brazil

² Postgraduate Department, Universidade Federal do Rio Grande do Sul, Porto Alegre, RS, Brazil

³ Department of Patology, Hospital de Clínicas de Porto Alegre, Porto Alegre, RS, Brazil

⁴ Department of Otolaryngology, Weill Cornell Medical College, New York, NY, United States

Address for correspondence Jefferson André Bauer, MD, Departamento de Otorrinolaringologia e Cirurgia de Cabeça e Pescoço (Zona 19), Hospital de Clínicas de Porto Alegre, Av. Ramiro Barcelos 2350, Porto Alegre, Rio Grande do Sul, Brasil, Zipcode 90035-903 (e-mail: jeffersonbauer86@gmail.com).

Int Arch Otorhinolaryngol 2022;26(4):e643–e648.

Abstract

Introduction Cholesteatoma is a disease with significant clinical impact but is incompletely understood. The challenge of performing studies with long-term follow-up in humans is a factor that has restricted the advance of knowledge in this field. Thus, the use of animal models is highly pertinent, and the Mongolian gerbil model has emerged as one of the most useful.

Objective The present study aims to evaluate, through serial otoendoscopies, the development and characteristics of pars flaccida retraction pocket and cholesteatoma in Mongolian gerbils after obliteration of the eustachian tube and compare it with the control group.

Methods Forty Mongolian gerbils were divided into two groups of 20 animals each. In the intervention group, the animals were followed with serial otoendoscopies after eustachian tube obliteration. In the control group, the animals were only followed through serial otoendoscopies.

Results At the end of the 16-week follow-up, cholesteatoma was present in 13 of 38 (34.2%) ears in the intervention group, and in 7 of 34 (20.6%) in the control group ($p = 0.197$). When we considered cholesteatoma and its potential precursor, pars flaccida retraction pocket, in a combined way, we verified it in 23 of 38 (60.8%) in the intervention group and in 11 of 34 (32.3%) in the control group ($p = 0.016$).

Conclusions Over the 16 weeks of follow-up, serial otoendoscopies enabled us to evaluate the formation and development of pars flaccida retraction pockets and cholesteatomas in Mongolian gerbils and proved to be an excellent diagnostic tool.

Keywords

- ▶ cholesteatoma
- ▶ chronic otitis media
- ▶ mongolian gerbils
- ▶ experimental models
- ▶ otoendoscopy

received
November 13, 2020
accepted after revision
July 20, 2021
published online
February 22, 2022

DOI <https://doi.org/10.1055/s-0041-1740159>.
ISSN 1809-9777.

© 2022. Fundação Otorrinolaringologia. All rights reserved.
This is an open access article published by Thieme under the terms of the Creative Commons Attribution-NonDerivative-NonCommercial-License, permitting copying and reproduction so long as the original work is given appropriate credit. Contents may not be used for commercial purposes, or adapted, remixed, transformed or built upon. (<https://creativecommons.org/licenses/by-nc-nd/4.0/>)
Thieme Revinter Publicações Ltda., Rua do Matoso 170, Rio de Janeiro, RJ, CEP 20270-135, Brazil

Introduction

Cholesteatoma is a pathology with high morbidity and high costs to the health system, with significant risk for complications, both intratemporal and extratemporal.¹ Over the past decades, our understanding of the disease has evolved, especially in clinical and pathophysiological aspects. Many gaps persist in our understanding of its pathogenesis; however, several theories have been proposed. Clinical and experimental evidence^{2–6} has demonstrated that the development of this pathology may follow a sequence of progressive tympanic retraction, pocket formation, loss of self-cleaning properties, keratin accumulation, and cholesteatoma formation. Nevertheless, some previous studies have failed to clearly demonstrate this evolution.^{7,8}

In the effort to provide adequate answers to lingering knowledge gaps, and considering the difficulty in performing histological and long-term follow-up studies of this disease in humans, the use of animal models for this purpose is highly valuable. Among these, Mongolian gerbils have emerged as one of the most operational species to meet this need, because together with humans, they are the only species to develop cholesteatomas spontaneously. According to Chole et al.,⁹ cholesteatomas in Mongolian gerbils exhibit several characteristics similar to those of humans, both macroscopically and microscopically. It has previously been demonstrated that, with experimental obliteration of the external auditory canal or eustachian tube (ET), cholesteatoma can be induced in these animals, with characteristics very similar to those that occur spontaneously.^{10–14} The obliteration of the external auditory canal has been used more frequently in prior studies, since this technique allows the development of cholesteatoma in almost all the animals that undergo the procedure.^{10,15} Although this model has provided us added knowledge of cholesteatoma in general, the pathogenesis involved in the formation of cholesteatoma

when this technique is used appears to differ from that observed in humans.

The present study aims to evaluate, through serial otoscopies, the development and characteristics of pars flaccida retraction pocket and cholesteatoma in Mongolian gerbils after obliteration of the ET and compare it with the control group.

Materials and Methods

The present research was performed at the Animal Experimentation Unit (AEU) of the Hospital de Clínicas de Porto Alegre, between March 2016 and November 2017. All procedures were performed according to the regulations of the Committee on Animal Ethics (CEUA, in the Portuguese acronym) of this institution (16–0010).

Obliteration of the ET in Mongolian gerbils was performed by cauterization of the tubal ostium bilaterally. The animals underwent the procedure while under general anesthesia using inhaled isoflurane, intraperitoneal tramadol (30 mg/kg), and bupivacaine (0.5%, 4 mg/kg). Cauterization was performed using monopolar cautery with a needle tip inserted in a transpalatal approach, without direct visualization of the tubal ostia. Based on an anatomical study by Wolfman et al,¹⁶ the needle was introduced ~ 5 mm posterior to the transition between the hard palate and soft palate of the animal, maintained for 3 seconds, and angled ~ 30° to the right initially and, afterwards, using the same angulation, to the left (→Fig. 1). In the immediate postoperative period, analgesia included intramuscular dipyron (500 mg/kg) in animals that underwent the intervention. Maintenance of analgesia was performed using tramadol hydrochloride (10 mg/kg) every 12 hours intraperitoneally in animals exhibiting clinical signs of pain.

Sixteen weeks was used as a follow-up time (→Fig. 2), established by Wolfmann et al.,¹⁶ who reported that 75% of

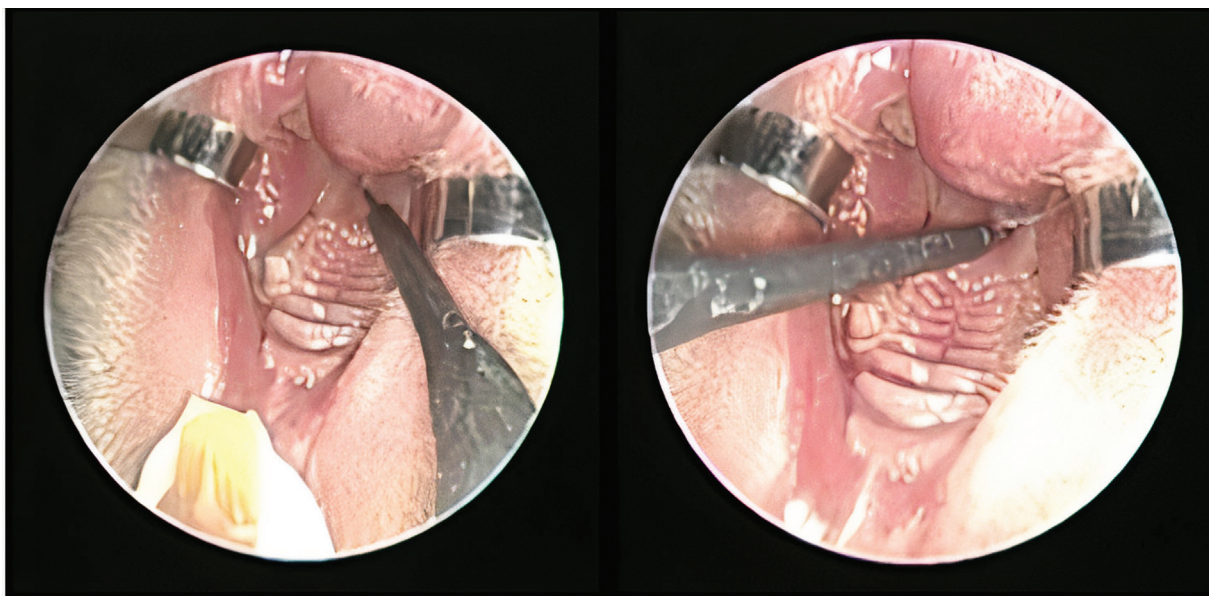


Fig. 1 Eustachian tube obliteration.

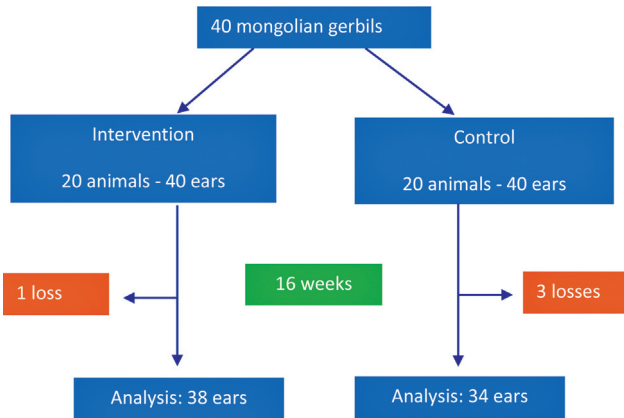


Fig. 2 Study flow chart.

the animals developed cholesteatoma by histology after ET obstruction during this follow-up period. To evaluate the natural history of potential pathology, all Mongolian gerbils sequentially underwent bilateral otoendoscopy (Karl-Storz optical fiber, 0°, 2.8mm, and 18cm; Karl Storz SE & Co. KG, Tuttlingen, Germany) under general anesthesia at zero (to exclude previous cholesteatoma), 1, 4, 8, 12, and 16 weeks (►Fig. 3). Otoendoscopies were evaluated for the presence of normal tympanic membrane (►Fig. 4a), pars flaccida retraction pocket (►Fig. 4b) or cholesteatoma (►Fig. 4c).

We considered cholesteatoma through otoendoscopy in two possibilities: presence of a plug of keratin filling a pars flaccida retraction pocket; and keratin accumulation adjacent to the tympanic membrane and partially or totally obliterating the external auditory canal.

The sample calculation was performed using an estimated incidence of developing cholesteatoma of ~ 45% in the control group and of 85% in the intervention group, as reported in the literature.^{9,11,16} The incidence of cholesteatoma formation in each group was reported as *n* (%). Differences in the incidences between the groups were assessed using the chi-squared test.

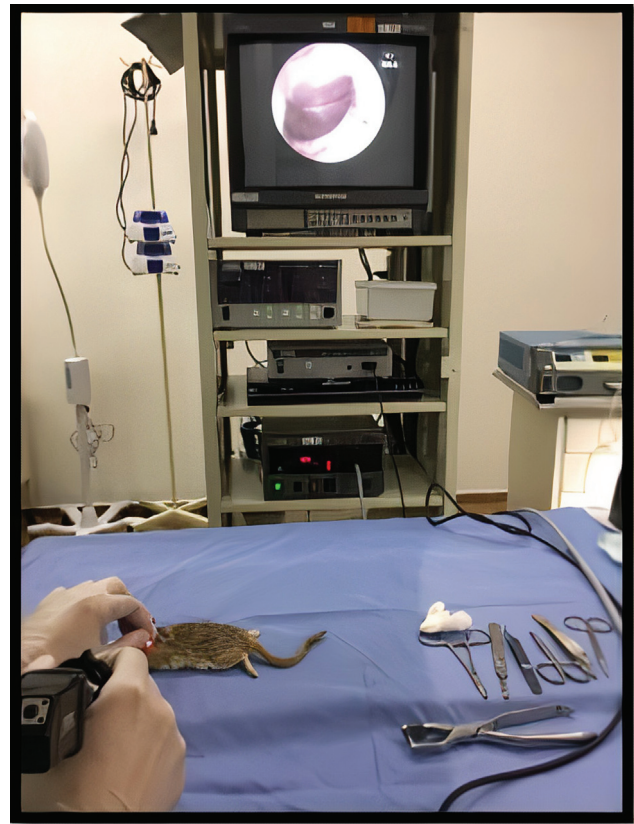


Fig. 3 Otoendoscopy.

Results

Forty Mongolian gerbils > 3 months of age of both genders were included in the study and divided into 2 groups (intervention and control) of 20 animals each (►Fig. 2). Five losses occurred throughout the study: three in the control group and two in the intervention group. However, one was included in the analysis because it was followed-up for at least 8 weeks, resulting in 72 ears studied. The groups were divided without randomization and did not demonstrate statistically significant differences in their baseline characteristics (►Table 1).

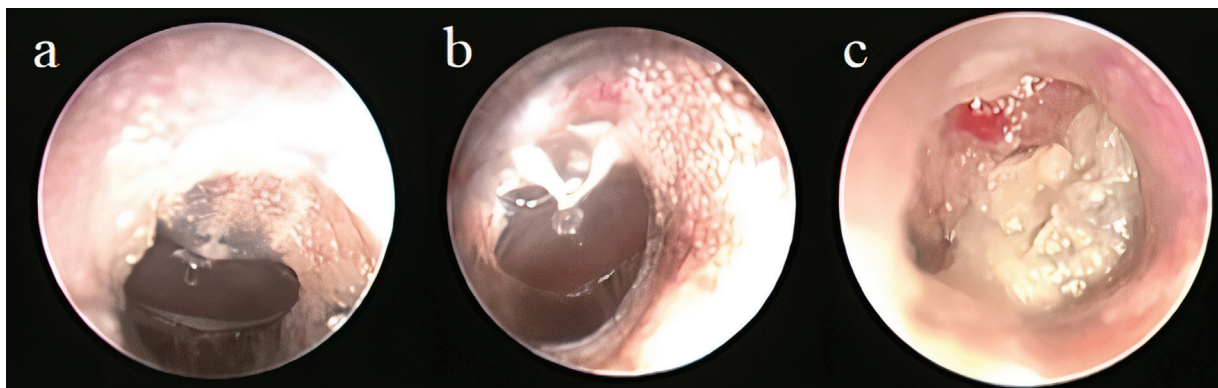


Fig. 4 Evolution of otoendoscopy in “animal 8” - intervention group. a) week zero – normal; b) week 1–pars flaccida retraction pocket; c) week 8–cholesteatoma.

Table 1 Baseline characteristics

	Intervention	Control	
Age	5.3 months	5.2 months	
Weight	88.8 g	81.8 g	$p = 0.08$
Gender (M/F)	17/3	17/3	

In the first two evaluations (week zero, week 1), no cholesteatoma was visualized by otoendoscopic evaluation. In week zero, we verified the presence of pars flaccida retraction pocket in 2 out of 38 (5.2%) ears in the intervention group and in 1 out of 34 (2.9%) ears in the control group ($p = 0.654$). In week 1, the occurrence of pars flaccida retraction pocket was observed in 6 out of 38 (15.7%) ears in the intervention group and in 3 out of 34 (8.8%) ears in the control group ($p = 0.372$).

In week 4, the presence of cholesteatoma was observed in 5 out of 38 (13.1%) ears in the intervention group and in 1 out of 34 (2.9%) ears in the control group ($p = 0.117$). Considering the ears in the intervention group that developed cholesteatoma this week, 3 out of 5 (60%) presented pars flaccida retraction pocket in the previous evaluation. Pars flaccida retraction pocket was seen in 9 out of 38 (23.6% [6 new/3 already present in the previous evaluation]) ears in the intervention group and in 6 out of 34 (17.6% [3 new/3 previous]) ears in the control group ($p = 0.528$).

In the 8th week, 8 out of 38 (21.05%) ears in the intervention group showed cholesteatoma, and 2 out of 34 (5.8%) ears in the control group ($p = 0.063$). In this week, we identified 3 new cholesteatomas compared with the previous evaluation, 2 out of 3 (66%) presented pars flaccida retraction pocket at week 4. The presence of pars flaccida retraction was seen in 9 out of 38 (23.6% [2 new/5 previous]) ears in the intervention group and in 6 out of 34 (17.6% [1 new/5 previous]) in the control group ($p = 0.528$).

In week 12, we observed the presence of cholesteatoma in 10 out of 38 (26.3%) ears in the intervention group and in 4 out of 34 (11.7%) ears in the control group ($p = 0.119$). In the intervention group, 2 new cholesteatomas emerged, 1 of which (50%) presented pars flaccida retraction pocket in the previous evaluation. Pars flaccida retraction pocket was observed in 12 out of 38 (31.5% [4 new/8 previous]) ears in the intervention group and in 6 out of 34 (17.6% [1 new/5 previous]) ears in the control group ($p = 0.172$).

At the end of the 16-week follow-up, cholesteatoma was present in 13 out of 38 (34.2%) ears in the intervention group and in 7 out of 34 (20.6%) in the control group, a difference that was not statistically significant ($p = 0.197$). In this final week, we identified 3 new cholesteatomas compared with the previous evaluation, and 2 out of 3 (66%) presented pars flaccida retraction pocket at week 12. When we consider cholesteatoma and its potential precursor, pars flaccida retraction pocket, combined, these changes were observed in 23 out of 38 (60.8%) in the intervention group and in 11 out of 34 (32.3%) in the control group, a difference with statistical significance ($p = 0.016$). Using serial otoendoscopic evalua-

tion, the development of cholesteatomas occurred, on average, at 10.5 weeks in animals in the intervention group compared with 14.2 weeks in the control group ($p = 0.052$).

Over the 16 weeks, 13 cholesteatomas developed in the intervention group and 7 in the control group (► Fig. 5). In the intervention group, 8 out of 13 (61.5%) cholesteatomas developed in ears that presented pars flaccida retraction pockets in the immediately previous evaluation, compared with 4 out of 7 (57.1%) in the control group ($p = 0.744$).

Discussion

An animal model of cholesteatoma has value in the study of pathogenesis. The Mongolian gerbil has been considered a suitable model of study, since it is the only species, other than humans, prone to spontaneous cholesteatoma. The majority of previous studies is based on observations made after closure of the external auditory canal to increase the incidence of cholesteatoma formation, followed by serial sacrifice of the animals and histological analysis of the bulla. Although these studies have shed light into many facets of this intriguing disease, it is often difficult to fully translate their findings into the human clinical scenario. Particularly, one of the most accepted theory for the development of cholesteatoma in humans is related to malfunction of the ET, with the consequent generation of negative pressure in the middle ear, inflammation, progressive retraction of the tympanic membrane and, finally, cholesteatoma formation.¹⁷ To follow this progression, the clinician can best assess this with serial inspection of the affected ear with the aid of otoscopes, microscopes or endoscopes. In other words, experimentally-induced cholesteatomas obtained by suturing the ear canal are critically dissimilar to natural occurring cholesteatomas. Similarly, relying on histopathology to make the clinical diagnosis of cholesteatoma is not consistent with real-world clinical care.

Taking this into account, we chose ET obliteration as a technique to induce cholesteatoma in the present study. We create an experimental model that could simulate, as close as possible, the development and the diagnosis of cholesteatomas in humans. To do so, we have decided to induce the development of the disease through ET obliteration and follow-up the animals with serial otoendoscopies. This method allows us to analyze evolutionary characteristics, formation pathways and cholesteatoma progression over time in the same animal, a scenario not possible using histology. To our knowledge, this is the first time that endoscopes have been used to monitor cholesteatoma in Mongolian gerbils. Using this methodology, we found that ET

16-Week follow-up

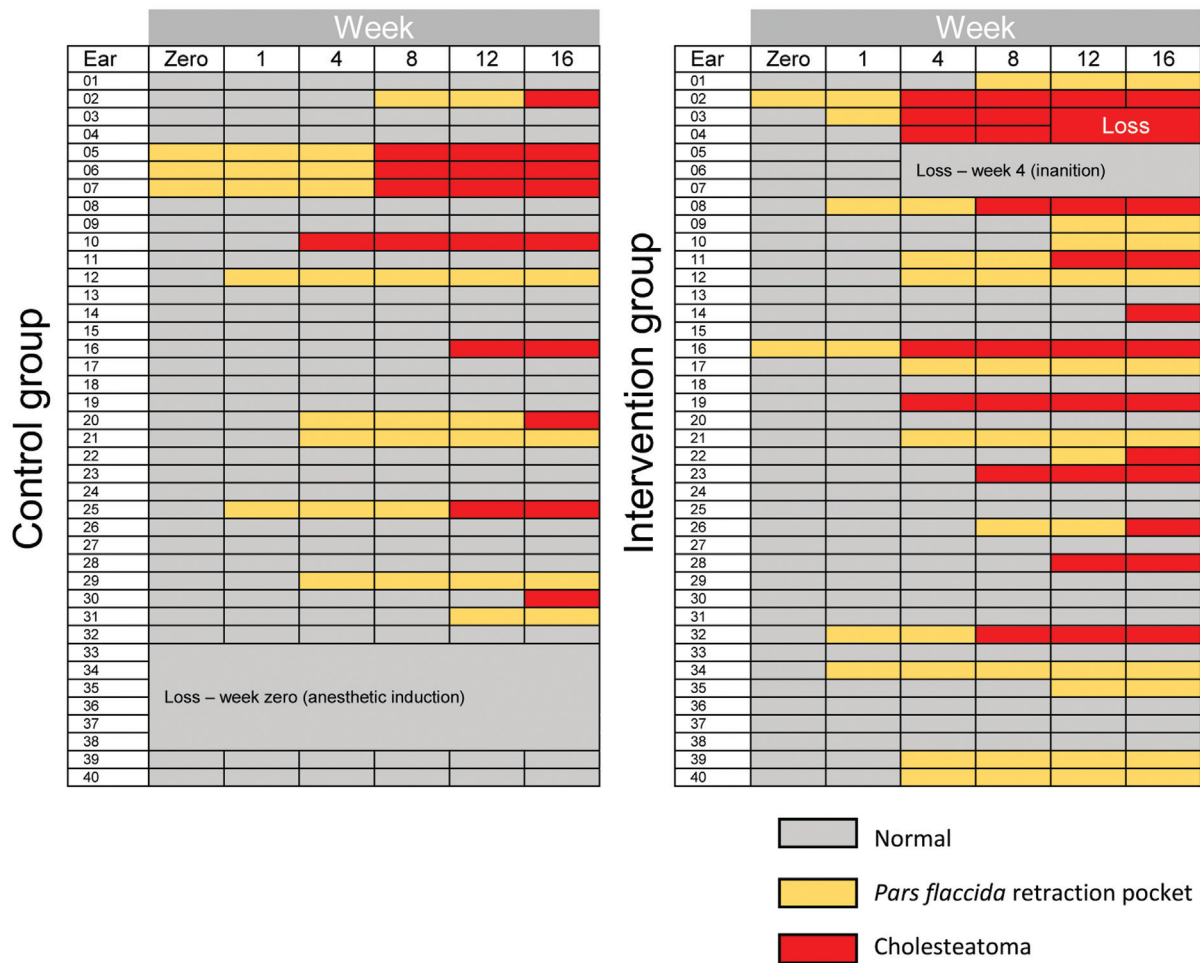


Fig. 5 Findings of each ear studied during the 16-week follow-up.

obliteration showed a tendency to increase the incidence of cholesteatoma in Mongolian gerbils, although not achieving statistical significance. However, when we included pars flaccida retraction pockets in the analysis (a condition also closely related to ET obliteration and theoretically a potential precursor of cholesteatoma), we obtained a high combined incidence of these changes in the intervention group, with statistical significance when compared with the control group. The inclusion of these findings furthers the concept of a spectral progression to cholesteatoma.

The present study has some limitations. We faced difficulties in the complete visualization of the tympanic membrane through otoscopy in cases in which the external auditory canal was completely occluded by the accumulation of keratin. The impossibility of directly visualizing the tubal ostia during the cauterization procedure was another difficulty of the present study. We cauterized in an extended way (~ 3 seconds) and bilaterally in an attempt to increase the chance of success. However, at no point in the study was there confirmation that the obliteration was really effective, which is an important limitation. Furthermore, we must be

very careful when projecting results obtained in experimental studies on humans. In addition to the evident anatomical differences, Mongolian gerbils have a substantially higher incidence of cholesteatoma than humans, demonstrating a greater propensity for the development of this pathology.

Considering our findings in serial otoendoscopies, we hypothesize that ET obliteration and the consequent desatubulization of the middle ear (negative pressure and inflammatory process) seems to increase the incidence of cholesteatoma in Mongolian gerbils. This would occur either by pars flaccida retraction and gradual accumulation of keratin, followed by the probable loss of the self-cleaning ability of the retraction pocket, or by progressive accumulation of keratin in the lateral wall of the tympanic membrane with later advancement toward the middle ear and bulla. In addition, we observed that even in the control group there is a high incidence of cholesteatomas that presented pars flaccida retraction pocket in their immediately previous evaluation. Therefore, we must consider this formation pathway (retraction pocket – cholesteatoma) as responsible for at least part of the spontaneous cholesteatomas in these

animals. Taking this into account, the present study corroborates the possibility of using Mongolian gerbils as an animal model to study also the formation pathways of cholesteatoma, and otoscopy proved to be an excellent tool for this purpose.

Conclusion

Over the 16 weeks follow-up, serial otoscopy enabled us to evaluate the formation and development of pars flaccida retraction pockets and cholesteatomas in Mongolian gerbils and proved to be an excellent diagnostic tool.

Source of Funding

Fundo de Incentivo à Pesquisa (FIPE, in the Portuguese acronym).

Conflict of Interests

The authors have no conflict of interests to declare.

References

- Da Costa SS, Cruz OLM, De Oliveira JAA. *Otorrinolaringologia Princípios e Prática*. Porto Alegre, Brazil: Artmed; 2006
- Sadé J Retraction pockets and attic cholesteatomas. *Acta Otorhinolaryngol Belg* 1980;34(01):62–84
- Yoon TH, Schachern PA, Paparella MM, Aeppli DM. Pathology and pathogenesis of tympanic membrane retraction. *Am J Otolaryngol* 1990;11(01):10–17
- Rosito LP, da Costa SS, Schachern PA, Dornelles C, Cureoglu S, Paparella MM. Contralateral ear in chronic otitis media: a histologic study. *Laryngoscope* 2007;117(10):1809–1814
- Sudhoff H, Tos M. Pathogenesis of attic cholesteatoma: clinical and immunohistochemical support for combination of retraction theory and proliferation theory. *Am J Otol* 2000;21(06):786–792
- Louw L. Acquired cholesteatoma pathogenesis: stepwise explanations. *J Laryngol Otol* 2010;124(06):587–593
- Sudhoff H, Tos M. Pathogenesis of sinus cholesteatoma. *Eur Arch Otorhinolaryngol* 2007;264(10):1137–1143
- Sadé J, Avraham S, Brown M. Atelectasis, retraction pockets and cholesteatoma. *Acta Otolaryngol* 1981;92(5-6):501–512
- Chole RA, Henry KR, McGinn MD. Cholesteatoma: spontaneous occurrence in the Mongolian gerbil *Meriones unguiculatus*. *Am J Otol* 1981;2(03):204–210
- McGinn MD, Chole RA, Henry KR. Cholesteatoma induction. Consequences of external auditory canal ligation in gerbils, cats, hamsters, guinea pigs, mice and rats. *Acta Otolaryngol* 1984;97(3-4):297–304
- Kim HJ, Chole RA. Experimental models of aural cholesteatomas in Mongolian gerbils. *Ann Otol Rhinol Laryngol* 1998;107(02):129–134
- McGinn MD, Chole RA, Henry KR. Cholesteatoma. Experimental induction in the Mongolian Gerbil, *Meriones Unguiculus*. *Acta Otolaryngol* 1982;93(1-2):61–67
- Tinling SP, Chole RA. Gerbilline cholesteatoma development. Part II: temporal histopathologic changes in the tympanic membrane and middle ear. *Otolaryngol Head Neck Surg* 2006;134(06):953–960
- Tinling SP, Chole RA. Gerbilline cholesteatoma development Part III. Increased proliferation index of basal keratinocytes of the tympanic membrane and external ear canal. *Otolaryngol Head Neck Surg* 2006;135(01):116–123
- Kim HJ, Tinling SP, Chole RA. Increased proliferation and migration of epithelium in advancing experimental cholesteatomas. *Otol Neurotol* 2002;23(06):840–844
- Wolfman DE, Chole RA. Experimental retraction pocket cholesteatoma. *Ann Otol Rhinol Laryngol* 1986;95(6 Pt 1):639–644
- Rosito LPS, Sperling N, Teixeira AR, Selaimen FA, da Costa SS. The role of tympanic membrane retractions in cholesteatoma pathogenesis. *BioMed Res Int* 2018;2018:9817123