

Sternocleidomastoid Muscle Flap after Parotidectomy

Ahmad Abdel-Fattah Nofal¹ Morsi Mohamed²

¹Department of Otorhinolaryngology-Head and Neck Surgery, Zagazig University, Zagazig, Egypt

²Department of General Surgery, Zagazig University, Zagazig, Egypt

Address for correspondence Ahmad Abdel-Fattah Nofal, MD, Department of Otorhinolaryngology-Head and Neck Surgery, Zagazig University, Zagazig 46166, Egypt (e-mail: nofal_9999@hotmail.com).

Int Arch Otorhinolaryngol 2015;19:319–324.

Abstract

Introduction Most patients after either superficial or total parotidectomy develop facial deformity and Frey syndrome, which leads to a significant degree of patient dissatisfaction.

Objective Assess the functional outcome and esthetic results of the superiorly based sternocleidomastoid muscle (SCM) flap after superficial or total parotidectomy.

Methods A prospective cohort study for 11 patients subjected to parotidectomy using a partial-thickness superiorly based SCM flap. The functional outcome (Frey syndrome, facial nerve involvement, and ear lobule sensation) and the esthetic results were evaluated subjectively and objectively.

Results Facial nerve palsy occurred in 5 cases (45%), and all of them recovered completely within 6 months. The Minor starch iodine test was positive in 3 patients (27%), although only 1 (9%) subjectively complained of gustatory sweating. The designed visual analog score completed by the patients themselves ranged from 0 to 3 with a mean of 1.55 ± 0.93 ; the scores from the blinded evaluators ranged from 1 to 3 with a mean 1.64 ± 0.67 .

Conclusion The partial-thickness superiorly based SCM flap offers a reasonable cosmetic option for reconstruction following either superficial or total parotidectomy by improving the facial deformity. The flap also lowers the incidence of Frey syndrome objectively and subjectively with no reported hazard of the spinal accessory nerve.

Keywords

- ▶ parotid gland
- ▶ facial paralysis
- ▶ gustatory sweating
- ▶ surgical flaps

Introduction

Parotidectomy, either superficial or total, is an effective treatment of benign and malignant neoplasm of the parotid gland, but most patients are left with a facial deformity in the preauricular and retromandibular region and Frey syndrome. Both facial deformity and Frey syndrome often lead to a significant degree of patient dissatisfaction.^{1–3}

The incidence of Frey syndrome after parotidectomy is ~94% when a starch iodine test is performed,⁴ but only ~12 to 54% in patients who are symptomatic.^{5,6} It is believed to be caused by aberrant regeneration of the injured parasympathetic nerve fibers of the parotid gland. The nerve fibers subsequently innervate the

sweat glands of the overlying skin causing gustatory sweating begin within 2 weeks to 2 years.⁶

Many procedures have been introduced to decrease these complications, such as fascia lata grafts⁷; dermal-fat-fascia free grafts⁸; dermal-fat grafts⁹; the platysma muscle flaps¹⁰; temporoparietal fascia flaps¹¹; sternocleidomastoid muscle (SCM) flaps, both superiorly and inferiorly based^{12–14}; superficial musculoaponeurotic system (SMAS) flaps^{14–16}; vascularized fat grafts¹⁷; vascularized dermis-fat grafts¹⁸; and polytetrafluoroethylene implants.¹⁹

The SCM receives its blood supply superiorly from the occipital artery, the superior thyroid artery in its midportion,

received
January 27, 2015
accepted
February 23, 2015
published online
March 27, 2015

DOI <http://dx.doi.org/10.1055/s-0035-1549155>.
ISSN 1809-9777.

Copyright © 2015 by Thieme Publicações Ltda, Rio de Janeiro, Brazil

License terms



and the transverse cervical artery inferiorly; therefore the muscle can be used either as a superiorly or inferiorly based flap. It has been used as a muscular or myocutaneous flap for orofacial reconstruction,²⁰ but it can also be used as a simple means to eliminate the contour deformity after parotidectomy by filling the depression deformity and preserving facial symmetry.²¹

The SCM flap has many advantages over the SMAS flap, such as potentially decreased cosmetic defect, less risk of skin injuries during flap design, minimal risk of late skin necrosis, an ability to provide a larger width and length of muscle tissue that can be interposed, and ease with flap design and axis of rotation after parotidectomy.¹³

Patients and Methods

This study was performed in Department of Otolaryngology Head and Neck Surgery and in the general surgery department in the university hospital from June 2011 to December 2014. Eleven patients who had superficial or total parotidectomy for benign parotid lesions with a benign preoperative fine-needle cytology result were studied. Patients with recurrent parotid lesion, malignant lesion, lesions with preoperative facial nerve affection, or previous radiotherapy were excluded from the study. All the patients were followed for at least 12 months.

All patients gave a full history and were given a complete local and systemic examination, including neck ultrasonography and preoperative fine-needle cytology, with computed tomography and magnetic resonance imaging obtained in selected cases.

The aim of this prospective cohort study is to evaluate the functional outcome and esthetic results of the partial-thickness superiorly based SCM flap after superficial or total parotidectomy for benign parotid lesions. The functional outcome involved Frey syndrome, the facial nerve affection, and ear lobule sensation. The esthetic results evaluated the facial deformity (preauricular and retromandibular depression) and the incision scar. Frey syndrome was evaluated objectively by Minor starch iodine test by applying 1% tincture of iodine in region of the face and upper neck, which was allowed to dry and then dusted with starch; chewing on a lemon wedge was used to assess the gustatory stimulus. The facial nerve function was evaluated by a scale evaluating all four regions of the face (forehead, eye, midface, and lower lip) to assess which branch was affected (frontal, zygomatic, buccal, or marginal mandibular). The facial

nerve function was evaluated subjectively by a visual analog scale (–Table 1), which was completed by the patient and by three blinded nursing staff members (0 = normal appearance symmetrical to the opposite side; 1 = minimal asymmetry, barely noticeable from a short distance; 2 = mild asymmetry, noticeable but with no disfigurement; 3 = moderate asymmetry, mainly in the preauricular area, apparent when looking at the patient; 4 = severe asymmetry, with deep preauricular and retromandibular groove; and 5 = severe asymmetry, with deep preauricular and retromandibular groove with obvious scar). The visual analog scale was also used to evaluate cosmetic facial disfigurement and to subjectively evaluate gustatory sweating.

Surgical Technique

The surgery was done under general anesthesia with the patients in supine position and head tilted to the opposite side. All the facial incisions were hidden in the preauricular crease, and neck incisions were hidden in the curvilinear crease ~3 cm below the angle of the mandible. These incisions were connected by gentle curve around the lobule of the ear and extended posteriorly behind the mastoid tip and SCM. Superficial parotidectomy or total parotidectomy (if the deep lobe was involved) was performed with conventional identification and preservation of the facial nerve and its branches. Then a superiorly based partial-thickness flap was taken from the SCM and rotated anteriorly to be sutured by 3–0 Vicryl interrupted sutures to the remnants of the parotid fascia and preserved healthy parotid tissue. This covered the facial nerve and its branches, retromandibular vein, and external carotid artery and its terminal branches, filling the defect that appears after parotidectomy, to achieve better facial contour restoration (–Fig. 1). The thickness of the flap varied from case to case according to the size of the gap and the type of the operation (superficial or total parotidectomy), and the length of the flap was designed before cutting the SCM by measuring the length of the defect. Care was taken to avoid injury to the spinal accessory nerve during cutting and dissection of the flap, and the flap was sutured to cover all the parotid gland bed from the zygomatic arch superiorly to the level just below the mandible. Then the suction drain was placed deep to the flap before closure of the wound.

Results

This study was performed in 6 male (55%) and 5 female (45%) patients with a mean age 49.5 year (range 34 to 68 years).

Table 1 The designed visual analog score

Degree	Appearance
0	Normal appearance, symmetrical to the opposite side
1	Minimal asymmetry, barely noticeable from a short distance
2	Mild asymmetry, noticeable but with no disfigurement
3	Moderate asymmetry, mainly in the preauricular area, apparent when looking at the patient
4	Severe asymmetry, with deep preauricular and retromandibular groove
5	Severe asymmetry, with deep preauricular and retromandibular groove with obvious scar

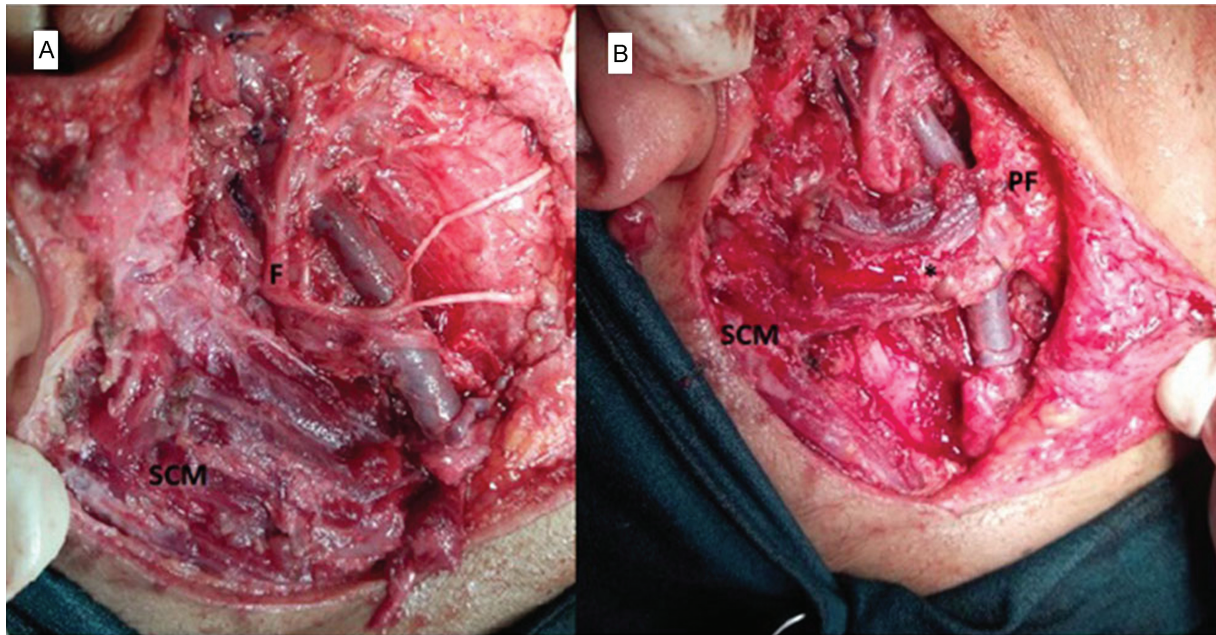


Fig. 1 (A) The parotid bed after total parotidectomy showing sternocleidomastoid muscle (SCM) and the facial nerve (F) with its branches completely preserved. (B) The parotid bed after applying the superiorly based SCM flap (*) and suturing it with the parotid fascia (PF) to cover the parotid bed after total parotidectomy.

Nine patients underwent superficial parotidectomy and two had total parotidectomy as the lesion affected the deep lobe. The final histopathologic diagnoses were pleomorphic adenoma (mixed tumor) in 8 cases and Warthin tumor in 3 cases.

The drain was removed on the first postoperative day, and all patients were discharged on the second postoperative day. The extra operating time required for design and transposition of the superiorly based partial-thickness SCM flap was only ~10 minutes. None of our patients suffered from trapezius muscle weakness, but one patient had postoperative hematoma, which was managed by aspiration and compression with no need for exploration.

All the patients were evaluated regarding the facial nerve and great auricular nerve function in the first postoperative day and at 6 months postoperatively. Frey syndrome was evaluated objectively and subjectively at 6 months postoperatively, and the cosmetic appearance was also evaluated by visual analog score at 6 months postoperatively (► **Table 2**).

Five patients (45%) complained of postoperative facial palsy; in four of them, only the marginal mandibular branch was affected, and in one, both the marginal mandibular and zygomatic branches were affected. All recovered completely within 6 months with no permanent facial nerve affliction. The great auricular nerve and thus the sensation of the lobule of the ear was affected in 7 cases (64%) immediately postoperatively, 2 of which recovered and 5 (45%) of which became permanent.

Frey syndrome or gustatory sweating was assessed at 6 months postoperatively. Three patients (27%) were positive to Minor starch iodine test, of whom only 1 (9%) patient complained of gustatory sweating in the preauricular region of ~2 cm² surface area.

A visual analog scale was designed to evaluate cosmetic results at 6 months postoperatively. The patient-completed scores ranged from 0 to 3 with a mean of 1.55 ± 0.93 . Scores from three blinded nursing staff ranged from 1 to 3 with a mean of 1.64 ± 0.67 . The patient in ► **Fig. 1** was evaluated 6 months postoperatively and was scored 1 by the patient and 1 by the blinded persons using the visual analog score (► **Fig. 2**).

Discussion

Most parotid tumors are benign in nature with long life expectancy anticipated, and so cosmetic considerations after resection are important. Tumors of the parotid gland are generally removed using a standard external bayonet-shaped incision without reconstruction of the parotid bed.²²

Many ideas for achieving better aesthetic result and preventing gustatory sweating have been discussed. Appiani and Delfino were the first to describe the combined use of a facelift incision for parotidectomy and the use of a sternomastoid muscle flap for reconstruction.²³ Terris et al used the facelift incision as an important innovation,²² which improves the postoperative appearance by avoiding the obvious cervical scar. Hussain and Murray preserved the superficial lobe for deep lobe parotid tumors to get a better aesthetic outcome.²⁴ Lin et al used endoscopy-assisted parotidectomy for benign tumors.²⁵ Foustanos and Zavrvides said that the facelift incision combined with SMAS advancement flap might be ideal to alleviate the unsightly facial depression and prevent conspicuous formation of scar tissue and gustatory sweating.¹⁶

In this study, we used the superiorly base SCM flap after either superficial or deep parotidectomy and sutured it

Table 2 Patients' facial nerve function, occurrence of Frey syndrome, and cosmetic appearance

Patient	Age (y)	Sex	Postoperative facial nerve function		Postoperative sensation in the lobule of the ear		Frey syndrome (6 mo postoperatively)		Cosmetic appearance by visual analog score (6 mo postoperatively)	
			1 d	6 mo	1 d	6 mo	Objectively (Minor starch test)	Subjectively	Patient evaluation	Blinded evaluation
Pleomorphic adenoma	48	M	Dropped angle of the mouth	Normal	Lost	Lost	-	-	1	2
Pleomorphic adenoma	38	F	Normal	Normal	Lost	Normal	-	-	2	1
Pleomorphic adenoma	44	F	Normal	Normal	Normal	Normal	+	+ in the preauricular area	3	3
Warthin tumor	68	M	Dropped angle of the mouth	Normal	Lost	Lost	-	-	0	1
Pleomorphic adenoma	34	M	Normal	Normal	Normal	Normal	-	-	1	1
Warthin tumor	61	M	Normal	Normal	Normal	Normal	-	-	1	1
Pleomorphic adenoma	49	F	Dropped angle of the mouth & inability to close the eye completely	Normal	Lost	Lost	+	-	3	2
Pleomorphic adenoma	50	M	Normal	Normal	Lost	Normal	-	-	2	2
Pleomorphic adenoma	48	F	Dropped angle of the mouth	Normal	Normal	Normal	+	-	1	1
Pleomorphic adenoma	39	F	Dropped angle of the mouth	Normal	Lost	Lost	-	-	2	2
Warthin tumor	66	M	Normal	Normal	Lost	Lost	-	-	1	2

Five patients (45%) had postoperative facial palsy. Three cases with Frey syndrome were positive only to Minor starch iodine test. The designed visual analog score completed by the patients themselves ranged from 0 to 3 with a mean of 1.55 ± 0.93 ; the scores from the blinded evaluators ranged from 1 to 3 with a mean 1.64 ± 0.67 .

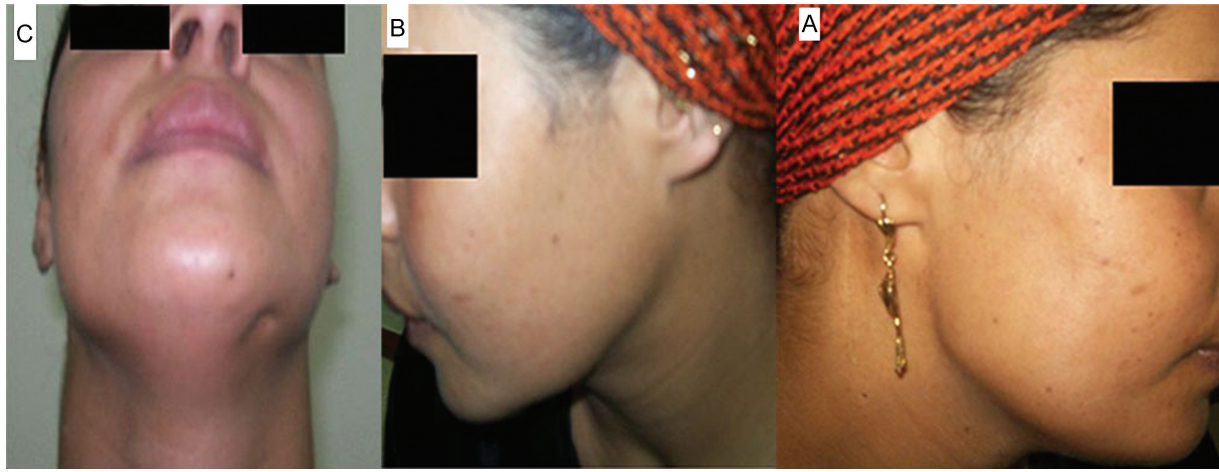


Fig. 2 Six months after using superiorly based sternocleidomastoid muscle flap after right-side total parotidectomy: (A) frontal view; (B) left normal side view; (C) right operated side view. There was no facial deformity and no significant difference between the normal and operated side.

using interrupted sutures to the remnants of the parotid fascia and preserved healthy parotid tissue, but Fee and Tran used inferiorly based SCM flap to reconstruct after total parotidectomy only and sutured it to the masseter muscle.²⁶

We avoided use of the SCM flap in malignant and highly recurrent cases not only for fear of burying the tumor recurrence and delaying its detection but also because the subsequent surgical procedure(s) poses more risk to the facial nerve and results in greater deformity than the original unreconstructed defect, as shown by other studies.²⁶

Frey syndrome was improved subjectively (9%) and objectively (27%, using Minor iodine starch test) in this study, in contrast to Gooden et al²⁷ and Kornblut et al,²⁸ who did not show a benefit in preventing Frey syndrome after SCM flap; however, other studies showed a beneficial effect,^{14,26,29} which may be due to the short duration of evaluation (6 months postoperatively) in this study as aberrant regeneration of the injured parasympathetic nerve fibers of the parotid gland may take as long as 2 or even 8 years.³⁰

The cosmetic result in this study was mostly satisfactory using a visual analog scale (scores of 0 = normal appearance to 5 = severe asymmetry with bad scar) completed by the patients themselves or by blinded persons. The patient-completed scores ranged from 0 to 3 with a mean of 1.55 ± 0.93 and the scores from the blinded health care staff ranged from 1 to 3 with a mean of 1.64 ± 0.67 .

Conclusion

The partial-thickness superiorly based SCM flap offers a reasonable cosmetic option for reconstruction following either superficial or total parotidectomy by improving the facial deformity and also lowers the incidence of Frey syndrome objectively and subjectively with no reported hazard of the spinal accessory nerve.

References

- Blumenfeld RJ, Friedman JE. Intratympanic surgical treatment of Frey's syndrome. *Arch Otolaryngol* 1967;86(1):2-7
- Smith RO Jr, Hemenway WG, Stevens KM, Ratzler ER. Jacobson's neurectomy for Frey's syndrome. *Am J Surg* 1970;120(4):478-481
- Yu LT, Hamilton R. Frey's syndrome: prevention with conservative parotidectomy and superficial musculoaponeurotic system preservation. *Ann Plast Surg* 1992;29(3):217-222
- Kornblut AD, Westphal P, Miehle A. A reevaluation of the Frey syndrome following parotid surgery. *Arch Otolaryngol* 1977;103(5):258-261
- Laage-Hellman JE. Gustatory sweating and flushing after conservative parotidectomy. *Acta Otolaryngol* 1957;48(3):234-252
- Morfit HM, Kramish D. Auriculotemporal syndrome (Frey's syndrome) following surgery of parotid tumors. *Am J Surg* 1961;102:777-780
- Wallis KA, Gibson T. Gustatory sweating following parotidectomy: correction by a fascia lata graft. *Br J Plast Surg* 1978;31(1):68-71
- Conley JJ, Clairmont AA. Dermal-fat-fascia grafts. *Otolaryngology* 1978;86(4 Pt 1):ORL-641-ORL-649
- Nosan DK, Ochi JW, Davidson TM. Preservation of facial contour during parotidectomy. *Otolaryngol Head Neck Surg* 1991;104(3):293-298
- Kim SY, Mathog RH. Platysma muscle-cervical fascia-sternocleidomastoid muscle (PCS) flap for parotidectomy. *Head Neck* 1999;21(5):428-433
- Rubinstein RY, Rosen A, Leeman D. Frey syndrome: treatment with temporoparietal fascia flap interposition. *Arch Otolaryngol Head Neck Surg* 1999;125(7):808-811
- Bugis SP, Young JE, Archibald SD. Sternocleidomastoid flap following parotidectomy. *Head Neck* 1990;12(5):430-435
- Sanabria A, Kowalski LP, Bradley PJ, et al. Sternocleidomastoid muscle flap in preventing Frey's syndrome after parotidectomy: a systematic review. *Head Neck* 2012;34(4):589-598
- Casler JD, Conley J. Sternocleidomastoid muscle transfer and superficial musculoaponeurotic system plication in the prevention of Frey's syndrome. *Laryngoscope* 1991;101(1 Pt 1):95-100
- Rappaport I, Allison GR. Superficial musculoaponeurotic system amelioration of parotidectomy defects. *Ann Plast Surg* 1985;14(4):315-323

- 16 Foustanos A, Zavrides H. Face-lift approach combined with a superficial musculoaponeurotic system advancement flap in parotidectomy. *Br J Oral Maxillofac Surg* 2007;45(8):652–655
- 17 Allen RJ, Kaplan J. Reconstruction of a parotidectomy defect using a paraumbilical perforator flap without deep inferior epigastric vessels. *J Reconstr Microsurg* 2000;16(4):255–257, discussion 258–259
- 18 Baker DC, Shaw WW, Conley J. Microvascular free dermis-fat flaps for reconstruction after ablative head and neck surgery. *Arch Otolaryngol* 1980;106(8):449–453
- 19 Dulguerov P, Quinodoz D, Cosendai G, Piletta P, Marchal F, Lehmann W. Prevention of Frey syndrome during parotidectomy. *Arch Otolaryngol Head Neck Surg* 1999;125(8):833–839
- 20 Marx RE, McDonald DK. The sternocleidomastoid muscle as a muscular or myocutaneous flap for oral and facial reconstruction. *J Oral Maxillofac Surg* 1985;43(3):155–162
- 21 Chow TL, Lam CY, Chiu PW, Lim BH, Kwok SR. Sternomastoid-muscle transposition improves the cosmetic outcome of superficial parotidectomy. *Br J Plast Surg* 2001;54:409–411
- 22 Terris DJ, Tuffo KM, Fee WE Jr. Modified facelift incision for parotidectomy. *J Laryngol Otol* 1994;108(7):574–578
- 23 Appiani E, Delfino MC. Plastic incisions for facial and neck tumors. *Ann Plast Surg* 1984;13(4):335–352
- 24 Hussain A, Murray DP. Preservation of the superficial lobe for deep-lobe parotid tumors: a better aesthetic outcome. *Ear Nose Throat J* 2005;84(8):518–524, 520–522, 524
- 25 Lin SD, Tsai CC, Lai CS, Lee SS, Chang KP. Endoscope-assisted parotidectomy for benign parotid tumors. *Ann Plast Surg* 2000;45(3):269–273
- 26 Fee WE Jr, Tran LE. Functional outcome after total parotidectomy reconstruction. *Laryngoscope* 2004;114(2):223–226
- 27 Gooden EA, Gullane PJ, Irish J, Katz M, Carroll C. Role of the sternocleidomastoid muscle flap preventing Frey's syndrome and maintaining facial contour following superficial parotidectomy. *J Otolaryngol* 2001;30(2):98–101
- 28 Kornblut AD, Westphal P, Miehke A. The effectiveness of a sternomastoid muscle flap in preventing post-parotidectomy occurrence of the Frey syndrome. *Acta Otolaryngol* 1974;77(5):368–373
- 29 Sood S, Quraishi MS, Jennings CR, Bradley PJ. Frey's syndrome following parotidectomy: prevention using a rotation sternocleidomastoid muscle flap. *Clin Otolaryngol Allied Sci* 1999;24(4):365–368
- 30 Malatskey S, Rabinovich I, Fradis M, Peled M. Frey syndrome—delayed clinical onset: a case report. *Oral Surg Oral Med Oral Pathol Oral Radiol Endod* 2002;94(3):338–340