

# An Emergent Entity: Indolent Mucormycosis of the Paranasal Sinuses. A Multicenter Study

Erika Celis-Aguilar<sup>1</sup> Alan Burgos-Páez<sup>1</sup> Nadia Villanueva-Ramos<sup>1</sup> José Solórzano-Barrón<sup>1</sup>  
 Alma De La Mora-Fernández<sup>1</sup> Juan Manjarrez-Velázquez<sup>2</sup> Sergio Verdiales-Lugo<sup>1</sup>  
 Lucero Escobar-Aispuro<sup>1</sup> Perla Becerril<sup>3</sup> Ana Valdez-Flores<sup>4</sup> Francisco Javier Merino-Ramírez<sup>4</sup>  
 Carmen Beatriz Caballero-Rodríguez<sup>4</sup>

<sup>1</sup>Department of Otolaryngology, Centro de Investigación y Docencia en Ciencias de la Salud (CIDOCS) de la Universidad Autónoma de Sinaloa, Culiacán, Sinaloa, México

<sup>2</sup>Department of Otolaryngology, Culiacan General Hospital, Culiacán, Sinaloa, México

<sup>3</sup>Department of Otolaryngology, General Hospital Regional No. 1 "Ignacio García Téllez" del IMSS, Mérida, Yucatán, México

<sup>4</sup>Department of Pathology, Centro de Investigación y Docencia en Ciencias de la Salud (CIDOCS), Universidad Autónoma de Sinaloa, Culiacán, Sinaloa, México

**Address for correspondence** Erika Celis-Aguilar, MD, Blvd. Alfonso G. Calderón No.2193 Poniente, Cons. 603. Desarrollo Urbano Tres Ríos. Zip code 80050. Culiacán, Sinaloa, México (e-mail: erikacelis@hotmail.com).

Int Arch Otorhinolaryngol 2019;23:92–100.

## Abstract

**Introduction** Indolent or chronic mucormycosis is a rare entity that affects both immunosuppressed and immunocompetent individuals. Additionally, its clinical evolution is nonspecific and there is no standardized treatment for this condition.

**Objective** To describe the clinical characteristics and management of patients with indolent mucormycosis.

**Methods** In the project of study with chart review in the Interinstitutional secondary care centers, patients with evidence of indolent mucormycosis, defined as pathological confirmation of nasal/paranasal sinus mucormycosis for more than 1 month, were included. All patients underwent complete laboratory workup, imaging studies, surgical treatment and adequate follow-up. No evidence of disease status was defined when patient had subsequent biopsies with no evidence of mucormycosis.

**Results** We included seven patients, three female and four male subjects. The mean age was 53.14 years. Four patients were immunosuppressed and three immunocompetent. Among the immunosuppressed patients three had diabetes and one had dermatomyositis. The symptoms were nonspecific: facial pain/headache, mucoid discharge and cacosmia were the ones most frequently reported. Maxillary sinus involvement was present in all patients. Two immunosuppressed subjects received amphotericin. Posaconazole was the only treatment in one immunosuppressed patient. All immunocompetent patients had single paranasal sinus disease and received only surgical treatment. All patients are alive and free of disease.

**Conclusion** Indolent mucormycosis is a new and emerging clinical entity in immunosuppressed and immunocompetent patients. Single paranasal sinus disease is a frequent presentation and should not be overlooked as a differential diagnosis in these patients. Immunocompetent patients should only be treated surgically.

## Keywords

- ▶ mucormycosis
- ▶ mucorales
- ▶ paranasal sinuses
- ▶ sinusitis
- ▶ mycoses
- ▶ chronic mucormycosis

received  
 October 29, 2017  
 accepted  
 May 23, 2018  
 published online  
 October 24, 2018

DOI <https://doi.org/10.1055/s-0038-1667005>.  
 ISSN 1809-9777.

Copyright © 2019 by Thieme Revinter Publicações Ltda, Rio de Janeiro, Brazil

License terms



## Introduction

Mucormycosis is commonly a fatal infection caused by fungi of the order Mucorales, with *Rhizopus* being the most common species associated with this disease.<sup>1</sup> Other isolated species are *Absidia*, *Mucor* and *Rhizomucor*.<sup>2,3</sup> Histologically, it presents with hyphae that are broad-based and non septated with right angles.<sup>4,5</sup> Since this is predominantly a fulminant disease, it is potentially lethal.<sup>5</sup> Patients are usually immunosuppressed individuals, and the clinical hallmark has been vascular invasion with tissue necrosis.<sup>6</sup> Nonetheless, new cases of indolent mucormycosis are being reported, occurring among immunosuppressed<sup>4,7-9</sup> and immunocompetent patients.<sup>10-15</sup> The clinical characteristics are distinguished by its chronic evolution,<sup>14</sup> nonspecific symptoms and in some cases absence of frank vascular invasion and necrosis.<sup>5</sup> Additionally, single paranasal sinus disease is also a frequent presentation.<sup>11</sup> We currently address this new form of disease with recent evidence. The objective of this study is to describe the clinical characteristics and management of patients with indolent mucormycosis.

## Methods

### Patients

The patients were recruited from November 2012 to November 2016. This study was a multicenter clinical chart review conducted in secondary care centers. Indolent mucormycosis was defined as pathological evidence of nasal/paranasal sinus mucormycosis for longer than 1 month. The inclusion criteria were patients with indolent mucormycosis who had pathological confirmation, complete imaging studies and underwent surgical/medical treatment with adequate follow-up.

This is an interinstitutional study approved by the ethical committees of the hospitals involved and led by Centro de Investigación y Docencia en Ciencias de la Salud (CIDOCS) de la Universidad Autónoma de Sinaloa, Sinaloa, Mexico. A signed informed consent was obtained from all patients.

### Evaluation and Surgical Technique

All patients were evaluated by the otolaryngology and the infectiology departments. All patients underwent imaging, laboratory workup and surgical treatment. The patients were operated on by certified interinstitutional otolaryngologists.

The surgical procedures consisted in external maxillary approach (modified Caldwell-Luc procedure), endoscopic ethmoidectomy and antrostomy. The endoscopic procedure consisted in the removal of the uncinated process, ethmoid bulla; the resection of anterior and posterior ethmoid cells was done depending on the extension of disease. The identification of the natural maxillary ostium was performed and enlarged with a backbite and a 45° Blakesley forceps.

All surgical specimens were evaluated by two certified pathologists.

### Statistical Analysis

The data were gathered by clinical chart review. The statistical analysis was performed using the Statistical Package for the Social Sciences (SPSS) 18.0 (SPSS Inc., Chicago, IL, USA).

The statistical analysis included descriptive statistics (mean and standard deviation).

## Results

### Demographic Data

We included seven patients, three female and four male subjects. The mean age was 53.14 years. Four patients were immunosuppressed and three were immunocompetent. Maxillary sinus involvement was present in all patients.

Among the immunosuppressed patients, three had diabetes and one had dermatomyositis. The symptoms were nonspecific. Facial pain, mucoid discharge and cacosmia were the symptoms most frequently reported. (See ► **Table 1**).

The duration of symptoms ranged from 1 to 28 months. Two patients had asymptomatic mucormycosis, found incidentally on computed tomography (CT) scan (cases 3 and 5).

### Immunosuppressed Cases

Case 1 was a 38-year-old female patient who presented initially with fulminant mucormycosis disease. Middle turbinate resection, modified Caldwell-Luc procedure and endoscopic ethmoidectomy were urgently performed. Necrosis was seen intraoperatively in the middle turbinate. In spite of ocular involvement (proptosis, pupillary dilation and restriction of ocular movements), we decided on ocular preservation and hospitalization for a period of 1 month, with strict metabolic control, and administration of up to 3g of amphotericin. At the end of the month, she was asymptomatic, and ocular involvement was stable. Nonetheless, the magnetic resonance imaging (MRI) and CT scan showed progressive orbital apex pathology. An intraconal biopsy was performed, with final pathology result of mucormycosis. She underwent orbital exenteration with confirmation of orbital disease. Subsequent biopsies of maxillary and ethmoid sinus were negative. This case was included because it shows a patient with persistent disease that developed chronic symptoms. Once amphotericin was prescribed for 1 month, the patient had no disease progression and no additional symptoms. The disease was confined to the orbital fat. The fulminant course was arrested and led to an indolent one. See ► **Fig. 1**.

Case two was diagnosed with diabetes during her hospitalization. Initial nasal endoscopy revealed only middle meatus edema. Surgical findings were compatible with fungus ball and necrosis of maxillary mucosa. Pathology study of the mucosa revealed mucormycosis. Two subsequent biopsies were performed, and the last biopsy showed no evidence of disease. See ► **Fig. 2**.

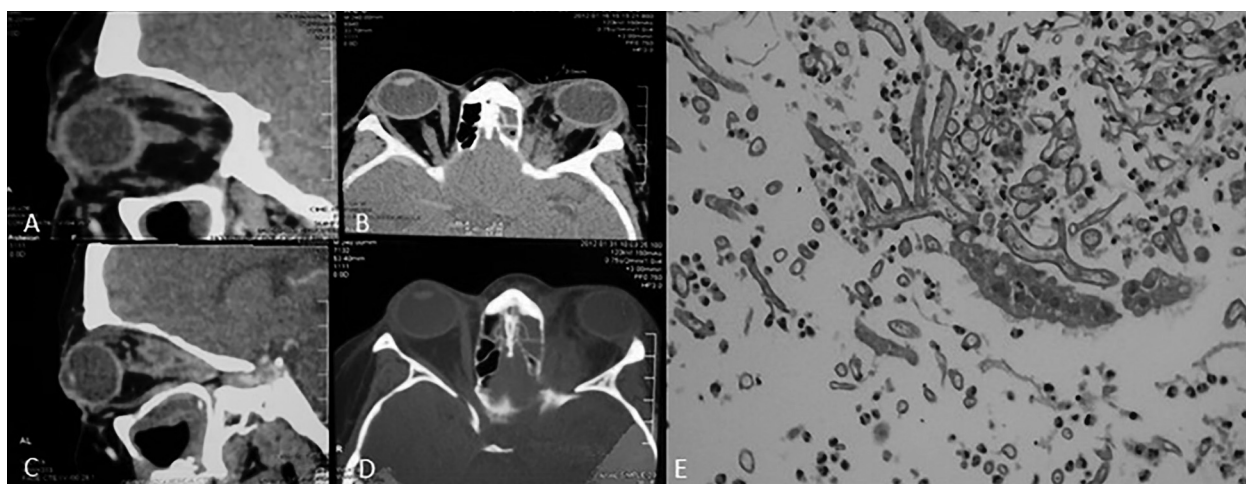
Case three was asymptomatic. The patient had diabetes and renal failure and, since he was a candidate for a kidney transplant, a paranasal sinus CT scan was performed. Sinus occupation required mandatory surgery, which later led to the diagnosis of mucormycosis. Subsequent biopsies were negative. ► **Fig. 3** shows histopathological confirmation.

Case four had dermatomyositis. Patient complained of nasal obstruction, facial fullness, chronic rhinorrhea with posterior discharge and cough. Paranasal sinus CT scan was performed with left maxillary sinus occupation. See ► **Table 1** for additional symptoms and treatment. See ► **Fig. 4** for preoperative CT scan.

**Table 1** Demographics and clinical characteristics of the study population

Patient number	Sex	Age	Immunocompetent status	Anatomic localization	Duration of symptoms (mo)	Clinical features	Treatment	Follow-up
1	F	38	Immunosuppressed	Rhino-orbital Left maxillary Left ethmoid Left orbit	1	Maxillary pain, proptosis, pupil dilation, restriction of ocular movements. Acute facial pain	Antrostomy, Caldwell Luc, ethmoidectomy, orbital exenteration, liposomal amphotericin B with a total accumulative dose of 3 g, posaconazole 45 days	4 years follow up NED
2	F	61	Immunosuppressed	Left maxillary sinus	6	Headache, facial pain, purulent rhinorrhea, halitosis, cacosmia.	Caldwell Luc, endoscopic antrostomy, amphotericin B 750 mg	2.5 years follow up, NED
3	M	54	Immunosuppressed	Right maxillary sinus	NA	Asymptomatic	Caldwell Luc Posaconazole	2 years follow up, NED
4	F	46	Immunosuppressed	Left maxillary sinus	28	Nasal obstruction, facial fullness, chronic rhinorrhea with posterior discharge and cough.	Caldwell Luc	2 months
5	M	77	Immunocompetent	Left maxillary sinus	NA	Contralateral nasal mass Right Nasal obstruction, Left side asymptomatic.	Resection of contralateral mass Left Caldwell Luc and endoscopic antrostomy	1 year follow up, NED
6	M	54	Immunocompetent	Right maxillary sinus	8	Headache, cacosmia	Caldwell Luc and endoscopic antrostomy (Caldwell Luc a year after, no recurrence)	1.6 years, asymptomatic, NED
7	M	42	Immunocompetent	Left maxillary sinus	24	Mucoid discharge, nasal obstruction, headache.	Caldwell Luc, endoscopic antrostomy	1 year follow up, NED

Abbreviations: F, female; M, male; mo, months; NA, none available; NED, no evidence of disease.



**Fig. 1** Case 1. Chronic orbital mucormycosis. (A-D) Computed tomography scan shows intraorbital density, predominantly on the apex region. (E). Periodic acid-Schiff (PAS) stain showing mucormycosis with 90-degree non-septated hyphae.

### Immunocompetent

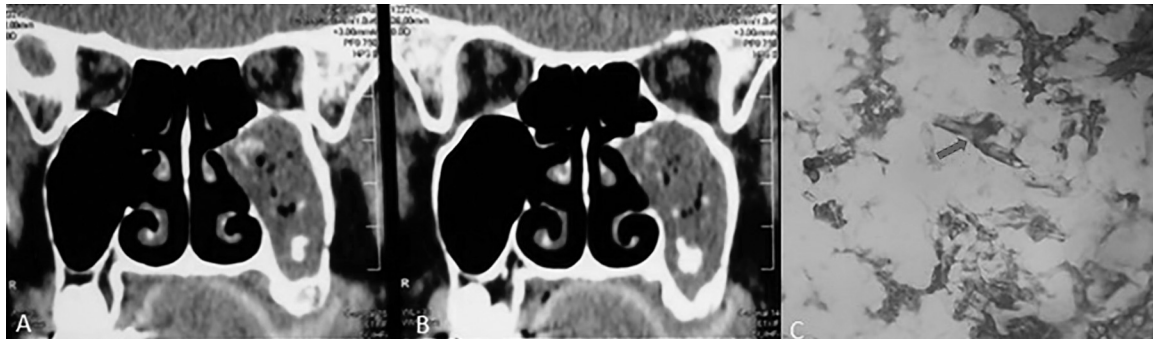Among the immunocompetent cases (5, 6, and 7), one patient had cocaine addiction, interrupted 5 years earlier and 2 patients had previous septoplasties.

Patient number 5 had right nasal polyp as the only cause of nasal symptoms. Mucormycosis was contralateral and

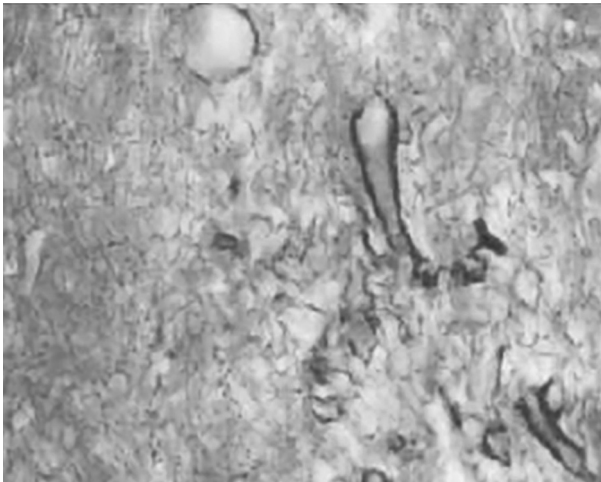
asymptomatic. See ►Figs. 5, 6 and 7. See ►Table 1 for complete description of symptoms and treatments.

### Treatment

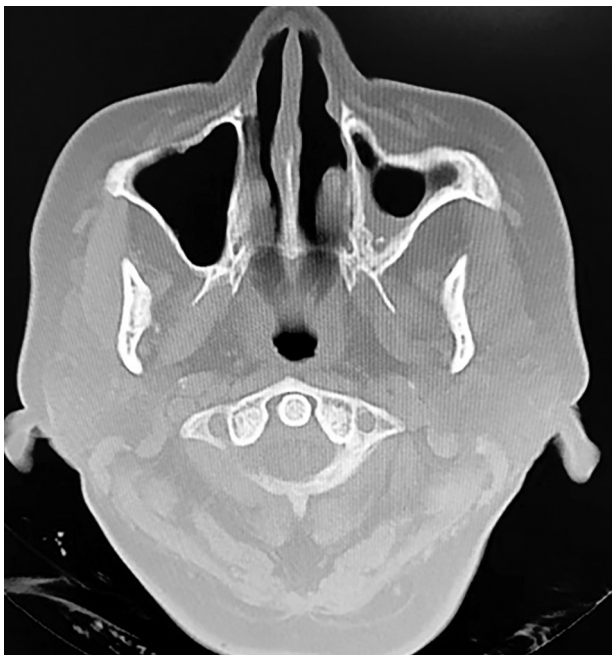All patients underwent surgical treatment, which consisted mainly in an external maxillary approach and endoscopic



**Fig. 2** Case 2. (A and B) Computed tomography scan shows left maxillary sinus with heterogeneous density and osteitis. (C) Hematoxylin eosin stain (100x) and (D) Periodic acid-Schaff stain (400x) demonstrate respiratory epithelium with thick hyphae; at higher magnification, non-septated hyphae with right angles are confirmed (red arrow).



**Fig. 3** Case 3. Pathology specimen shows edematous mucosa with lymphocyte and plasmatic cells infiltration. Abundant irregular hyphae were observed, with 15 to 30µm, broad with thin wall, non septated, with irregular ramifications filling blood vessels.



**Fig. 4** Case 4. Computed tomography scan showing osteitis of maxillary walls and occupation with heterogeneous density of left maxillary sinus.

antroostomy. Regarding medical treatment, one immunosuppressed subject received only amphotericin, and case one received both amphotericin and posaconazole. On the other hand, posaconazole was the only treatment in one immunosuppressed patient. (See ►Table 1)

All immunocompetent patients had unilateral maxillary sinus involvement and received only surgical treatment, with resolution of the disease. The surgical findings in these patients were similar: black and abundant debris in the maxillary sinus. Two immunocompetent patients had signs of necrosis in the maxillary mucosa. Interestingly, only case one had evident necrosis at nasal endoscopy.

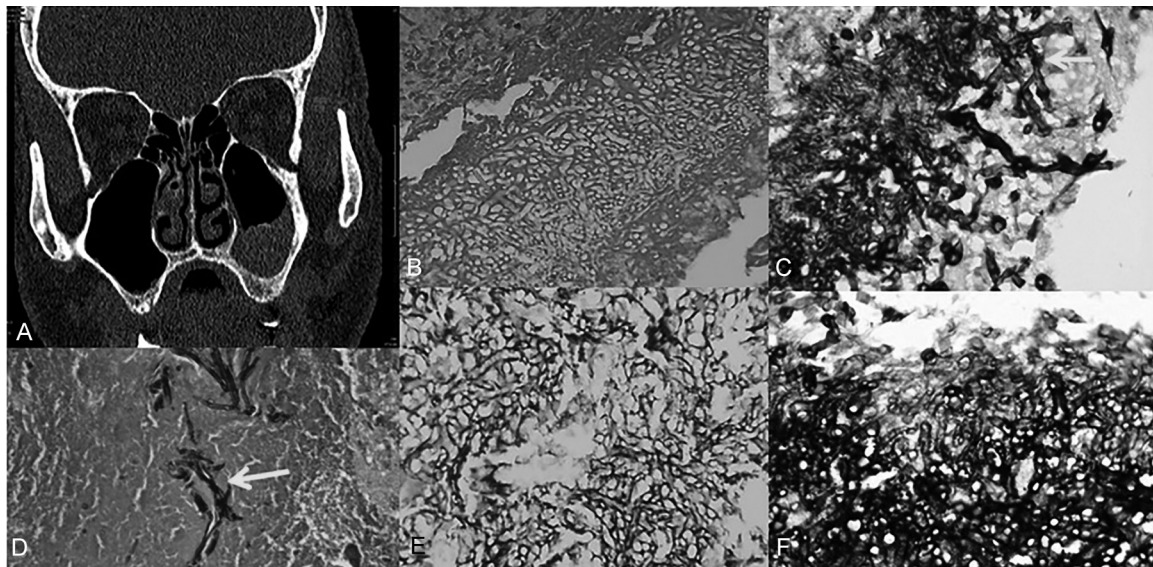
## Discussion

Mucormycosis refers to any fungal infection by members of the order mucorales, which is in the class zygomycetes. Most pathogenic species are members of the family mucoraceae.<sup>1,8</sup> It is currently known that mucormycosis affects mainly immunosuppressed individuals,<sup>16</sup> especially uncontrolled diabetic patients with acidosis. Deferoxamine therapy and trauma have also been described as risk factors.<sup>1,8,13,17</sup> Furthermore, immunocompetent individuals are also prone to this disease.<sup>18</sup> Unfortunately, the previous literature has mainly described the fulminant course of this disease.

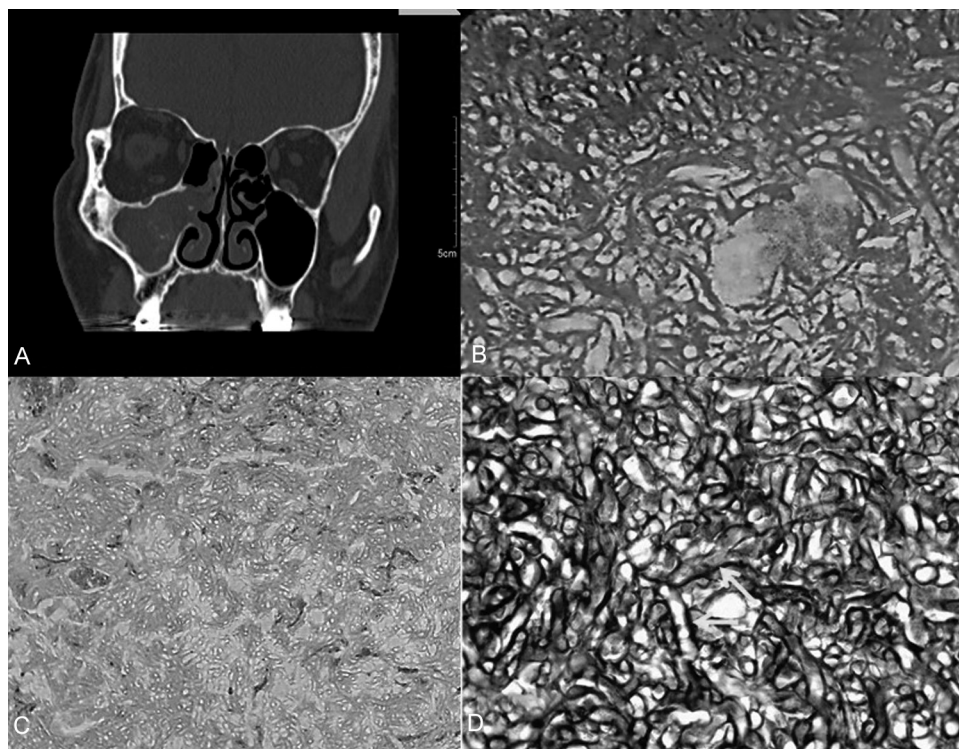
Chronic or indolent mucormycosis of the paranasal sinuses was described initially in 1964.<sup>19</sup> Although the disease is not universally known, over 30 cases have been described in the literature.<sup>15,20</sup> Interestingly, indolent mucormycosis can affect immunocompetent and immunosuppressed individuals. Although, immunocompetent cases are associated with a less severe disease.<sup>7</sup>

On the other hand, chronic invasive fungal sinusitis has generally been associated with the *aspergillus* species,<sup>10</sup> reinforcing the concept that mucormycosis develops only into an acute fulminant course. It is the objective of this paper to describe the chronic presentation of mucormycosis and to show our experience in the treatment of both immunocompetent and immunosuppressed patients.

The definition of chronic mucormycosis has been controversial, since some authors acknowledge a period of only weeks,<sup>9,21,22</sup> while others consider it necessary the presence of mucormycosis for at least 1 month.<sup>4</sup> All the patients



**Fig. 5** Case 5. (A) Computed tomography scan demonstrates left maxillary sinus occupation. (B) Periodic acid-Schaff stain (100x): necrotic tissue with mixed inflammatory cells and hyphae with diverse diameters non septated, with some showing 90-degrees angulation, compatible with mucor (red arrow). (C, D, E, F) Grocott Gomori stain (40x, 100x, 400x): abundant non-septated hyphae with 90-degree angulation; this stain was highly positive on hyphae walls.

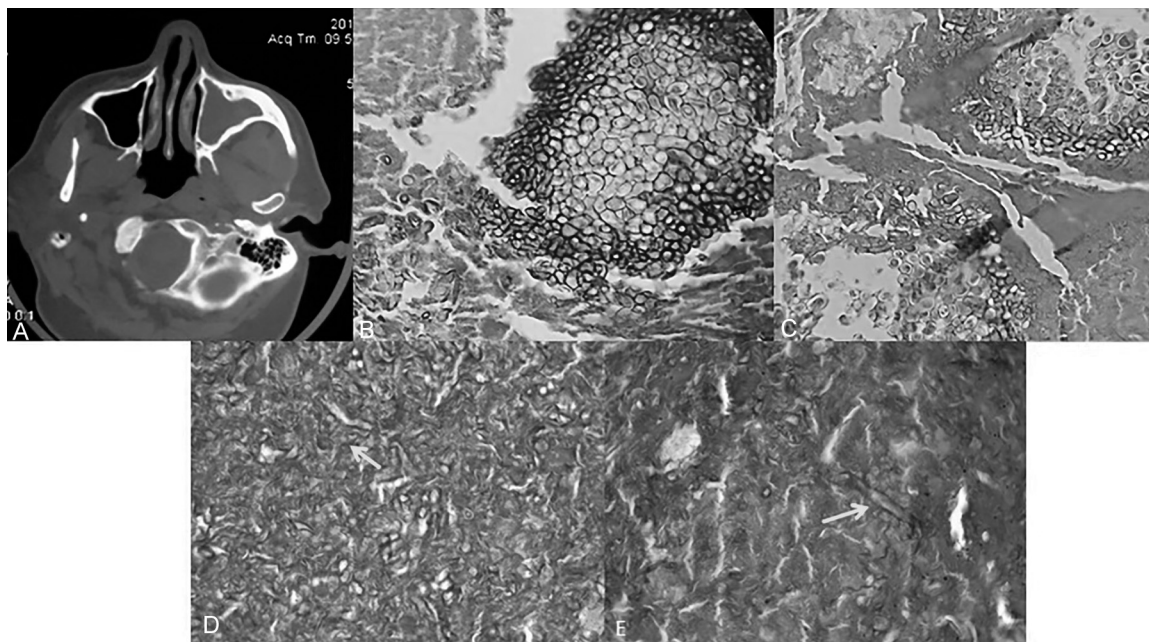


**Fig. 6** Case 6. (A) Computed tomography scan with total right maxillary sinus heterogeneous occupation. (B) Periodic acid-Schiff stain (400x) shows numerous thick hyphae semi-septated (yellow arrow) with 90-degrees angulation (red arrow) (C) Hematoxylin eosin stain (100x) shows abundant pauci-septated hyphae with right angles and necrosis. (D) Grocott Gomori stain (100X) shows abundant hyphae compatible with zygomycetes.

included in our study had at least 1 month of suggestive mucormycosis infection.

Also, chronic mucormycosis has been associated with internal carotid artery occlusion,<sup>9</sup> although none of our patients developed this complication. One common clinical

feature we could find in most of our patients was the presence of facial pain or headache. This could be a hallmark symptom when faced with a patient with chronic paranasal sinus disease with evident CT scan sinus occupation. Some authors<sup>5,23,24</sup> also describe this pain frequently in their



**Fig. 7** Case 7. (A) Computed tomography scan with left total maxillary sinus occupation. (B) Periodic acid-Schiff (PAS) stain (400x) showing spores and scant hyphae compatible with mucormycosis. (C) Hematoxylin eosin stain (400 x) showing inflammatory cells, spores and hyphae compatible with mucor. Figure D and E show non-septated hyphae on PAS stain (100x).

patients.<sup>6</sup> In our study, only one patient had orbital apex syndrome. This patient had middle turbinate necrosis, evident at nasal endoscopy. Necrosis was seen in most of our patients during modified Caldwell-Luc procedure in maxillary mucosa, but no evidence of necrosis was seen on rhinoscopy or nasal endoscopy. This defies the current knowledge that necrosis is usually seen at the physical exploration of these patients. In our study, maxillary sinus disease was the most common paranasal sinus involved, pointing to a more limited disease. Curiously, other authors have described a more aggressive course with orbital apex syndrome, cavernous sinus thrombosis<sup>4,21,22</sup> and brain abscess.<sup>25</sup> Although, on immunocompetent patients, the disease has been more localized.<sup>5,10,26</sup> Other authors have corroborated single paranasal sinus disease on immunocompetent patients.<sup>7,11,12,15,16</sup> See **Table 2** and **3** for a brief review of the literature.

The CT scan in some of these cases may not have the typical erosion of sinus wall. Mignogna et al and Ketenci et al did not find erosion in the CT scans of their patients, only sinus occupation. Erosion could not be considered a hallmark sign in chronic mucormycosis cases.

Among the immunosuppressed patients, case one began with a fulminant mucormycosis disease, only to progress to an indolent orbital course. During the patient's hospitalization, efforts for orbital preservation led to continued observation in an otherwise stable patient; nonetheless, orbital apex disease progression was seen on subsequent CT scans, with additional mucormycosis pathological confirmation ultimately leading to orbital exenteration. It is possible that treatment with amphotericin B lead in fact to an indolent course in case number 1. only amphotericine treatment on iniatilly invasive mucormycosis cases with no surgery could lead to an indolent course.

Careful imaging follow-up is necessary, especially in cases of orbital disease. Also, a chronic orbital case treated with a course of antifungals could erroneously lead a surgeon to do no further surgery, which, in fact, happened in this case, making it necessary first, an orbital biopsy and later, with this being positive, an exenteration. Mutilation of a patient (exenteration) is a difficult decision. This article recommends immediate orbital exenteration in case of progressive orbital disease, only evident on CT scan.

Since this is an infrequent disease, no randomized control trials are possible, and only case series are reported in the literature.<sup>15</sup> Therefore, there is controversy on the best treatment available for this pathology. Some authors advocate a surgical and amphotericin B treatment,<sup>4,7,27,28</sup> while others support only the surgical or medical treatment, such as monotherapy.<sup>11,12</sup> These patients, as many authors point out, have different comorbidities that contraindicate either the use of amphotericin or surgical treatment. Several case reports showed us that monotherapy is a viable treatment with good results.<sup>19,22</sup> Additionally, many authors describe a persistent disease with a very slow progression that has no impact on the quality of life of the patient.<sup>5,10,27,28</sup>

We agree with Tyson et al,<sup>5</sup> Seung et al<sup>7</sup> Jung H, et al<sup>11</sup> and Ketenci et al<sup>27</sup> that an only surgical treatment in immunocompetent patients is possible. Interestingly, there has been a rise in the reported cases of acute and chronic mucormycosis.<sup>1,2</sup> This could mean an increased interest in publishing these cases, more awareness of this disease with prompt diagnosis and treatment, or a real increment of mucormycosis cases due to more diabetic or immunosuppressed patients. A possible explanation to indolent mucormycosis in Mexico is the tropical weather and high temperature of this geographical area, which could increase the risk of fungal infection. Other

**Table 2** Current literature on indolent mucormycosis immunosuppressed patients

Publication Year	N	Sex	Age	DX	Max	Ethm	Sph	OAS	Other	Time (mo)	Clinical features	Surg sinus	EX	Ampho B	Follow-up
Ferstenfeld <sup>25</sup> (1977)	2	F M	61 36	DM DM	Y Y	Y Y	N N	N N	Y N	1 0.5	Case 1: Fever, Pain, nasal congestion, exophthalmos, ophthalmoplegia, loss of vision Case 2: Left temporal headache and maxillary ache. Swelling of the left side of face, protrusion left of the left eye.	Y Y	Y N	Y Y	Case 1: Recover of functional capacity. Case 2: Afebrile, right arm weakness and seizures.
Finn <sup>2</sup> (1982)	2	F M	82 58	RA DM/ Lymphoma	N Y	Y N	N N	N N	N N		Case 1: Periorbital edema, necrotic crust. Case 2: Proptosis, purulent nasal discharge	Y Y	N N	Y N	Case 1: 36 months. Nasal cavity remained clean Case 2: 12 months No recurrence of infection.
Dooley <sup>22</sup> (1992)	1	M	45	DM	N	Y	Y	Y	N	1.5	Orbital Apex Syndrome.	Y	N	Y	48 months. Improved ocular movement.
Harril <sup>21</sup> (1996)	2	F F	46 66	DM DM	Y N	Y N	Y Y	Y Y	N N	Case 1: 8 Case 2: 1.5	Case 1: Prosis Ophthalmoplegia, intranasal mass Case 2: Facial pain, ophthalmoplegia	Y Y	N N	Y Y	Case 1: NED, 21 Months Case 2: Died of unrelated cause
Ruoppi <sup>16</sup> (2001)	2	F M	62 72	Asthma DM	Y Y	N Y	N Y	N N	N N	Case 1: 0.6 Case 2: 0.1	Case 1: Facial pain, purulent discharge, swelling in the right upper gingiva and palate. Case 2: Facial pain, conjunctivitis, proptosis and chemosis of the conjunctiva	Y Y	N N	Y Y	Case 1: 38 months No fungal infection has occurred. Case 2: 37 months. No signs of recurrence.
Rumboldt <sup>18</sup> (2002)	1	M	16	Leukemia	N	N	Y	N	IC	3	Fever, headache, changes in the mental status	N	N	Y	3 months. Only biopsy. The lesion continued to grow, and the patient developed an infarction in the right middle cerebral artery.
Waizel Haiat <sup>6</sup> (2003)	1	M	55	DM	Y	Y	Y	Y	N	3	Left palpebral ptosis with increased volume, purulent anterior and posterior discharge.	Y	Y	Y	12 months. No signs of recurrence.
Bertin <sup>26</sup> (2003)	1	m	61	DM	Y	Y	N	N	N		Facial cellulite	N	N	Y	6 months. NED or recurrence.
Marin- Mendez <sup>4</sup> (2005)	2	M M	70 72	DM DM	Y Y	Y Y	Y Y	Y N	N N	1	Case 1: weakness, nasal obstruction, rhinorrhea, OAS Case 2: ptosis, nasal obstruction, rhinorrhea, OAS	Y Y	N Y	N Y	Case 1: Recovery of eye movement Case 2: Cavernous sinus thrombosis, deceased.
Odessey <sup>24</sup> (2008)	1	M	64	DM AR	Y	N	N	N	N	Several days	Frontal headache, right periorbital pain, diplopia, numbness and right facial weakness	Y	N	Y	None specified. Despite improvement in facial symmetry and ocular symptoms.
Kim <sup>7</sup> (2013)	1	F	56	DM	Y	N	N	N	N	Several months	Severe nasal obstruction with facial tenderness	Y	N	Y	19 months. No evidence of infection or recurrence
Teixeira <sup>3</sup> (2013)	1	F	46	DM	N	Y	N	Y	N	24	Right side periorbital and deficit of II, III, IV, V, VI and VII cranial nerves.	Y	Y	Y	9 years. Asymptomatic and without evidence of disease recurrence.
Jung <sup>1</sup> 2013	1	F	67	DM	Y	N	N	N	N	36	Foul odor, postnasal drip.	Y	N	N	10 months
Dimaka <sup>8</sup> (2014)	1	M	82	DM	Y	Y	Y	N	N	6	Purulent and odorous nasal discharge, epistaxis, anosmia	N	N	Y	42 months Still alive and relatively well.
Gutierrez-Delgado <sup>9</sup> (2016)	1	M	47	DM	Y	N	N	N	N	3	Paresthesia, pain and swelling in the left zygomatic bone	Y	N	Y	4 months. NED or recurrence

Abbreviations: Ampho B, amphotericin B; RA, rheumatoid arthritis; DM, diabetes mellitus; DX, diagnosis; Ethm, ethmoid sinus; EX, exenteration; F, female; M, male; Max, maxillary sinus; MCI, middle cerebral infarction; mo, months; N, none; NED, no evidence of disease; OAS, orbital apex syndrome; Sph, sphenoid sinus; Sinus surg, sinus surgery; Y, yes.

**Table 3** Current literature on indolent mucormycosis: immunological competent patients

Publication Year	n	Sex	Age	Prev DX	Max	Ethm	Sph	OAS	Other	Time (mo)	Clinical Features	Sinus surg	EX	Ampho B	Follow-up
Tyson <sup>5</sup> (1992)	1	F	26	No	Y	Y	N	N	N	48	Nasal obstruction, mucoid discharge, left facial pain and pressure	Y	N	Y	She has been free of disease for more than 36 months postoperatively
Del Valle <sup>28</sup> (1996)	1	M	54	No	N	N	Y	N	N	0.75 days before intervention.	Severe left temporal headache, the patient was healthy until this acute episode.	Y	N	Y	12 months. Examinations and biopsies have shown to be free of disease.
Ketenci <sup>27</sup> (2005)	1	F	63	No	N	N	Y	N	N	3	Severe headache	Y	N	N	6 months Biopsy and CT scan showed no recurrence.
Virik <sup>10</sup> (2007)	1	M	40	No	Y	Y	Y	N	N	24	Nasal obstruction, proptosis, diplopia.	Y	N	Y	Not specified Free of disease on regular endoscopic follow-up.
Mignogna (2011) <sup>15</sup>	5	M	67	RPC	Y	N	Y	N	N	0.5-1	Case 1: Chronic bilateral orofacial pain and fever	N	N	Y	6 months
		M	46	No	Y	N	N	N	N	0.5-1	Case 2: respiratory distress, fever	N	N	Y	24 months
		M	47	BPH	Y	N	N	N	N	0.5-1	Case 3: acute diplopia, orbital pain	N	N	Y	60 months
		M	54	No	Y	N	N	N	N	0.5-1	Case 4: rhinorrhea, facial pain	N	N	Y	14 months
		F	53	No	Y	N	N	N	Y Erosion of orbit	.5-1	Case 5: rhinorrhea, headache, orbital pain	N	N	Y	20 months
Jung <sup>11</sup> (2013)	4	F	67	No	Y	N	N	N	N	5	Case 1: Foul odor, postnasal drip, nasal stuffiness	Y	N	N	17 months
		M	60	No	Y	N	N	N	N	4	Case 2: Stuffiness, postnasal drip	Y	N	N	24 months
		F	68	No	Y	N	N	N	N	4	Case 3: Foul odor, postnasal drip, nasal stuffiness	Y	N	N	12 months
Jad <sup>12</sup> (2015)	1	F	34	No	Y	Y	Y	N	N	2	Headache, blockage of left nasal cavity, changes in voice. (similar event a year ago)	N	N	N	There was no recurrence in any patient. 3 months treatment with fluconazole. After 3 months, the CT scan was repeated and found to be normal.
Wolkow <sup>13</sup> (2017)	1	F	74	No	Y	Y	Y	Y	N	1	Fever, chills, left facial pain, and left periorbital erythema and edema.	Y	Y	Y	4 months Lesions recurred, accompanied by spontaneous drainage of purulent fluid.
Hemashettar <sup>14</sup> (2011)	1	M	18	No	N	N	N	N	Nose Facial skin	144	Ulcerative lesion on the nose and palate	N	N	N	Debridement and fluconazole. 6 months follow-up. The wound healed but later the patient was lost to follow-up.

Abbreviations: Ampho B, amphotericin B; BPH, benign prostatic hypertrophy; Ethm, ethmoid sinus; EX, exenteration; F, female, M, male; Max, maxillary sinus; mo, months; N, none; OAS, orbital apex syndrome; Prev DX, previous diagnosis; RPC, rhinopharyngeal cancer; Sph, sphenoid sinus; Sinus surg, sinus surgery; Y, yes.



authors have hypothesized that chronic sinusitis could be a risk factor for this fungal infection.<sup>15</sup>

In contrast to acute fulminant invasive sinusitis, chronic mucormycosis could have better survival. In a recent systematic review,<sup>20</sup> only half of the patients with acute fulminant disease survived, with diabetic patients having better prognosis than patients with other comorbidities. Chronic mucormycosis, at least in our series, had a 100% survival rate. Other authors support this improvement in survival, especially in immunocompetent patients.<sup>5,10,11,24,27</sup>

Differential diagnosis of this disease should be kept in mind, such as neoplasms, bacterial sinusitis, granulomatous disorders, cavernous sinus thrombosis, pseudotumors, etc.<sup>9</sup>

The limitations of this study are mainly the lack of mucormycosis cultures. Nonetheless, the characteristic broad non-septated hyphae with right angle branching usually suffices for diagnosis. Since this is an emerging entity, we are confident that new studies could confirm our results and shed new light on this disease.

The strengths of this study are the high number of patients included, in contrast to what has been previously published, the longer follow-up and the fact that it is a multicenter study.

Finally, indolent mucormycosis is a differential diagnosis in patients with facial pain or headache, mucoid discharge, cacostia with a paranasal sinus occupation on CT scan in immunosuppressed and immunocompetent individuals.

## Conclusion

Indolent mucormycosis is a new and emerging clinical entity in immunosuppressed and immunocompetent patients. Single paranasal sinus disease is a frequent presentation and should not be overlooked as a differential diagnosis in these patients. Immunocompetent patients should only be treated surgically. More studies are needed to confirm our results.

## References

- Ibrahim AS, Kontoyiannis DP. Update on mucormycosis pathogenesis. *Curr Opin Infect Dis* 2013;26(06):508–515
- Finn DG, Farmer JC Jr. Chronic mucormycosis. *Laryngoscope* 1982; 92(7 Pt 1):761–766
- Teixeira CA, Medeiros PB, Leushner P, Almeida F. Rhinocerebral mucormycosis: literature review apropos of a rare entity. *BJM Case Rep* 2013. Doi: 10.1136/bcr-2013-008552 <https://www.ncbi.nlm.nih.gov/pubmed/23389725>
- Marin-Mendez H, Monroy-Aguirre D, Rodríguez-Perales M, Caretta-Barradas Sergio. Síndrome de ápex orbitario causado por mucormicosis orbito cerebral crónica e indolente: reporte de dos casos. *An Orl Mex* 2005;50:64–68
- Tyson JC, Gittelman PD, Jacobs JB, Holliday R, Press R. Recurrent mucormycosis of the paranasal sinuses in an immunologically competent host. *Otolaryngol Head Neck Surg* 1992;107(01):115–119
- Waizel-Haiat S, Cohn-Zurita F, Vargas-Aguayo AM, Ramírez-Aceves R, Vivar-Acevedo E. Mucormicosis rinocerebral invasora crónica. *Cir Cir* 2003;71(02):145–149
- Kim ST, Kim WS, Lee HH, Kim JY. Successful treatment of invasive rhinopulmonary mucormycosis with an indolent presentation by combined medical and surgical therapy. *J Craniofac Surg* 2013;24(02):e182–e184
- Dimaka K, Mallis A, Naxakis SS, et al. Chronic rhinocerebral mucormycosis: a rare case report and review of the literature. *Mycoses* 2014;57(11):699–702
- Gutiérrez-Delgado EM, Treviño-González JL, Montemayor-Alatorre A, et al. Chronic rhino-orbito-cerebral mucormycosis: A case report and review of the literature. *Ann Med Surg (Lond)* 2016;6:87–91
- Virk RS, Arora P. Chronic sinonasal aspergillosis with associated mucormycosis. *Ear Nose Throat J* 2007;86(01):22
- Jung H, Park SK. Indolent mucormycosis of the paranasal sinus in immunocompetent patients: are antifungal drugs needed? *J Laryngol Otol* 2013;127(09):872–875
- Jad B, Pottathil S, Raina S, Singh V. Paranasal Sinus Mucormycosis in an Immunocompetent Host: A Case Report. *Int J Health Sci Res* 2015;5:617–620
- Wolkow N, Jakobiec FA, Stagner AM, et al. Chronic orbital and calvarial fungal infection with *Apophysomyces variabilis* in an immunocompetent patient. *Surv Ophthalmol* 2017;62(01):70–82
- Hemashettar BM, Patil RN, O'Donnell K, Chaturvedi V, Ren P, Padhye AA. Chronic rhinofacial mucormycosis caused by *Mucor irregularis* (*Rhizomucor variabilis*) in India. *J Clin Microbiol* 2011; 49(06):2372–2375
- Mignogna MD, Fortuna G, Leuci S, et al. Mucormycosis in immunocompetent patients: a case-series of patients with maxillary sinus involvement and a critical review of the literature. *Int J Infect Dis* 2011;15(08):e533–e540
- Ruoppi P, Dietz A, Nikanne E, Seppä J, Markkanen H, Nuutinen J. Paranasal sinus mucormycosis: a report of two cases. *Acta Otolaryngol* 2001;121(08):948–952
- Sun HY, Singh N. Mucormycosis: its contemporary face and management strategies. *Lancet Infect Dis* 2011;11(04):301–311
- Rumboldt Z, Castillo M. Indolent intracranial mucormycosis: case report. *AJNR Am J Neuroradiol* 2002;23(06):932–934
- Vignale R, Mackinnon JE, Casella de Vilaboa E, Burgoa F. Chronic, destructive, mucocutaneous phycomycosis in man. *Sabouraudia* 1964;3(02):143–147
- Turner JH, Soudry E, Nayak JV, Hwang PH. Survival outcomes in acute invasive fungal sinusitis: a systematic review and quantitative synthesis of published evidence. *Laryngoscope* 2013;123(05):1112–1118
- Harril WC, Stewart MG, Lee AG, Cernoch P. Chronic rhinocerebral mucormycosis. *Laryngoscope* 1996;106(10):1292–1297
- Dooley DP, Hollsten DA, Grimes SR, Moss J Jr. Indolent orbital apex syndrome caused by occult mucormycosis. *J Clin Neuroophthalmol* 1992;12(04):245–249
- Rao SP, Kumar KR, Rokade VR, Khanna V, Pal C. Orbital Apex Syndrome due to mucormycosis caused by *Rhizopus microsporum*. *Indian J Otolaryngol Head Neck Surg* 2006;58(01):84–87
- Odessey E, Cohn A, Beaman K, Schechter L. Invasive mucormycosis of the maxillary sinus: extensive destruction with an indolent presentation. *Surg Infect (Larchmt)* 2008;9(01):91–98
- Ferstenfeld JE, Cohen SH, Rose HD, Rytel MW. Chronic rhinocerebral phycomycosis in association with diabetes. *Postgrad Med J* 1977;53(620):337–342
- Bertin H. Mucormicosis rinosinusal. *Rev Otorrinolaringol Cir Cabeza Cuello* 2003;63:122–126
- Ketenci I, Unlü Y, Sentürk M, Tuncer E. Indolent mucormycosis of the sphenoid sinus. *Otolaryngol Head Neck Surg* 2005;132(02): 341–342
- Del Valle Zapico A, Rubio Suárez A, Mellado Encinas P, Morales Angulo C, Cabrera Pozuelo E. Mucormycosis of the sphenoid sinus in an otherwise healthy patient. Case report and literature review. *J Laryngol Otol* 1996;110(05):471–473