

# Adenomatous Tumors of the Middle Ear: A Literature Review

Flavia Amarante Cardoso<sup>1</sup> Eduardo Machado Rossi Monteiro<sup>1</sup> Livia Bernardi Lopes<sup>1</sup>  
Marianna Novaes da Costa Avila<sup>1</sup> Bernardo Oliveira Scarioli<sup>1</sup>

<sup>1</sup>Department of Otorhinolaryngology, Hospital Felício Rocho, Belo Horizonte, Brazil

**Address for correspondence** Flavia Amarante Cardoso, Department of Otorhinolaryngology, Hospital Felício Rocho, Avenida do Contorno, 9530, Belo Horizonte 30110130, Brazil (e-mail: flaviamarante@gmail.com).

Int Arch Otorhinolaryngol 2017;21:308–312.

## Abstract

**Introduction** Neuroendocrine adenomas of the middle ear (NAME) are uncommon causes of middle ear masses. Mostly limited to case reports and small series, the literature is poor in providing an overall assessment of these tumors.

**Objective** To review the current literature about all aspects of the disease, including its etiology, clinical manifestations, diagnosis, and treatment.

**Data Synthesis** The pathogenesis of adenomatous tumors of the middle ear is not clear yet. One potential explanation is that an undifferentiated pluripotent endodermal stem cell may still be present in the middle ear mucosal surface, and may be the origin of the tumors. It typically appears as a nonspecific retrotymppanic mass. The average age of onset for the disease is the fifth decade, and the most common clinical symptom is conductive hearing loss. Malign behavior is rare. There are numerous differential diagnoses of NAME. The final diagnosis depends on microscopic findings. The preoperative evaluation should include the use of computed tomography and magnetic resonance imaging. The adjunctive therapy of middle ear adenomatous tumors with radiotherapy, chemotherapy or somatostatin analogs is generally not recommended.

**Conclusion** There is still much debate on pathogenesis and classification of NAME. Saliba's classification is currently the most complete and preferable one. Aggressive surgical procedure with ossicular chain excision is the gold standard treatment. Follow-up with physical and radiological exams is mandatory, particularly if the first procedure was conservative, without the removal of the encased ossicles.

## Keywords

- ▶ middle ear
- ▶ adenoma
- ▶ neuroendocrine tumors

## Introduction

Adenomatous middle ear tumors are uncommon causes of middle ear masses. First described by Hyams and Michaels<sup>1</sup> in 1976, and afterwards by Murphy<sup>2</sup> in 1980, they still challenge pathologists and otolaryngologists in terms of their similarities to other rare pathologies, their etiologies, classification and prognosis.<sup>3</sup> Mostly limited to case reports and small series, the literature is poor in providing an overall assessment of these tumors. Some researchers insist that adenoma of the middle ear and carcinoid tumors are distinct

biological neoplasms with similar characteristics; however, recent histopathologic evidence suggests that such labels can represent a spectrum of a common pathological entity.<sup>4</sup> Therefore, it has been commonly assumed that the different names given to these lesions, including ceruminous adenoma, monomorphic adenoma, adenocarcinoma, and carcinoid tumors, may actually represent a spectrum of the same pathology with different degrees of neuroendocrine differentiation. Many of these terms were applied incorrectly, and currently there is a tendency to unify these lesions under the name *neuroendocrine adenoma of the middle ear* (NAME).<sup>5</sup>

received  
October 3, 2016  
accepted  
January 22, 2017  
published online  
April 28, 2017

DOI <https://doi.org/10.1055/s-0037-1601400>  
ISSN 1809-9777.

Copyright © 2017 by Thieme Revinter Publicações Ltda, Rio de Janeiro, Brazil

License terms



Due to the rarity of middle ear tumors, adenomatous aggregate the controversies in the classification and biological behavioral differences, and protocols for the management of these tumors are scarce. Therefore, the aim of this study was to review the current literature about all aspects of the disease, including its etiology, clinical manifestations, diagnosis, and treatment.

## Review

### Etiology

The pathogenesis of adenomatous tumors of the middle ear is not clear yet. Just as in the lung, the middle ear mucosa is derived from the endoderm; however, skin cells with neuroendocrine features are not observed in the ear cavity. The middle ear does not contain enterochromaffin cells either, which normally lead to carcinoid tumors in the lung and gastrointestinal tract, and, therefore, it is not possible to identify the progenitor cell of the neuroendocrine carcinoid tumors, as in the lung. One potential explanation is that an undifferentiated pluripotent endodermal stem cell may still be present in the middle ear mucosal surface, and may be the origin of the tumors.<sup>4</sup> The lack of evidence for epithelial junction surface leads to another consideration: a precursor of the stroma (neural crest). This theory is based on the fact that glomus cells derived from the neural crest normally present neuroendocrine features and absence of epithelial structure and exocrine characteristics. In either event, a metaplastic alteration would be required within the resident cells of the middle ear to account for the dual population noted within these tumors.<sup>4</sup>

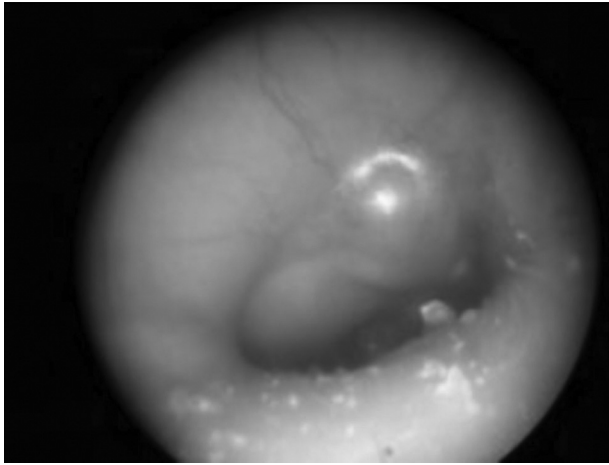
The advanced theory proposed by Thompson and Torske, who stated that a pluripotent undifferentiated stem cell can give rise to an adenomatous tumor of the middle ear, can explain both the epithelial and neuroendocrine tumor components. Thus, recent studies have used pathological features suggesting that adenoma and carcinoid of the middle ear may represent different stages of the same disease, and tend to classify these tumors based on immunohistochemical markers and on the presence or absence of metastasis.<sup>6</sup> Both tumors are positive for a variety of markers, including: the cytokeratin cocktail and vimentin immunostaining; and neuroendocrine markers, such as neuron-specific enolase (NSE), chromogranin, and uniform distribution of synaptophysin.<sup>6</sup> In one study, human pancreatic polypeptide was almost uniformly positive, and a variable positivity was observed for S-100, serotonin, glucagon, Leu-7, adrenocorticotropic hormone and somatostatin in both the adenoma and the carcinoid of the middle ear.<sup>4</sup> The current classification says that the most common neoplasm (type I) is the neuroendocrine adenoma of the middle ear, which shows positive immunohistochemistry and negative metastasis. A type II tumor is the middle ear adenoma, which shows negative immunohistochemistry and negative metastasis. The least common type (type III) within this classification scheme is the carcinoid tumor of the middle ear, which shows positive immunohistochemistry and positive metastasis and/or carcinoid syndrome.<sup>7</sup>

### Clinical Presentation

The middle ear adenoma typically appears as a nonspecific retrotympanic mass. The average age of onset for the disease is the fifth decade (14–80 years),<sup>8</sup> and there seems to be no difference between sexes.<sup>7</sup> The most common clinical symptom is conductive hearing loss.<sup>4</sup> Other symptoms reported include ear fullness, tinnitus, ear pain, otorrhea and facial weakness.<sup>7</sup> Facial nerve palsies were thought to be related to anatomic abnormalities, or local pressure from the tumor with facial canal bone dehiscence,<sup>4</sup> and facial nerve invasion has been described in one case of middle ear carcinoid<sup>9</sup> and presumed in another case. Otoscopy usually reveals a gray-white or fibrotic mass behind an intact tympanic membrane (–Fig. 1). There is only one reported case of systemic symptoms caused by a middle ear tumor, including diarrhea, abdominal cramps, skin flushing, and bronchoconstriction. Regarding regional symptoms, there was one reported case of middle ear carcinoid metastases to ipsilateral cervical lymph nodes.<sup>10</sup>

### Diagnosis

There are numerous differential diagnoses of NAME, including chronic otitis media, cholesteatoma, mucosal adenoma, ceruminous adenoma, carcinoid, paraganglioma, adenoid cystic carcinoma, pleomorphic adenoma, meningioma and schwannoma. Tomazic et al report a case of a NAME mimicking as chronic otitis media with an episode of facial nerve palsy. In this case, the patients presented hearing loss as the prevailing symptom, accompanied by other symptoms, such as tinnitus, equilibrium changes, fullness, otorrhea and pain. Therefore, especially when dealing with cases of chronic otitis media that does not respond to conservative therapy with episodes of facial nerve palsy, this entity should be considered in differential diagnosis.<sup>11</sup> The preoperative evaluation should include the use of computed tomography (CT) and magnetic resonance imaging (MRI) to evaluate tumor characteristics.<sup>6</sup> The CT highlights a nonspecific opacity, with possible extension to the middle ear and the mastoid, and the ossicular chain is usually embedded into the mass, but without bony erosion. Magnetic resonance imaging may be useful in cases extending to the posterior fossa (–Fig. 2). In MRI, tumors are isointense to hyperintense, and relative to white matter in the T1-weighted images, being highlighted with the administration of gadolinium. In the T2-weighted images, the tumors are approaching the intensity of the gray matter signal. One of the differential diagnoses of adenomatous middle ear tumors is paraganglioma, and to help discriminate between the disorders, some clinical and radiological findings were presented. Although both middle ear adenomas and glomus tympanicum appear as tissue lesions on the CT and the MRI, only glomus tumors have specific clinical features, such as pulsatile tinnitus, a close relationship between the tumor and Jacobson's nerve or its branches, and flushing vascular angiography. In contrast, adenomatous tumors of the middle ear are clearly separated from Jacobson's nerve and its branches, and although they show highlighted contrast, they have expressionless angiographic findings. The evaluation of patients with suspected

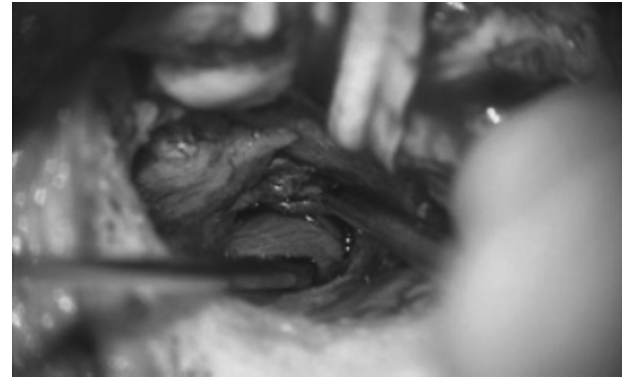


**Fig. 1** Otomicroscopy of a right ear shows a middle ear mass medial to an intact tympanic membrane (courtesy of Thomas E. Linder, Kantonsspital Luzern, Luzern, Switzerland).

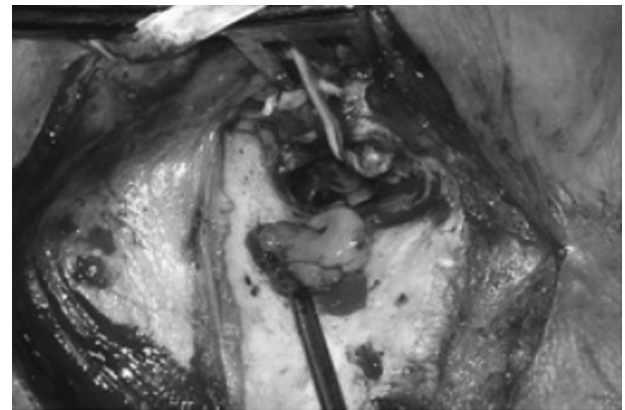
metastases (cervical mass, systemic symptoms) should include images of the neck, chest and abdomen. Researchers concluded that the octreotide scan is a sensitive method for monitoring through in cases of both recurrence of carcinoid ears and metastases, but there is no evidence for its use in the preoperative diagnosis and evaluation of these tumors.<sup>12</sup> Immunohistochemical staining can be a useful tool in differentiating adenomatous middle ear tumors from other neuroendocrine tumors, such as paraganglioma. The absence of S-100 protein positivity, combined with a strong positive staining for keratin, strongly argues against a diagnosis of paraganglioma. Immunostaining for galanin may also be useful, because carcinoid tumors have proved to be galanin negative, whereas some paragangliomas have been found to be galanin positive.<sup>13,14</sup>

**Treatment**

The treatment of choice for middle ear adenomatous tumors is surgical (► **Fig. 3**), with the surgical approach performed in

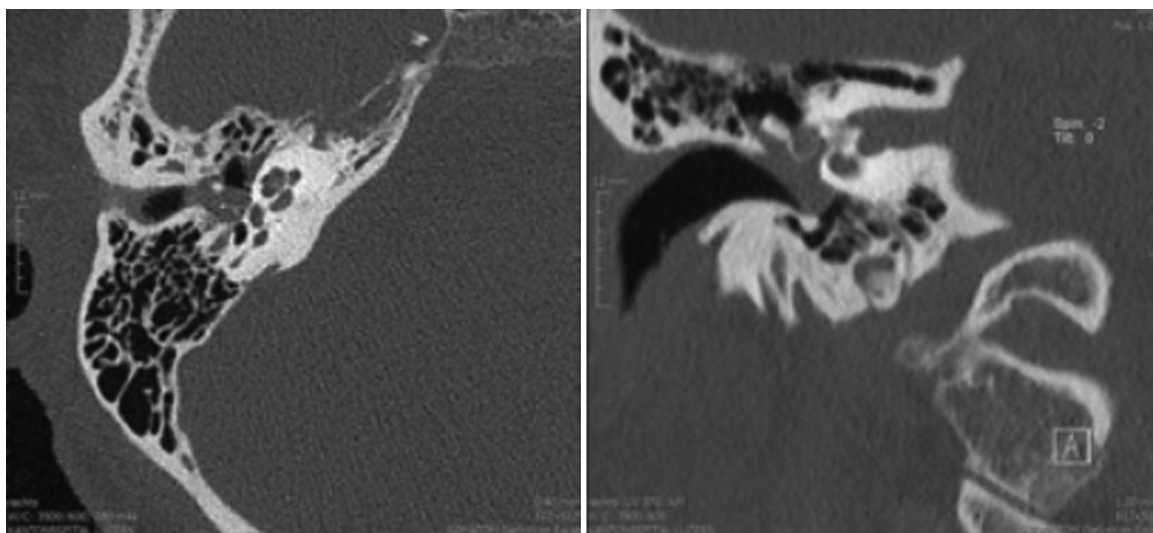


**Fig. 3** Middle ear tumor (courtesy of Thomas E. Linder, Kantonsspital Luzern, Luzern, Switzerland).



**Fig. 4** Tumor removed from middle ear (courtesy of Thomas E. Linder, Kantonsspital Luzern, Luzern, Switzerland).

accordance with the extent of the disease.<sup>2</sup> A transcanal approach can be used for small tumors limited to the mesotympanum, or tumors that extend through the tympanic membrane into the outer ear canal (► **Fig. 4**). Access to larger tumors, extending to the epitympanum and/or the



**Fig. 2** Axial (A) e (B) CT images of a middle ear adenoma, showing a nonspecific middle ear mass with ossicular chain involvement (courtesy of Thomas E. Linder, Kantonsspital Luzern, Luzern, Switzerland).

mastoid, can be accomplished with a tympanoplasty and intact canal wall mastoidectomy. The incidence of recurrence is higher with transcanal tympanoplasty (14%) than with a radical mastoidectomy (9%)<sup>7</sup>, but this is insufficient evidence to suggest the superiority of one procedure over the other.

As ossicular involvement is common, the ossicles are usually removed, and ossicular reconstruction should be performed. The adjunctive therapy of middle ear adenomatous tumors with radiotherapy, chemotherapy or somatostatin analogs is generally not recommended.<sup>7</sup>

## Discussion

Neoplasms of the middle ear are rare entities. Middle ear adenomas account for less than 2% of all ear tumors. Hyams and Michael<sup>1</sup> were the first to describe these tumors in 1976. They were named as middle ear adenomas, and their possible origin was the mucosal epithelium of the middle ear. In 1980, Murphy<sup>2</sup> described a similar tumor, but felt it was better characterized as a carcinoid tumor because of the ultrastructural evidence of a neuroendocrine differentiation. Until now, there is much debate in the literature as to the true nature of these neoplasms. The actual consensus is that they represent the same tumor with different degrees of glandular and neuroendocrine differentiation,<sup>4</sup> and there is a tendency to unify these lesions under the name *neuroendocrine adenoma of the middle ear* (NAME).<sup>5</sup>

The most common symptom is hearing loss, though aural fullness, tinnitus and otalgia, as well as asymptomatic patients, have also been described. Some tumors were discovered incidentally during routine physical examinations or diagnostic radiographic studies performed for non-related reasons.<sup>4</sup>

In the majority of the reported cases, the tympanic membrane is intact and displaced laterally by a retrotympanic mass that can be reddish, grayish or yellowish. The tumor is grossly vascularized, well circumscribed and unencapsulated. It tends to surround the ossicles, but without bony erosion. Facial palsy is uncommon, and it is generally resolved after the tumor resection, which suggests compression of the tympanic portion of the nerve rather than frank invasion, which has also been demonstrated, but is rare.<sup>9</sup> Paraneoplastic syndrome has been reported once.<sup>15</sup> Metastases reports are rare and controversial. The described metastases were all regional, occurred late to very late, and often after multiple recurrences.<sup>16</sup> The lack of systemic changes and documented metastases associated with these tumors may be more a function of their relatively small size and poor vascularization than a lack of biologic potential.

Radiologic images are nonspecific. Computed tomography images highlight homogenous, hypodense and well limited lesions of the temporal bone, which are able to extend to the entire tympanic cavity and the mastoid bone. Ossicles are generally embedded into the mass without apparent erosion. There are no characteristic differences between the benign or malignant variants of NAME. Magnetic resonance imaging does not provide preoperative information in addition to the information generated by a CT. The tumors are isointense in

T1-weighted images, and approximate the signal intensity of gray matter in T2-weighted images.

As the clinical signs, physical examination and image findings are unspecific, the final diagnosis is made by histology and immunohistochemistry. Neuroendocrine adenomas of the middle ear are composed of exocrine and neuroendocrine cells, sometimes with neuroendocrine markers such as NSE, chromogranin, synaptophysin, serotonin and pancreatic polypeptide.

The predominant architectural pattern is described as cuboidal to columnar, uniform in size, with eosinophilic, fine granular cytoplasm. The nuclei are round to oval, with finely dispersed chromatin, which often shows a “salt and pepper” pattern consistent with a neuroendocrine origin.

The classification for NAME proposed by Saliba and Evrard is based on immunohistochemistry findings and metastasis. This is currently the most used classification for middle ear glandular neoplasms (► **Table 1**).

Complete surgical removal is the treatment of choice. Excision of the ossicular chain, when encased by the tumor, has shown a better long-term result, as compared with 18–22% rate of recurrence in those patients in whom removal of the ossicles was not performed. The incidence of recurrence is higher with transcanal tympanotomy (14%) than with a radical mastoidectomy (9%)<sup>7</sup>, although there is yet no sufficient evidence to suggest the superiority of one procedure over the other. Repeated debulking-excision procedures are also an option to preserve the ossicular chain, but this technique requires continued long-term follow-up and patient compliance. When reconstruction of the tympanic membrane is required, one should prefer fascia over cartilage reconstruction to facilitate post-operative middle ear examinations.<sup>17</sup>

Chemotherapy and radiotherapy have been used for pulmonary and gastrointestinal carcinoid tumors, but there is no data for the treatment of middle ear carcinoid. Furthermore, there are descriptions of secondary malignant transformations due to radiation exposure.<sup>4</sup>

Local recurrence rates as high as 18% have been reported; therefore, a new surgical procedure is required. All recurrences developed when the ossicular chain was not removed during the first operation. Regional metastasis, when present, should be managed surgically with a parotidectomy or neck dissection.

Reports of disease free intervals vary from 53 to 158 months. Regular long-term follow-up with otoscopy and audiometry is recommended. Special attention should be given when the ossicular chain was not excised. In these

**Table 1** Saliba's Classification of middle ear glandular neoplasms

Type	Immuno-histochemistry	Metastasis	Percentage (%)
NEAME	+	–	76
MEA	–	–	20
CTME	+	+	4

Abbreviations: CTME, carcinoid tumor of the middle ear; MEA, middle ear adenoma; NEAME, neuroendocrine adenoma of the middle ear.

Note: Adapted from Saliba and Evrard, 2009.<sup>7</sup>

cases, systematic CT or MRI examinations should be made to detect recurrence early.

## Final Comments

Middle ear glandular neoplasms are uncommon. Malign behavior, such as carcinoid syndrome and metastasis, is rare. The final diagnosis depends on microscopic findings. There is still much debate on their pathogenesis and classification. Saliba's classification is currently the most complete and preferable one. The treatment of choice is an aggressive surgical procedure with ossicular chain excision. Follow-up with physical and radiological exams is mandatory, particularly if the first procedure was conservative, without removal of the encased ossicles. Chemotherapy and radiotherapy are not recommended.

## References

- Hyams VJ, Michaels L. Benign adenomatous neoplasm (adenoma) of the middle ear. *Clin Otolaryngol Allied Sci* 1976;1(01):17-26
- Murphy GF, Pilch BZ, Dickersin GR, Goodman ML, Nadol JB Jr. Carcinoid tumor of the middle ear. *Am J Clin Pathol* 1980;73(06):816-823
- Almuhanna K. Neuroendocrine adenoma of the middle ear with the history of otitis media and carcinoma of the cheek: a case report. *BMC Res Notes* 2014;7:532
- Torske KR, Thompson LDR. Adenoma versus carcinoid tumor of the middle ear: a study of 48 cases and review of the literature. *Mod Pathol* 2002;15(05):543-555
- Lott Limbach AA, Hoschar AP, Thompson LD, Stelow EB, Chute DJ. Middle ear adenomas stain for two cell populations and lack myoepithelial cell differentiation. *Head Neck Pathol* 2012;6(03):345-353
- Pelosi S, Koss S. Adenomatous tumors of the middle ear. *Otolaryngol Clin North Am* 2015;48(02):305-315
- Saliba I, Evrard AS. Middle ear glandular neoplasms: adenoma, carcinoma or adenoma with neuroendocrine differentiation: a case series. *Cases J* 2009;2(6508):6508
- Ayache S, Braccini F, Fernandes M, Homassin JM. Adenoma of the middle ear: a rare and misleading lesion. *Otol Neurotol* 2002;23(06):988-991
- Ramsey MJ, Nadol JB Jr, Pilch BZ, McKenna MJ. Carcinoid tumor of the middle ear: clinical features, recurrences, and metastases. *Laryngoscope* 2005;115(09):1660-1666
- Mooney EE, Dodd LG, Oury TD, Burchette JL, Layfield LJ, Scher RL. Middle ear carcinoid: an indolent tumor with metastatic potential. *Head Neck* 1999;21(01):72-77
- Tomazic PV, Beham A, Lackner A, Ropposch T, Stockreiter U, Walch C. Neuroendocrine adenoma of the middle ear (NAME) mimicking as chronic otitis media with an episode of facial nerve palsy. *B-ENT* 2011;7(02):121-125
- Nikanne E, Kantola O, Parviainen T. [Carcinoid tumor of middle ear]. *Duodecim* 2003;119(11):1081-1084
- Ferlito A, Devaney KO, Rinaldo A. Neuroendocrine neoplasms of the larynx: advances in identification, understanding, and management. *Oral Oncol* 2006;42(08):770-788
- Cruz Toro P, Domenech I, Clemente I, et al. Temporal bone histopathology case of the month neuroendocrine adenoma of the middle ear. *Otol Neurotol* 2011;33:7-8
- Isenring D, Pezier TF, Vrugt B, Huber AM. Middle ear adenoma: case report and discussion. *Case Rep Otolaryngol* 2014;2014(342125):342125
- Godelieve WJA, Engen-van Grunsven IACH, van der Schans EJ, Kunst HPM, et al. Temporal Bone Histopathology Case of the Month: A White Mass Behind the Tympanic Membrane: Adenoma of the Middle Ear with Neuroendocrine Differentiation. *Otol Neurotol* 2011;32:38-39
- Gut SM, Wagner B, Kessler M, Linder T. [Neuroendocrine adenoma of the middle ear]. *HNO* 2014;62(03):180, 182-185