

Premalignant Laryngeal Lesions: Twenty-Year Experience in Specialized Service

Daniel D. Avila¹ Jeferson D'Ávila² Carlos Góis² Luíza Barretto³

¹ENT Discipline, Faculdade de Medicina, Universidade de São Paulo, São Paulo, SP, Brazil

²DME, Universidade Federal de Sergipe, Aracaju, SE, Brazil

³Department of Otorrinolaryngology, Otocenter, Aracaju, SE, Brazil

Address for correspondence Daniel D. Avila, Resident Doctor, ENT Discipline, Faculdade de Medicina, Universidade de São Paulo. Rua Arruda Alvim, 49, 114, São Paulo 05410-020, Brazil (e-mail: danielvdavila@gmail.com).

Int Arch Otorhinolaryngol 2014;18:352–356.

Abstract

Introduction Premalignant lesions are considered both a hyperplastic and dysplastic stage of epithelial lesions in the glottic larynx that may or may not progress into an invasive carcinoma. The evolution of laryngoscopic procedures in outpatients has provided better access to important information for safe and easy diagnosis of laryngeal pathologies.

Objective The goal of this study was to determine the accuracy of the preoperative exam for diagnosis of premalignant laryngeal lesions and their connection with benign diseases of the vocal folds, as well as to assess their epidemiologic characteristics.

Methods This is a retrospective and longitudinal cohort study performed through the review of surgical records of patients who underwent laryngeal microsurgery performed by a single surgeon from 1990 to 2009.

Results Preoperative assessment of outpatients was 64.4% accurate. Vocal fold cysts were the most frequently associated benign lesions. The patients who apparently had premalignant lesions represented 10.57% of those who underwent laryngeal microsurgery. Premalignant lesions prevailed in men (69.49%) age from 41 to 50 years (32.20%).

Conclusion Although the evolution of laryngoscopic procedures in outpatients has provided better access to important information for safe and easy diagnosis of laryngeal pathologies, about one-third of premalignant lesions are diagnosed just during the laryngeal microsurgery. Cysts were the most prevalent concomitant benign lesion of the vocal folds. Males were more prevalent than females and the predominant age bracket was between 41 and 50 years.

Keywords

- ▶ larynx
- ▶ laryngeal neoplasms
- ▶ leukoplakia

Introduction

Premalignant laryngeal lesions are also known as precancerous lesions, preneoplastic lesions, squamous intraepithelial lesions, hyperplastic epithelial lesions, among others. By definition, a premalignant lesion is considered in a hyperplastic and dysplastic stage (keratinization) of epithelial lesions in the glottic region that may or may not develop into an invasive carcinoma.¹ In clinical practice, they are commonly classified as leukoplakia, erythroplakia, erythro-

leukoplakia, and chronic laryngitis, although there is no consensus on this issue.² Regarding the epidemiology of premalignant lesions, the data found in the literature are scarce. However, it is known that these lesions are more prevalent in males and usually affect individuals above 50 years of age.³

The evolution of laryngoscopic procedures in outpatients has provided better access to important information for safe and easy diagnosis of laryngeal pathologies. Preoperative assessment procedures have also evolved, and the

received
January 18, 2014
accepted
February 19, 2014
published online
July 22, 2014

DOI <http://dx.doi.org/10.1055/s-0034-1376431>.
ISSN 1809-9777.

Copyright © 2014 by Thieme Publicações Ltda, Rio de Janeiro, Brazil

License terms



introduction of new endoscopic methods is providing more informative analyses of lesions of the vocal folds.⁴

The dissociation between the diagnostic imaging in the preoperative and transoperative periods in patients submitted to laryngeal microsurgery has been observed in clinical practice, especially with respect to benign lesions of the vocal folds.^{5,6} Neither comparisons concerning premalignant lesions nor studies regarding the concomitance of benign and premalignant laryngeal lesions are found in the medical literature.

The aim of this study was to determine the accuracy of preoperative evaluation for the diagnosis of premalignant laryngeal lesions and their association with benign diseases of the vocal folds, as well as assessing their epidemiologic characteristics.

Methods

This cross-sectional and historical cohort study enabled retrospective analysis of medical records of patients who underwent laryngeal microsurgery by a single surgeon from 1990 to 2009. Anamnesis and physical examinations were performed in all patients. All of them complained of hoarseness and underwent flexible nasopharyngolaryngoscopic assessment (Machida ENT–30P III, Machida Endoscope Co., Japan) and rigid telescopic laryngoscopy using a 70-degree, 10-mm Storz telescope (Karl Storz GmbH & Co. KG, Germany) with stroboscopic light source to obtain preoperative diagnostic imaging. The equipment was coupled to a video system for the morphologic characterization, localization of the lesion, and documentation. Laryngeal microsurgery was performed in the operating room under general anesthesia. A Bouchayer-type suspension laryngoscope was used together with a DF Vasconcelos microscope (D.F. Vasconcelos S.A., São Paulo, Brazil) (400-mm lens, 16× or 24× magnifications). Laryngeal microscopy was performed by suspension laryngoscopy, making a thorough inspection, classic palpation maneuvers, and eversion of laryngeal structures using specific instruments for this purpose. Those patients who underwent the surgery after 2000 were submitted to rigid endoscopy with 0-, 30-, 70-, and 120-degree endoscopes and contact endoscopy with specific 0-degree endoscope. After defining the transoperative diagnostic imaging, lesions were completely excised and subsequently placed separately in 10% formaldehyde solution and forwarded to the pathology laboratory on the same day.

As inclusion criteria, we considered patients who had the following records in transoperative diagnostic imaging confirmed with postoperative anatomopathological exam: leukoplakia, erythroplakia, hyperkeratosis, leukoerythroplasia, dysplasia, and chronic laryngitis. The exclusion criteria took into account patients who did not have records of preoperative diagnostic imaging or confirming postoperative anatomopathological exam. The following data were collected: preoperative diagnostic imaging, transoperative diagnostic imaging, sex, and age.

The study followed the ethical recommendations for research involving human beings advocated in the Resolution No. 196/96 of the National Health Council. It was submitted

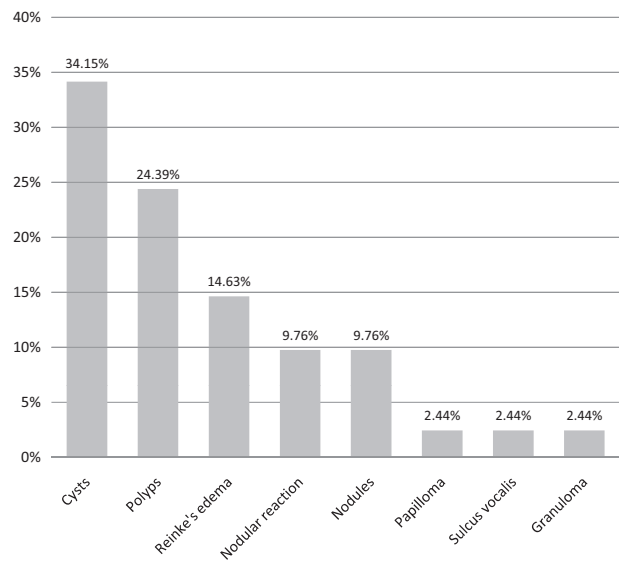


Fig. 1 Concomitant benign lesions of the vocal folds in patients with premalignant laryngeal lesions.

and approved by the Research Ethics Committee of the institution, under Protocol CAAE-1103.0.107.00007.

Results

A total of 558 patients were submitted to laryngeal microsurgery in the service from 1990 to 2009. According to the methodology proposed, 59 patients with premalignant lesions of the vocal folds were selected, which represented 10.57% of the sample.

During the preoperative period, diagnostic imaging of premalignant lesions was performed in 38 of the 59 patients (64.4%) who received this transoperative diagnosis. In the other 21 patients (35.6%), the diagnosis was performed during the surgical procedure.

In 26 of the 59 patients (44.07%) who had premalignant lesions diagnosed, other concomitant benign lesions of the vocal folds were observed, such as cysts—which were the most prevalent—followed by vocal fold polyps and Reinke edema (► **Fig. 1**).

Males were more prevalent (69.49%) than females (30.51%; ► **Fig. 2**). The average age was 47.74 years and the median was 47 years (20 to 85 years). The predominant age bracket was between 41 and 50 years. The third and the fifth decades were numerically equivalent (► **Fig. 3**). In females, premalignant lesions occurred most often in the sixth and the fifth decades of life, and in males, in the fifth and fourth decades (► **Fig. 4**).

Discussion

Premalignant laryngeal lesions have been a controversial topic of laryngeal pathology for decades, considering the classification, histologic diagnosis, and treatment of these lesions.² In addition to documenting diverse samples, studies

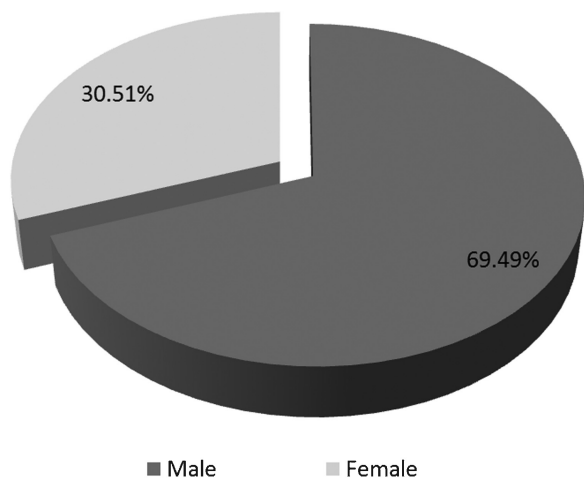


Fig. 2 Distribution of patients with premalignant laryngeal lesions according to sex.

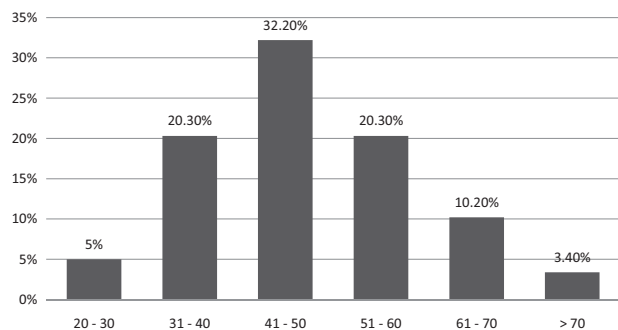


Fig. 3 Distribution of patients with premalignant lesions according to age.

on this topic are still scarce, especially regarding assessment in the transoperative period.

In our study, patients with imaging diagnosis of premalignant lesions represented 10.57% of the 558 patients submit-

ted to laryngeal microsurgery. In a 5-year follow-up study, Plch et al found 227 patients (18.10%) with histologic diagnosis of premalignant lesions among those submitted to laryngeal microsurgery.⁷ In a prevalence study, Araújo et al analyzed nasal-sinus and laryngeal tests of 214 outpatients, and they found 7.5% of the studied patients had suspected laryngeal carcinoma.⁸ In this way, 10.57% of the patients selected in our study were within the expected 7.5 and 18.10% considering the studies referenced.

There are still no comparative studies on outpatient and transoperative diagnoses of lesions considered premalignant found in the literature. However, some studies compare these diagnoses with benign findings in the vocal folds. Poels et al compared the consistency of preoperative diagnosis with transoperative diagnosis of benign lesions and claimed to have found 18% more benign lesions in the transoperative period.⁶ Neto et al conducted a comparative study between telescopic (outpatient) and suspension laryngoscopy (transoperative) for the diagnosis of benign lesions of the vocal folds.⁵ Accuracy in the outpatient diagnosis of benign lesions of the vocal folds was observed in 64.5% of the patients submitted to laryngoscopy, and the index of new benign lesions identified in the transoperative period was 23.3%. In our study, 64.6% of patients had diagnostic imaging of premalignant lesions confirmed in the transoperative period, and the index of new premalignant lesions identified in the transoperative period was 55.73%. It was expected that a larger number of lesions would be found in the transoperative period, considering that this is common in the clinical practice, which has been corroborated in the literature cited. However, it should be noted that regarding premalignant lesions, the index of new lesions identified in the transoperative period is greater than in the approach of benign lesions. With this, it is suggested that the transoperative method—whether conjugated to rigid and contact endoscopy or not—is more relevant for addressing premalignant than benign lesions.

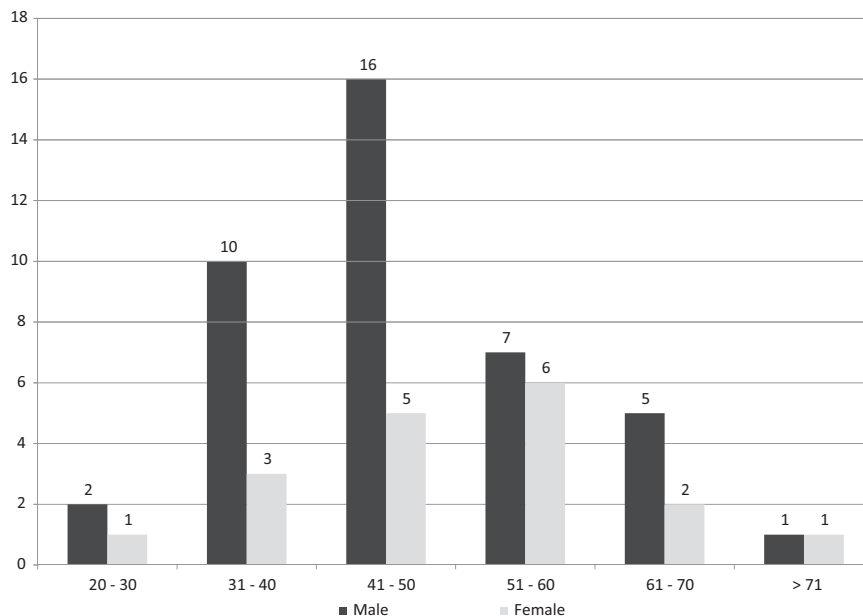


Fig. 4 Age bracket distribution by sex in patients with premalignant laryngeal lesions.

In addition to the diagnostic imaging of premalignant lesions in the transoperative period, there were also other associated lesions in 44% of the patients assessed in our study. The most prevalent lesion associated to premalignant ones was vocal fold cysts (34%). However, no data compatible with this association were found in the literature. Melo et al found 44 associated lesions in 267 patients with transoperative diagnosis of cysts, in which the most prevalent associated lesion was vascular dysgenesis (80%) and the least prevalent was leukoplakia, with only one case reported.⁹ Dailey et al stated that when using videolaryngostroboscopy, a cyst is more likely to be undistinguishable from other white masses that originated on the superficial lamina and decrease the flexibility of the mucosa.¹⁰ Thus, the association found in this study suggests that during the transoperative period it is possible that the surgeon detects other lesions able to reduce the wave in the mucosa and the vocal fold cyst. It is worth mentioning that definitive confirmation is obtained through anatomopathological study.

In a retrospective study conducted with 68 patients with vocal fold polyps, Sakae et al found only one case of leukoplakia associated to the polyp.¹¹ In our study, polyps were the second most prevalent associated lesion (24.39%), which was incompatible with the aforementioned study. On the other hand, Anghelina et al studied 32 patients with hyperplastic laryngeal lesions and found 12 (37%) patients with polyps.¹² This result is compatible with the findings in our study.

Plch et al considered Reinke edema and laryngeal papilloma as premalignant lesions,⁷ which did not occur in our study, as these lesions were not inclusion criteria. Reinke edema is a chronic inflammatory disease that can occur in smoker patients. Melo et al found a relationship between Reinke edema and leukoplakia in 35% of the patients.⁹ Martins et al conducted a histologic study and used electron microscopy with 54 smokers with Reinke edema.¹³ They stated that changes found in both methods were not specific for that lesion and were also present in benign lesions. However, they concluded that Reinke edema can harbor dysplasia as well as carcinoma sites. This statement is in agreement with our study, because we found an association of 14.63% between premalignant lesions and Reinke edema. The other lesion excluded from the inclusion criteria of our study—papilloma—is of epithelial origin caused by human papillomavirus infection and does not have an evidenced role with respect to its carcinogenic potential,¹⁴ although there are reports in the literature regarding its association to premalignant lesion and carcinoma.¹⁵ This association, although small, could be observed in our study, as papilloma corresponded to 2.44% of associated lesions.

Considering the differences between the findings of the preoperative and transoperative periods, it is recommended that laryngologists are prepared to modify the surgical planning and therapeutic approaches when necessary. At the same time, they have to be very attentive to benign lesions of the vocal folds, because they can be associated to premalignant lesions, which often can only be identified in the transoperative period. It is also important to inform the patients clearly about the possibility of revising the procedure

previously established, because the changes of the vocal folds observed through microlaryngoscopy and rigid and contact endoscopy can differ from those changes identified in the outpatient clinic.

With respect to sex, Plch et al reported that 62% of the patients with premalignant lesions were males.⁷ Anghelina et al assessed the clinical, morphologic, and immunohistochemical aspects of 32 patients with hyperplastic laryngeal lesions and found a predominance of males (66%).¹² Araújo et al observed that 68.7% of patients with suspicion of laryngeal carcinoma were males.⁸ On the other hand, the data obtained by Gale et al showed that 82.2% of the patients with clinical diagnosis of laryngeal leukoplakia and chronic laryngitis were males.² Our study showed that 69.5% of the patients were males, which is consistent with the studies conducted by Plch et al (62%),⁷ Anghelina et al (66%),¹² and Araújo et al (68.7%)⁸; however, this differed from the study conducted by Gale et al (82.2%).²

With respect to the age bracket, the results of the studies found differed. In the study conducted by Plch et al, the average age was 51.8 years (13 to 80 years) and most patients were in the sixth decade of life.⁷ Fischinger conducted a study with 178 patients with chronic hyperplastic laryngitis from 1994 to 1998 and the average age was 54 years (21 to 89 years).¹⁶ Sorting by sex, the prevalence of age brackets observed was 50 to 59 years in male patients and 40 to 49 in female patients. Araújo et al reported that 87.5% of patients with suspected carcinoma were older than 43 years of age.⁸ Gale et al reported an the average age of 51.5 years (14 to 86 years) in male patients and 44.8 years (19 to 89 years) in female patients.² In our study, the average age was 47 years (20 to 85 years), and most patients were in the fifth decade of life. When the distribution of the age bracket by sex was assessed, the largest frequencies of premalignant lesions in female patients occurred in the sixth and fifth decades of life, whereas in male patients they occurred in the fifth and fourth decades. Though differing in some aspects, all studies agree with an average age close to 50 years, regardless of sex.

A limitation of our study was that we did not associate the pre- and transoperative diagnoses of the benign lesions with the results of the postsurgical anatomopathological tests because the pathologists' diagnoses were often vague and nonspecific. Morphologically characterized lesions, such as cysts and polyps, were reported as "chronic nonspecific inflammatory processes." This fact reinforces the growing need for integration between otolaryngologists and pathologists in the sense of sharing knowledge about the morphofunctional characteristics of each lesion. Another limitation was the use of rigid endoscopy and contact endoscopy only in patients who underwent the surgery after 2000. The difference in the methodology used in the two phases of the study could theoretically lead to variations in the transoperative diagnosis of patients. However, from the mentioned year, our service experienced a sharp growth of the surgical cases, which made the group of patients submitted to these trans-surgical endoscopic method considerably larger, thus preventing comparisons with statistical validity.

Conclusion

Although the evolution of laryngoscopic procedures in outpatients has provided better access to important information for safe and easy diagnosis of laryngeal pathologies, about one-third of premalignant lesions are diagnosed just during the laryngeal microsurgery. Cysts were the most prevalent concomitant benign lesion of the vocal folds. Males were more prevalent than females, and the predominant age bracket was between 41 and 50 years.

References

- 1 Pinto JA, Steffen N, Carpes AF. Lesões pré-malignas da laringe. In: Associação Brasileira de Otorrinolaringologia e Cirurgia Cérvico-Facial (Org.). *Manuais de Otorrinolaringologia*, 1st ed. São Paulo, Brazil: Associação Brasileira de Otorrinolaringologia e Cirurgia Cérvico-Facial; 2008:104–111
- 2 Gale N, Michaels L, Luzar B, et al. Current review on squamous intraepithelial lesions of the larynx. *Histopathology* 2009;54(6): 639–656
- 3 Padial MB, Ronchi DI, Madeira K. Epidemiological profile of malignant neoplasms of the larynx in a laboratory of pathology in Criciúma - SC the period 2006 to 2010. *Arq Catarin Med* 2011; 40(4):64–68
- 4 D'Avila JS, Santos RC, D'Avila DV. Métodos de avaliação em laringologia. In: Associação Brasileira de Otorrinolaringologia e Cirurgia Cérvico-Facial (Org.). *Manuais de Otorrinolaringologia*, 1st ed. São Paulo, Brazil: Associação Brasileira de Otorrinolaringologia e Cirurgia Cérvico-Facial; 2008:136–145
- 5 Mendes Neto JA, Pinna BR, Caporrino Neto J, Pedrosa JE. Comparison between telelaryngoscopy and suspension laryngoscopy in the diagnosis of benign vocal fold lesions. *Braz J Otorhinolaryngol* 2008;74(6):869–875
- 6 Poels PJP, de Jong FICRS, Schutte HK. Consistency of the preoperative and intraoperative diagnosis of benign vocal fold lesions. *J Voice* 2003;17(3):425–433
- 7 Plch J, Pár I, Navrátilová I, Bláhová M, Zavadil M. Long term follow-up study of laryngeal precancer. *Auris Nasus Larynx* 1998;25(4): 407–412
- 8 Araújo A, Zettler EW, Santos MA, et al. Prevalence of laryngeal alterations in the high respiratory endoscopy service. *Int Arch Otorhinolaryngol* 2009;13(4):440–443
- 9 Melo ECM, Brito LL, Brasil OCO, et al. Incidence of non-neoplastic lesion in patients with vocal complains. *Braz J Otorhinolaryngol* 2001;67(6):788–794
- 10 Dailey SH, Spanou K, Zeitels SM. The evaluation of benign glottic lesions: rigid telescopic stroboscopy versus suspension micro-laryngoscopy. *J Voice* 2007;21(1):112–118
- 11 Sakae FA, Sasaki F, Sennes LU, et al. Vocal fold polyps and cover minimum structural alterations: associated injuries? *Braz J Otorhinolaryngol* 2004;70(6):739–741
- 12 Anghelina F, Ioniță E, Popescu CF, et al. Clinical, morphological and immunohistochemical aspects in laryngeal premalignant lesions. *Rom J Morphol Embryol* 2006;47(2):169–174
- 13 Martins RHG, Fabro AT, Domingues MAC, Chi AP, Gregório EA. Is Reinke's edema a precancerous lesion? Histological and electron microscopic aspects. *J Voice* 2009;23(6):721–725
- 14 Gallo A, Degener AM, Pagliuca G, et al. Detection of human papillomavirus and adenovirus in benign and malignant lesions of the larynx. *Otolaryngol Head Neck Surg* 2009;141(2):276–281
- 15 Sadri M, McMahon J, Parker A. Management of laryngeal dysplasia: a review. *Eur Arch Otorhinolaryngol* 2006;263(9):843–852
- 16 Fischinger J. Epithelial hyperplastic lesions in chronic hyperplastic laryngitis of patients treated from 1994 to 1998 at the Department of Otorhinolaryngology and Cervicofacial Surgery in Ljubljana. *Zdrav Vestn* 2002;71(3):69–71