



# The outcome of transobturator anterior vaginal wall prolapse repair using porcine dermis graft: intermediate term follow-up

Ayman Mahdy, Deborah Karp, G. Willy Davila, Gamal M. Ghoniem

*Section of Female Urology, Division of Urology, Department of Surgery (AM), University of Cincinnati, Cincinnati, OH; Department of Gynecology and Obstetrics (DK), Emory University School of Medicine, Atlanta, GA; Section of Urogynecology and Pelvic Reconstructive Surgery, Department of Gynecology (WD), Cleveland Clinic, Weston, FL and Division of Female Urology, Pelvic Reconstructive Surgery & Voiding Dysfunction, Department of Urology (GMG), University Of California Irvine, Orange, CA, USA*

## ABSTRACT

**Introduction and Hypothesis:** We evaluated the anatomical success and complications of Perigee® with porcine dermis Graft in the repair of anterior vaginal wall prolapse (AVWP).  
**Materials and Methods:** After Institutional Review Board (IRB) approval, the charts of all patients who underwent AVWP repair using the Perigee/InteXen® kit from July 2005 to July 2009 were reviewed. Patients who had less than 6-month follow-up were excluded. Preoperative data including patient age, previous AVWP repairs, hysterectomy status, preoperative dyspareunia and pertinent physical findings were collected and recorded. Postoperative success was defined as anatomical stage 0 or I using the Pelvic Organ Prolapse Quantification (POP-Q) scoring system. Graft related complications were also recorded.

**Results:** Out of 89 patients, 69 completed at least 6-month follow-up. Median follow-up was 13 (6-48) months. Seventeen patients (25%) had previous AVWP repair and 32 (46%) had previous hysterectomy. Preoperatively, AVWP stage II was found in 9 (13%), stage III in 27 (39%) and stage IV in 33 (48%) patients. Anatomic success was found in 48 (69%) patients, with 23 (33%) having stage 0 and 25 (36%) stage I AVWP. Intraoperative complications included incidental cystotomy in one patient and bladder perforation in one. Postoperative complications included vaginal exposure and dyspareunia in one case, wound dehiscence in one and tenderness over the graft arm with dyspareunia in one.

**Conclusions:** The use of porcine dermis in AVWP repair is safe with minimal graft related complications; however, anatomical success is lower than that reported with the use of synthetic grafts.

## ARTICLE INFO

### Key words:

Prolapse; Transplants; Cystocele; Vagina

**Int Braz J Urol. 2013; 39: 506-12**

Submitted for publication:  
October 08, 2012

Accepted after revision:  
May 29, 2013

## INTRODUCTION

Pelvic organ prolapse (POP) (1) occurs in 30 to 50 % of women (1). The most common type of POP is anterior vaginal wall prolapse (AVWP)

with a reported incidence of 34.3% (2). Although still commonly used by many pelvic reconstructive surgeons, traditional colporrhaphy for AVWP repair has a recurrence rate of up to 20% (3) with a more recently reported failure rate up to 70%

(4). During traditional colporrhaphy, the laterally placed pubocervical fascia is medially plicated; however, this technique is thought to potentially lead to vaginal shortening and narrowing (5). Additionally, 70 to 80% of AVWP cases may have a concomitant lateral defect (6) in which case the sole plication of the pubocervical fascia is not a viable option.

Consequently, given these limitations for anterior colporrhaphy, graft augmented repair has gained interest within the field of female pelvic reconstructive surgery. The purpose behind the use of these grafts is to obtain more durable and efficient prolapse repair while preserving sexual function without negative impacts on vaginal length and/or caliber. Many subtypes of grafts have been developed including autologous grafts, allografts, xenografts, and synthetic grafts. Polypropylene synthetic grafts are associated with significant host tissue reaction with a reported incidence of extrusion of up to 45%. Newer light-weight polypropylene grafts have lower rates of graft erosion ranging from 5-15% (7).

In order to obtain a satisfactory outcome with the use of xenografts, the graft should be biocompatible, strong, durable, resistant to infection and facilitate host tissue in-growth (8). In 2004, Zheng et al. compared porcine dermis with polypropylene grafts in the repair of full thickness abdominal wall defects in rats. They found decreased adhesion formation and milder inflammatory response with porcine dermis compared with polypropylene grafts (9). The relative safety of biological versus synthetic grafts was further supported by a recent randomized controlled trial (10).

Limited data is available regarding anatomical success associated with the use of biological grafts. Porcine dermis for AVWP repair has been recently used with variable outcomes. In most of the reported studies, the graft was secured laterally with delayed absorbable sutures (5-6,11). After gaining popularity as a mode of sling fixation, the transobturator approach was also employed in graft augmented AVWP repairs. The first publication of the use of transobturator four-arm biologic graft in AVWP repair was by Eglin in 2003 (12). We recently reported high short term success with a porcine dermis graft placed via a transobturator

approach using the Perigee® kit with InteXene® (American Medical Systems, Minnetonka, MN, USA) (13). The long term anatomic success rate using this type of graft in prolapse repair is still not well known. In this study, we present our intermediate term follow-up of AVWP repair using porcine dermis graft through the transobturator approach in an expanded patient population.

## MATERIALS AND METHODS

After obtaining Institutional Review Board approval, the charts of patients who underwent AVWP repair using the Perigee® with the biocompatible porcine dermis graft (InteXen®) within the Sections of Urogynecology and Pelvic Reconstructive Surgery and Female Urology at the study institution were reviewed. Only patients who completed at least 6-month follow-up were included.

All patients had routine preoperative assessment with history, physical exam, and multi-channel urodynamics (UDS). UDS were performed with and without prolapse reduction in order to assess for possible occult stress urinary incontinence (2). POP was staged using the POP-Q system in all cases. Cases involving hematuria, lower urinary tract storage symptoms (i.e. urgency, frequency and/or urge incontinence), history of lower urinary tract pathology or intrinsic sphincter deficiency underwent cystoscopy pre-operatively. Topical vaginal estrogen cream was used preoperatively in all patients with urogenital atrophy.

AVWP repairs were performed using the Perigee® kit with InteXen®. The technique was previously described (13). In brief, a 16 Fr Foley's catheter is inserted into the bladder. After infiltration of local anesthesia, an anterior vaginal wall incision is performed from the bladder neck to approximately 2-3 cm to the vaginal apex. Dissection is extended laterally to the lateral vaginal sulcus until the ischial spine and arcus tendineus fascia pelvis are easily palpable bilaterally. The skin puncture sites for the graft introducers are marked. The upper skin punctures are made at the medial border of the obturator foramen at the level of the clitoris and approximately 1.5 cm below the insertion of the adductor longus tendon. The two lower punctures are 3 cm inferior and 2

cm lateral to the upper ones. The trocar is guided through the obturator membrane and through the paravesical space and is externalized through the vaginal incision on both sides along the arcus tendineus as close as possible to the ischial spine. At this point, cystoscopy is performed to exclude bladder or urethral injury and to assure ureteral patency. The Perigee® arms are then connected to the trocars and brought out through the skin incisions. The InteXen® mesh is then trimmed, its arms' tensioned loosely, and the graft is secured to the underlying connective tissue using absorbable sutures. The vaginal mucosa is closed, a final mesh adjustment performed, the plastic sleeves of the mesh arms are removed, and the arms are cut flush with the skin. The skin incisions are closed using Dermabond® surgical glue (Ethicon, Somerville, NJ). Vaginal packing and a Foley catheter are left in place for 24 hours postoperatively. If a concomitant suburethral sling is indicated, the sling procedure is performed secondarily through a separate incision.

Pre and postoperative management were standardized for all patients. All patients received

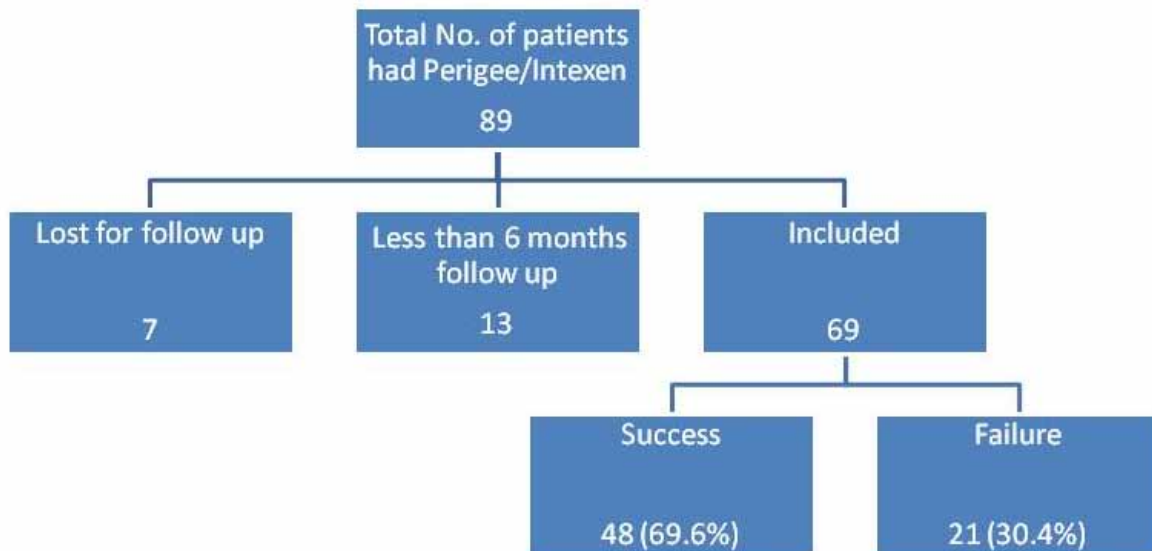
appropriate preoperative antibiotic prophylaxis and were observed in the hospital for at least 24 hours postoperatively. Patients were followed at 2 and 6 weeks, and then 6, 12 and 18 months and yearly thereafter. The 2 week post-operative visit included only brief history, and vaginal examination with POP-Q was performed at the 6-week visit and all subsequent visits.

**RESULTS**

Sixty nine patients fulfilled the inclusion criteria with at least six month postoperative follow-up. The mean follow up was 13 (6-48) months. The flow chart (Figure-1) details the patients' availability for follow-up. Of those who were excluded due to short-term or lack of follow-up, none had anatomic recurrence at the last documented visit. Fifty two patients (75%) had primary and 17 patients (25%) had recurrent AVWP.

Table-1 lists the preoperative data. Preoperative median age was 63 (41-87) years, total vaginal length 10 (8-12) cm, and mean POP-Q point Ba 1.8 ± 2.4 cm. Fifty five patients (80%) had at least one

**Figure 1 - Flow chart delineates the number of patients recruited.**



concomitant vaginal surgery with sling procedure in 25 (36%), posterior colporrhaphy with graft in 28 (41%), and posterior colporrhaphy without graft in 17 (25%). Preoperatively, eight patients had dyspareunia. All patients with dyspareunia had their dyspareunia improved postoperatively; however, two patients (2.8%) developed de novo dyspareunia.

Anatomical success as defined by anterior wall POP-Q stage  $\leq 1$  was achieved in 48 (70%) patients (Table-2). Mean postoperative POP-Q point Ba was  $-1.0 \pm 2.3$  cm. In cases that developed recurrence, the median time to recurrence was 5.6 (3-24) months. One third of patients with anatomical recurrence had no symptoms (Table-3). Reoperation was performed in two patients (3%) while the re-

**Table-1 - Shows patients pre-operative data.**

		No. Patients (%)
Previous AVWP repair		17 (25)
Previous Hysterectomy		32 (46)
AVWP	Stage II	9 (13)
	Stage III	27 (39)
	Stage IV	33 (48)

**Table 2 - Shows postoperative stages AVWP.**

Postoperative stage	N of patients (%)
0	23 (33)
I	25 (36)
II	11 (16)
III	6 (9)
IV	4 (6)
Total	69 (100)

**Table 3 - Symptoms in patients with recurrent AVWP.**

Symptom	N. Patients	
Urgency/frequency	3	
Urinary incontinence	SUI	1
	UUI	2
	MUI	1
Vaginal bulge/pressure/lump	6	
Mix of symptoms	1	
No symptoms	7	
Total	21	

mainder elected no intervention. There was no specific correlation found between recurrence and patients' age and local tissue quality.

Intraoperative complications included one case of incidental cystotomy which occurred during dissection and one bladder perforation with the right anterior Perigee introducer. Both complications were managed successfully without long-term sequel with primary cystotomy repair and one-week bladder drainage for the first case and reposition of the trocar for the second one. Postoperative complications included graft exposure and dyspareunia in one case, wound dehiscence in one, and dyspareunia and tenderness to palpation at the left inferior graft edge in one case. No major medical complications were encountered in our cohort.

## DISCUSSION

The common incidence of AVWP makes it a favorite target for clinical and basic science research. The incomplete understanding of its pathogenesis and mechanism of recurrence makes management of AVWP controversial. A major source of debate is the role of grafts in POP repair and the type of graft to be used. Several published reports encouraged more research in graft

materials; their outcome and complications with particular interest in longer term follow-up. Graft related complications gained a wide interest between both healthcare providers and patients in the recent few years. In October 2008, the United States Food and Drug Administration (FDA) issued a public health notification on complications associated with surgical mesh for treatment of POP. This was followed by an update of those complications in July 2012 (14).

The use of biological graft materials in POP was suggested to be associated with lower complication but higher recurrence rates compared with synthetic counterparts (discussion below).

In this study, we report our intermediate term outcome of AVWP repair using the Perigee/Intexen® kit with biologic porcine dermis graft.

The overall anatomical success in our series is 70%. This is comparable to that reported by Handel et al. (5) who reported a 64% success using porcine dermis at 17-month follow-up. This anatomical outcome however is less than the greater than 90% anatomic success rates reported with polypropylene mesh using the same transobturator approach for graft support (15-18). Interestingly, we noted that our intermediate follow-up success rate was significantly lower than the 95% success rate we reported on a smaller cohort of patients with shorter follow-up (13). These findings together provide support to the notion that biological grafts may have less long-term durability than synthetic mesh.

Compared with 21 anatomic failures, only two patients had reoperation for POP in our cohort. The discrepancy between recurrence and reoperation rates has been previously reported. In a study of 207 cases that had anterior colporrhaphy, Kapoor et al. reported a 12% recurrence rate with only a 3.4% reoperation rate (19). This discrepancy could be explained in different aspects. Patients who have recurrent prolapse might not be bothered with it or might not have the same degree of bother they experienced before surgery. In addition, patient experience with surgery and recovery as well as social and economic factors might also dissuade the patient from seeking additional surgery. We published this same observation in a study that compared surgical outcome between patients with POP who

had graft alone with those who had graft combined with fascial plication (20).

One of the major concerns associated with graft use is graft-related complications. Of these, vaginal graft exposure and graft erosion into the lower urinary tract are among the most worrisome. In this series we experienced only one case of vaginal graft exposure (1.4%). This patient presented with vaginal irritation and dyspareunia, and the site of the exposure was at the junction between the biological graft and the synthetic arm (Riv Fix). Exposure at the biological/synthetic graft interface was also reported by Araco et al. (21). The exposed part was successfully trimmed in the office with resolution of the patient's symptoms. The rate of graft exposure in our series is less than the 10.5% exposure rate reported with the Perigee® system with polypropylene mesh (Perigee/Intepro®) (16). Other authors have reported high mesh exposure rate using the porcine dermis in AVWP repair. It has to be noted however that we used a ready to use kit which shortens operative time and thus may decrease risk of contamination. To prevent graft bacterial contamination, all patients underwent placement of a peri-anal cerclage suture, placed before initiating the procedure (22). In addition, the pores in the Perigee/Intexen® graft may minimize the risk for hematoma formation, a possible cause for the high graft-related complication rate reported in these studies (5,23). The relative safety of biological compared with synthetic grafts has been reported by others (10,24,25).

The second graft related complication was tenderness over the left proximal polypropylene arm. This same patient also had a concomitant posterior colporrhaphy with fascia lata graft. She was offered graft excision but declined. An additional third case with wound dehiscence occurred likely due to hematoma formation as opposed to intraoperative graft contamination. She was successfully treated with antibiotics, and primary wound closure in the operating room.

It is notable that nine of our patients (13%) had stage II AVWP prior to surgery. Even though we reserve graft use for high stage POP (III and IV), there are other factors we considered in this cohort of patients. These factors included failed previous repair, advanced age of the patients, and

poor tissue quality encountered at the time of anterior wall dissection.

Why is the success rate of biologic graft augmentation lower than with the use of synthetic graft in AVWP repair? Implantation technique and graft behavior after implantation are likely two key variables. Intexen® is a non-crosslinked biologic graft and thus undergoes biologic degradation and enzymatic breakdown while tissue ingrowth and neo-vascularization occurs. In order to reduce the degree of strain placed upon an implanted biologic graft, we have begun placing the graft as an overlay to a midline plication with significantly improved results (20). In this series, the Intexen® graft was implanted without prior midline fascial plication.

Our study has strengths and limitations. The strengths include the relatively long term follow-up and large number of patients. In addition, we report a single-center experience with only two attending surgeons (WD and GG) ensuring technique standardization. One of the limitations of this study is its retrospective nature with inherent bias. We also acknowledge the lack of use of validated questionnaires in order to objectively assess functional outcomes. It has to be noted however that more than half of our patients had concomitant vaginal procedures and more than a third had another graft for posterior wall prolapse repair. This makes it difficult to accurately assess the functional outcome of the porcine dermis graft for AVWP repair alone.

This kit is not intended to provide apical vaginal support and recently is being replaced by newly designed kits that concomitantly address apical support. However this report provides valuable data to the literature; first because patients who underwent this type of graft repair will still be followed and they will be encountered in clinical practice within the next few years. And secondarily, we present the outcome of the porcine dermis graft which is currently in use with other vaginal POP suspensory kits.

## CONCLUSIONS

In conclusion we found the intermediate term success of AVWP repair using the porcine dermis graft through the transobturator approach to

be less favorable than that reported for a synthetic graft, from an anatomic perspective. The graft is relatively safe and is associated with minimal graft-related complications. Longer term follow-up and Randomized Controlled Trials are highly encouraged to precisely compare synthetic versus biological grafts in POP repair.

## ABBREVIATIONS

ATFP = Arcus Tendinous Fascia Pelvis  
 AVWP = Anterior Vaginal Wall Prolapse  
 FDA = Food and Drug Administration  
 IRB = Institutional Review Board  
 MUI = Mixed Urinary Incontinence  
 POP = Pelvic organ prolapse  
 PO-Q = Pelvic Organ Prolapse Quantification  
 SUI = Stress Urinary Incontinence  
 UDS = multichannel urodynamics  
 UUI = Urgency Urinary Incontinence

## CONFLICT OF INTEREST

Willy Davila: Consultant/honoraria: Astellas, Novasys medical and CL medical; Consultant/Research funding: American Medical System  
 Gamal Ghoniem: Speaker: Astellas and Allergan; Research: Uroplasty

## REFERENCES

1. Beer M, Kuhn A: Surgical techniques for vault prolapse: a review of the literature. *Eur J Obstet Gynecol Reprod Biol.* 2005; 119: 144-55.
2. Hendrix SL, Clark A, Nygaard I, Aragaki A, Barnabei V, McTiernan A: Pelvic organ prolapse in the Women's Health Initiative: gravity and gravidity. *Am J Obstet Gynecol.* 2002; 186: 1160-6.
3. Macer GA: Transabdominal repair of cystocele, a 20 year experience, compared with the traditional vaginal approach. *Trans Pac Coast Obstet Gynecol Soc.* 1978; 45: 116-20.
4. Weber AM, Walters MD, Piedmonte MR, Ballard LA: Anterior colporrhaphy: a randomized trial of three surgical techniques. *Am J Obstet Gynecol.* 2001; 185: 1299-304; discussion 1304-6.
5. Handel LN, Frenkl TL, Kim YH: Results of cystocele repair: a comparison of traditional anterior colporrhaphy, polypropylene mesh and porcine dermis. *J Urol.* 2007; 178: 153-6; discussion 156.

6. Gomelsky A, Rudy DC, Dmochowski RR: Porcine dermis in-reposition graft for repair of high grade anterior compartment defects with or without concomitant pelvic organ prolapse procedures. *J Urol*. 2004; 171: 1581-4.
7. Debodinance P, Cosson M, Collinet P, Boukerrou M, Lucot JP, Madi N: Synthetic meshes for transvaginal surgical cure of genital prolapse: evaluation in 2005. *J Gynecol Obstet Biol Reprod (Paris)*. 2006; 35: 429-54.
8. Cosson M, Debodinance P, Boukerrou M, Chauvet MP, Lobry P, Crépin G, et al.: Mechanical properties of synthetic implants used in the repair of prolapse and urinary incontinence in women: which is the ideal material? *Int Urogynecol J Pelvic Floor Dysfunct*. 2003; 14: 169-78; discussion 178.
9. Zheng F, Lin Y, Verbeken E, Claerhout F, Fastrez M, De Ridder D: Host response after reconstruction of abdominal wall defects with porcine dermal collagen in a rat model. *Am J Obstet Gynecol*. 2004; 191: 1961-70.
10. Natale F, La Penna C, Padoa A, Agostini M, De Simone E, Cervigni M: A prospective, randomized, controlled study comparing Gynemesh, a synthetic mesh, and Pelvicol, a biologic graft, in the surgical treatment of recurrent cystocele. *Int Urogynecol J Pelvic Floor Dysfunct*. 2009; 20: 75-81.
11. Wheeler TL 2nd, Richter HE, Duke AG, Burgio KL, Redden DT, Varner RE: Outcomes with porcine graft placement in the anterior vaginal compartment in patients who undergo high vaginal/uterusacral suspension and cystocele repair. *Am J Obstet Gynecol*. 2006; 194: 1486-91.
12. Eglin G, Ska JM, Serres X: Transobturator subvesical mesh. Tolerance and short-term results of a 103 case continuous series. *Gynecol Obstet Fertil*. 2003; 31: 14-9.
13. Mahdy A, Elmissiry M, Ghoniem G: The outcome of transobturator cystocele repair using biocompatible porcine dermis graft: our experience with 32 cases. *Int Urogynecol J Pelvic Floor Dysfunct*. 2008; 19: 1647-52.
14. The US Food and Drug Administration: FDA Safety Communication: UPDATE on Serious Complications Associated with Transvaginal Placement of Surgical Mesh for Pelvic Organ Prolapse. Available at <http://www.fda.gov/medicaldevices/safety/alertsandnotices/ucm262435.htm>
15. Eboue C, Marcus-Braun N, von Theobald P: Cystocele repair by transobturator four arms mesh: monocentric experience of first 123 patients. *Int Urogynecol J*. 2010; 21: 85-93.
16. Moore RD, Beyer RD, Jacoby K, Freedman SJ, McCammon KA, Gambla MT: Prospective multicenter trial assessing type I, polypropylene mesh placed via transobturator route for the treatment of anterior vaginal prolapse with 2-year follow-up. *Int Urogynecol J*. 2010; 21: 545-52.
17. Moore RD, Miklos JR: Vaginal repair of cystocele with anterior wall mesh via transobturator route: efficacy and complications with up to 3-year follow-up. *Adv Urol*. 2009: 743831.
18. Grgic O, Oreskovic S, Grgic HL, Kalafatic D, Zupic T, Maurac I: Outcome and efficacy of a transobturator polypropylene mesh kit in the treatment of anterior pelvic organ prolapse. *Int J Gynaecol Obstet*. 2012; 116: 72-5.
19. Kapoor DS, Nemcova M, Pantazis K, Brockman P, Bombieri L, Freeman RM: Reoperation rate for traditional anterior vaginal repair: analysis of 207 cases with a median 4-year follow-up. *Int Urogynecol J*. 2010; 21: 27-31.
20. Karp DR, Peterson TV, Mahdy A, Ghoniem G, Aguilar VC, Davila GW: Biologic grafts for cystocele repair: does concomitant midline fascial plication improve surgical outcomes? *Int Urogynecol J*. 2011; 22: 985-90.
21. Araco F, Gravante G, Overton J, Araco P, Dati S: Transvaginal cystocele correction: Midterm results with a transobturator tension-free technique using a combined bovine-pericardium/polypropylene mesh. *J Obstet Gynaecol Res*. 2009; 35: 953-60.
22. Biller DH, Guerette NL, Bena JF, DavilaGW: A prospective, randomized controlled trial of the use of an anal purse-string suture to decrease contamination during pelvic reconstructive surgery. *Int Urogynecol J Pelvic Floor Dysfunct*. 2008; 19: 59-63.
23. Simsiman AJ, Luber KM, Menefee SA: Vaginal paravaginal repair with porcine dermal reinforcement: correction of advanced anterior vaginal prolapse. *Am J Obstet Gynecol*. 2006; 195: 1832-6.
24. Deval B, Haab F: Management of the complications of the synthetic slings. *Curr Opin Urol*. 2006; 16: 240-3.
25. Trabuco EC, Klingele CJ, Gebhart JB: Xenograft use in reconstructive pelvic surgery: a review of the literature. *Int Urogynecol J Pelvic Floor Dysfunct*. 2007; 18: 555-63.

---

**Correspondence address:**

Dr. Gamal M. Ghoniem  
Vice Chair and Professor of Urology  
Chief Division of Female Urology,  
Pelvic Reconstructive Surgery & Voiding Dysfunction  
333 City Blvd West, Suite 2100  
Orange, CA, 92868, USA  
Telephone: + 1 714 450-3876  
E-mail: [gghoniem@hs.uci.edu](mailto:gghoniem@hs.uci.edu)