

# Challenging Non-Traumatic Posterior Urethral Strictures Treated with Urethroplasty: A Preliminary Report

Nicolaas Lumen, Willem Oosterlinck

*Department of Urology, Ghent University Hospital, Ghent, Belgium*

---

## ABSTRACT

*Introduction:* Posterior urethral strictures after prostatic radiotherapy or surgery for benign prostatic hyperplasia (BPH) refractory to minimal invasive procedures (dilation and/or endoscopic urethrotomy) are challenging to treat. Published reports of alternative curative management are extremely rare. This is a preliminary report on the treatment of these difficult strictures by urethroplasty.

*Materials and Methods:* Seven cases were treated: 4 cases occurred after open prostatectomy or transurethral resection of the prostate for BPH, one case after external beam irradiation and 2 after brachytherapy. The 4 cases after BPH-related surgery were in fact complete obstructions at the bladder neck and the membranous urethra with the prostatic urethra still partially patent. Anastomotic repair by perineal route was done in all cases with bladder neck incision in the BPH-cases and prostatic apex resection in the radiotherapy cases.

*Results:* Mean follow-up was 31 months (range: 12-72 months). The operation was successful, with preserved continence, in 3 of the 4 BPH-cases and in 2 of the 3 radiotherapy cases. An endoscopic incision was able to treat a short re-stricture in the BPH-patient and a longer stricture at the bulbar urethra could be managed with a perineostomy in the radiotherapy-patient.

*Conclusion:* Posterior non-traumatic strictures refractory to minimal invasive procedures (dilation/endoscopic urethrotomy) can be treated by urethroplasty using an anastomotic repair with a bladder neck incision if necessary.

*Key words:* urethra; urethral stricture; reconstructive surgical procedures; radiotherapy; benign prostatic hyperplasia  
*Int Braz J Urol. 2009; 35: 442-9*

---

## INTRODUCTION

Posterior urethral strictures are complications that may occur after prostatic radiotherapy or surgery for benign prostatic hyperplasia (BPH). Urethral strictures have been reported in up to 8% after brachytherapy (1), in up to 6% after external beam radiotherapy (2), in 2.2-9.8% after transurethral resection of the prostate (TURP) (3) and in 1.9% after simple open prostatectomy (4). Most of these strictures however can be treated by minimal invasive procedures such as dilation or endoscopic urethrotomy (5,6). When these procedures fail,

reported descriptions of further management by urethroplasty are extremely rare as only one paper on the subject could be found (7). The incidence of non-traumatic posterior urethral strictures and the need for urethroplasty will probably rise due to the high number of patients undergoing TURP, radical or simple prostatectomy and due to the increasing interest in brachytherapy and external beam radiotherapy for the treatment of prostate cancer.

The deep location in the body, behind the pubic bone, just above the pelvic floor and the voluntary sphincter mechanism, and the possible involvement of the continence mechanism of the bladder neck makes

the treatment highly challenging. Therefore, we were prompted to report our experience in this field.

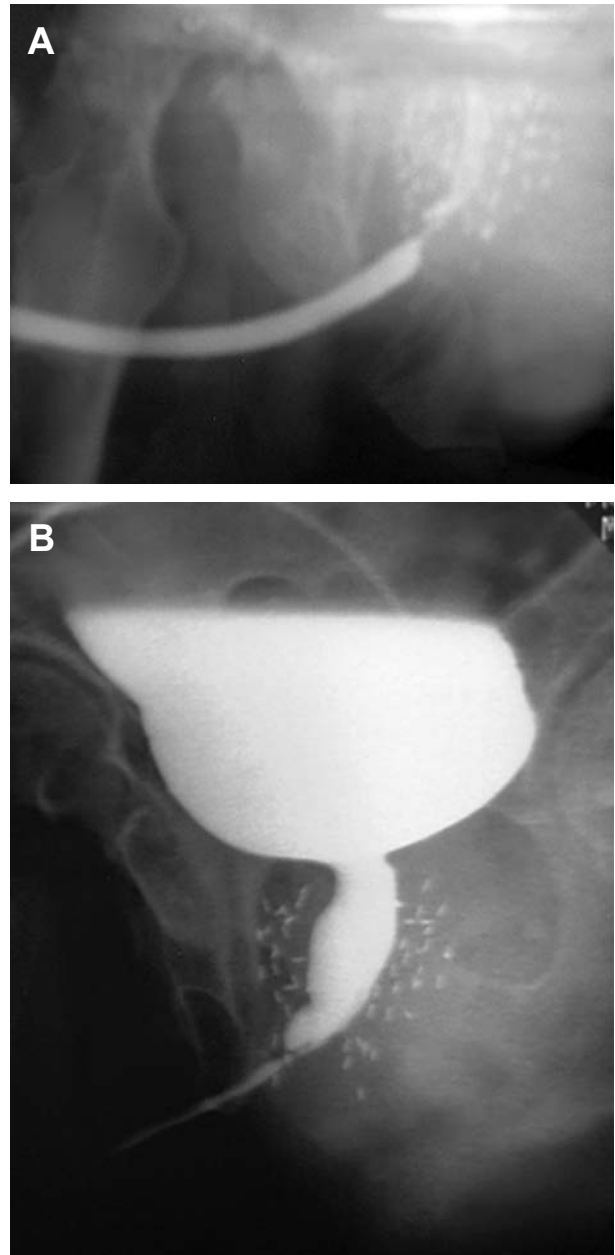
## MATERIAL AND METHODS

Between 2001 and 2007, seven cases of non-traumatic posterior urethral strictures were treated by urethroplasty (Table-1). These cases were identified using a prospectively collected database. Mean age was 70.4 years (range: 62-78 years). Before referral to our centre, endoscopic incision had been attempted in all cases. In 4 cases, the procedure had to be stopped due to a false routing. In the other cases recurrence occurred almost immediately. Endoscopic incision was repeated in 2 patients and one was dilated regularly. The strictures were the consequence of open prostatectomy (Millin-technique) for BPH in one patient and transurethral resection of the prostate (TURP) in the 3 others. All these 4 BPH-patients were unable to void immediately after their BPH-surgery for at least 2 weeks. Two patients received brachytherapy and one external irradiation for localized prostate cancer. In all patients, a retrograde urethrography combined with a cysto-urethrography was done to assess the location and length of the stricture and the condition of the bladder neck. In the BPH-cases, retrograde urethrography revealed a complete obstruction at the membranous urethra and on trial to void, the bladder neck remained closed. In these cases, a suprapubic cystoscopy revealed a completely strictured bladder neck. In the irradiated cases the bladder neck was still patent but the prostatic urethra was partially obstructed (Figure-1). Six out of 7 patients had a suprapubic catheter: all BPH-patients and 2 irradiated patients.

### Operative Technique

Antibiotics (fluoroquinolones) were started 24 hours prior to surgery and continued for three days. In cases of infected urine, antibiotics were given based on the results of the urine culture. The patient was placed in the high lithotomy position. All patients were operated by a midline perineal incision and by that route alone. The bulbospongiosum muscle was

dissected away from the corpus spongiosum. The bulbar urethra was circumferentially dissected from the ventral aspect of the corpora cavernosa from the penoscrotal angle until its passage through the pelvic floor. The bulbus was attracted and the urethra



**Figure 1** – Retrograde urethrography (A) and voiding cysto-urethrography (B) showing a stricture at the distal prostatic urethra after brachytherapy. The bladder neck is patent in this case.

Table 1 – Patients' characteristics and outcomes.

Patient	Age (years)	Follow-up (months)	Etiology	Previous Endoscopic Interventions	Suprapubic Catheter	Bladder Neck	Structure Length (cm) and Location	Failure	Treatment of Failure	Incontinence
1	66	12	TURP	1	Yes	Obliterated	1.5 – membranous urethra	NO	-	NO
2	63	72	TURP	4	Yes	Obliterated	2 – membranous urethra	NO	-	NO
3	78	25	TURP	3	Yes	Obliterated	3 – membranous and apical prostatic urethra	YES, after 3 months	endoscopic incision	YES (1-2 pads/day)
4	76	12	Open prostatectomy	2	Yes	Obliterated	2.5 – membranous and apical prostatic urethra	NO	-	NO
5	74	48	External beam radiotherapy	2	Yes	Open	1.5 – apical prostatic urethra	YES, after 6 months	perineostomy	NO
6	62	20	brachytherapy	1	No	Open	2 – apical prostatic urethra	NO	-	YES (1-2 pads/day)
7	74	29	brachytherapy	1	Yes	Open	2 – apical prostatic urethra	NO	-	NO

was further dissected through the pelvic floor. The fibrotic column of the strictured membranous urethra is followed as far as possible. A large Beniqué sound (26F) was introduced inside the urethra and marked the distal level of the defect. The urethra was transected at this level. The transected distal part of the urethra is spatulated after removal of all fibrosis. The residual fibrosis at the proximal (prostatic) end of the urethra is then removed layer by layer with curved scissors until the open, healthy urethra was reached. In the 4 BPH-cases in which a bladder neck stricture was present, a resectoscope was introduced in the prostatic urethra and the bladder neck incised. In the 3 radiotherapy or brachytherapy cases, the apex of the prostate was partially resected during this procedure. A spatulated end-to-end anastomosis was made with 8 interrupted polyglycolic sutures 3x0 sutures between the prostatic urethra and the proximal bulbar urethra. In cases of a rather short defect, mobilization of the urethra up to the penoscrotal angle was sufficient to elongate the urethra by its elasticity to bridge the gap without any tension. Cleavage of the corporal bodies was performed to gain extra length in 2 (radiotherapy) cases. A urethral catheter (18F) was left indwelling for two weeks. After this period, a voiding cysto-urethrography was performed. In cases of extravasation at the anastomosis-site, the catheter was reinserted and a new voiding cysto-urethrography was carried-out one week later. The catheter was maintained until extravasation was no longer visible. Extensive description of the technique has been previously described (8).

Follow-up with history taking, clinical examination, uroflowmetry and echographic residual urine measurement was done every three months during the first year and annually thereafter. In cases of suspected recurrence, a retrograde urethrography and cystoscopy was done.

Success was defined as spontaneous voiding, no significant residual urine and no complaints after one single reconstructive procedure. Incontinence was defined as the need of at least one protection pad a day.

## RESULTS

Mean follow-up was 31 months (range: 12-72 months). Mean stricture length was 2.1 cm

(range: 1.5-3 cm). Mean operation time was 130 min (range: 110-145 min). Two weeks after urethroplasty, voiding cysto-urethrography showed a patent urethra without extravasation in all BPH cases (4/4) and one radiotherapy patient (1/3). In the remaining 2 irradiated patients, the catheter was left indwelling for 3 and 6 weeks respectively due to persistent extravasation at the anastomosis. After final removal of the urethral catheter, all patients could urinate well. Three BPH-patients (3/4) have remained excellent until present. One BPH-patient developed a short recurrence 3 months after the operation at the level of the anastomosis and at the bladder neck. This was treated by endoscopic incision and solved the problem, for up to 23 months. The patient suffered from slight stress incontinence after the endoscopic procedure but remains very pleased with the final result.

The patient who was irradiated externally developed a stricture of 3 cm length at the bulbar urethra 6 months after urethroplasty. He was treated by a first stage Johansson procedure. Four years later, the patient is still voiding well through his perineostomy and for this reason he has refused the second stage of a Johansson procedure.

The two patients who received brachytherapy have a suboptimal urinary flow ( $Q_{max}$  of only 10 mL/sec) but are very pleased with their results. One patient also suffered from slight stress incontinence.

Summarizing these results, success- and continence-rates are 71.4% (5/7). Currently, all patients have no suprapubic catheter.

## COMMENTS

Although the urological department of the Ghent University Hospital has been a reference centre in the BENELUX (Belgium, the Netherlands and Luxembourg) for urethral stricture repair since 1980, our first case of non-traumatic posterior urethral stricture was only seen in 2001. This illustrates the rarity of the need for urethroplasty for this disease. A recent study regarding the incidence of urethral strictures after interventions for curative treatment of prostatic cancer has demonstrated that the incidence is perhaps much higher but the extent of the stricture is such that

it can be managed either with endoscopic incision or even without further treatment (7).


### Strictures after Prostate Operation for BPH

Our initial experience has shown us that after prostatectomy/TURP for BPH the prostatic urethra itself is still partially patent with the bladder neck and membranous urethra completely obstructed. Therefore, these strictures cannot be placed into the classification proposed by Pansodoro and Emiliozzi (6). These authors propose a trial of endoscopic incision of iatrogenic prostatic urethral strictures with reasonable results, but in all of their patients the prostatic urethra was narrowed, but not completely obstructed (6). Reports of endoscopic treatment of complete obliteration of the posterior urethra are very scarce and show disappointing results (9). Endoscopic treatment of these obstructions had been tried in all patients, without any success. In view of the complete obstruction, it seems to us that endoscopic treatment is not a good option in these patients (10). In patient 3, the prostatic urethra was open for only about 1 cm with a dense and long fibrosis also at the bladder neck. This patient also did worse after our reconstruction. He had a recurrent stricture at the membranous urethra

and the bladder neck, which needed an endoscopic incision. Our hypothesis of posterior urethral stricture formation was similar in all these 4 patients. They had an overdistended bladder before prostatectomy/TURP and could not urinate at removal of the urethral catheter after the intervention. A suprapubic catheter was placed to give them the opportunity to try micturition and guarantee emptying of the bladder. In all patients spontaneous micturition remained absent during at least two weeks.

However, immediately after prostatectomy/TURP the wound edges at the bladder neck and membranous urethra must form new urethral mucosa to cover the operated prostatic urethra. With spontaneous micturition, blood clots and fibrin are washed away after operation. It is our hypothesis that during a prolonged period of post-operative absent micturition, the accumulation of blood clots and fibrin at the wound edges leads to fibrosis and finally stricture formation at the bladder neck and membranous urethra with an open prostatic urethra between them, because the lumen is much larger at this level (Figure-2). Probably, it would have been better to leave the urethral catheter indwelling for a few weeks instead of a suprapubic catheter or to perform intermittent self-catheterization. Unfortunately, we have no histological or urodynamic

**A**



**B**



**Figure 2** – Proposed pathogenesis for strictures at the bladder neck and membranous urethra. A) Immediate postoperative situation after TURP. B) Accumulation of fibrin and blood clots at the bladder neck and membranous urethra finally leading to stricture formation.

data to prove this hypothesis, therefore the hypothesis can only be considered as an assumption. Pansadoro and Emiliozzi (6) have proposed a somewhat different pathogenesis of prostatic urethral strictures: strictures occur when delay of epithelialization is combined with overgrowth of fibrotic tissue.

It is possible that transurethral ultrasound can demonstrate the open prostatic urethra. This examination was not performed because we realized this possibility only after the experience.

### Strictures after Radiotherapy

In all referred patients, the prostatic urethra was only partially obstructed and the bladder neck was found to be patent. The operative challenge was not greater than in any other end-to-end anastomosis in that region, for example for urethral rupture after pelvic trauma. The intervention could have been done completely by the perineal route. In the cases after brachytherapy, the anastomosis was made after resection of the apex of the prostate with removal of several radioactive seeds.

Ideally, the anastomosis should be made between two well vascularized ends. This was not the case because the prostate was fibrotic as far as we could feel, probably due to vascular damage after the irradiation (1).

The anastomosis was made of fibrotic prostatic tissue at one side, but by a well vascularized stump of bulbar urethra at the other side. Obviously one well vascularized side at the anastomotic site can be sufficient for wound healing, although it can take considerably longer than in the non-irradiated cases. This is suggested by the observation that two out of three radiotherapy patients needed a prolonged urethral catheter because of persistent extravasation. In these cases, the urethra was also extensively mobilized and the corpora cavernosa cleaved to shorten the distance, so that the tension free anastomosis was guaranteed.

### Continence Mechanism

It is believed that after prostatectomy or TURP continence relies only on the external sphincter (11). Anastomotic urethroplasty at the level of the

membranous urethra usually destroys the external sphincter mechanism, as observed after repair of post-traumatic posterior urethral strictures (12). Taking this into account, all BPH-patients would be expected to be incontinent after urethroplasty. In fact, all patients were continent after the anastomotic repair at the membranous urethra. The bladder neck still was able to work sufficiently, even after its incision. This was done very prudently, necessitating a re-intervention of incision in one patient. Unfortunately, he became slightly stress incontinent after the second procedure. The competence of the bladder neck can be judged on a cysto-urethrography: the bladder neck should be closed following this examination. Unfortunately, this examination was not performed routinely in all cases. Therefore, our statement remains an assumption. However, a recent paper by Whitson et al. (13) still reports a significant contribution of the external sphincter after anastomotic urethroplasty at the membranous urethra. Obviously, the final continence mechanism in these complex cases still is uncertain and a matter of debate for which further research is needed. Moreover, patients should be warned about the possibility of incontinence after the procedure.

Non-traumatic posterior urethral strictures, refractory to endoscopic treatment are often managed by techniques that abandon the urethral outlet such as a definitive suprapubic catheter or a continent stoma (14,15). Five out of seven patients in this series could void after urethroplasty and with one additional procedure, all patients arrived at a reasonable solution without need for catheterization. Two brachytherapy patients had a suboptimal uroflowmetry ( $< 10\text{mL/s}$ ) after the procedure without any evidence (urethrography and urethroscopy) of recurrence. This suboptimal flow can be explained by a fibrotic obstructive irradiated prostate at its entire length even if the diameter appears to be sufficient. These patients however were subjectively very satisfied with the result.

Although we are aware of the limitations of this study (small numbers, heterogenic population), our data suggest that even for these very challenging patients voiding can be made possible again with end-to-end urethroplasty and if necessary in combination with bladder neck incision.

A search on PubMed over the past 10 years revealed only one series on posterior urethral stricture

repair after radiotherapy (7). They described seven cases of posterior urethral stenosis of which three underwent an anastomotic urethroplasty and four the placement of a urethral stent. All three anastomotic repairs were successful. Urethral stents failed twice out of four repairs with urethral stenosis recurring at either end of the stent. In spite of these worse results with stents, these authors still see this as a possible choice in their therapeutic algorithm. They also described a small series of posterior urethral strictures after radical prostatectomy, which is a situation clearly different from the one where the prostate is still in place. Therefore, at date of publication, to our knowledge this is the largest reported series describing urethroplasty for non-traumatic posterior urethral strictures.

With a normal functioning bladder still in place, it is possible to directly to a continent stoma of the bladder (14,15). This option remains open after failed urethroplasty. All our patients were warned that success was far from guaranteed and eventually other interventions could be necessary to solve their problem. They all accepted the risk and considered a continent catheterizable stoma a second choice.

## CONCLUSION

Urethroplasty, using an anastomotic repair in combination with a bladder neck incision, if necessary, provides good results. This salvage urethroplasty can preserve continence in most of the cases.

This operation can be done by perineal approach alone and is not more demanding than an anastomotic repair after urethral rupture in pelvic fractures.

Nevertheless, these conclusions are based on a small number of cases and it would be dangerous to generalize about them. They can offer, however, some inspiration for colleagues with similar unusual and difficult cases.

## CONFLICT OF INTEREST

None declared.

## REFERENCES

1. Sullivan L, Williams SG, Tai KH, Foroudi F, Cleeve L, Duchesne GM: Urethral stricture following high dose rate brachytherapy for prostate cancer. *Radiother Oncol.* 2009; 91: 232-6.
2. Fonteyne V, Villeirs G, Lumen N, De Meerleer G: Urinary toxicity after high dose intensity modulated radiotherapy as primary therapy for prostate cancer. *Radiother Oncol.* 2009; 6. [Epub ahead of print]
3. Rassweiler J, Teber D, Kuntz R, Hofmann R: Complications of transurethral resection of the prostate (TURP)--incidence, management, and prevention. *Eur Urol.* 2006; 50: 969-79; discussion 980.
4. Varkarakis I, Kyriakakis Z, Delis A, Protogerou V, Deliveliotis C: Long-term results of open transvesical prostatectomy from a contemporary series of patients. *Urology.* 2004; 64: 306-10.
5. Santucci RA, McAninch JW: Urethral reconstruction of strictures resulting from treatment of benign prostatic hypertrophy and prostate cancer. *Urol Clin North Am.* 2002; 29: 417-27.
6. Pansadoro V, Emiliozzi P: Iatrogenic prostatic urethral strictures: classification and endoscopic treatment. *Urology.* 1999; 53: 784-9.
7. Elliott SP, McAninch JW, Chi T, Doyle SM, Master VA: Management of severe urethral complications of prostate cancer therapy. *J Urol.* 2006; 176: 2508-13.
8. Oosterlinck W, Lumen N, Van Cauwenberghe G: Surgical treatment of urethral stenoses: technical aspects. *Ann Urol (Paris).* 2007; 41: 173-207.
9. Neikov K, Panchev P, Kirilov S: Endoscopic treatment of complete obliteration of posterior urethra. *Khirurgiia (Sofia).* 2001; 57: 38-40.
10. Oosterlinck W, Lumen N: Endoscopic treatment of urethral strictures. *Ann Urol (Paris).* 2006; 40: 255-66.
11. Strasser H, Frauscher F, Helweg G, Colleselli K, Reissigl A, Bartsch G: Transurethral ultrasound: evaluation of anatomy and function of the rhabdosphincter of the male urethra. *J Urol.* 1998; 159: 100-4; discussion 104-5.
12. Koraitim MM, Atta MA, Fattah GA, Ismail HR: Mechanism of continence after repair of post-traumatic posterior urethral strictures. *Urology.* 2003; 61: 287-90.
13. Whitson JM, McAninch JW, Tanagho EA, Metro MJ, Rahman NU: Mechanism of continence after repair of posterior urethral disruption: evidence of rhabdosphincter activity. *J Urol.* 2008; 179: 1035-9.

14. Moreira SG Jr, Seigne JD, Ordorica RC, Marcet J, Pow-Sang JM, Lockhart JL: Devastating complications after brachytherapy in the treatment of prostate adenocarcinoma. *BJU Int.* 2004; 93: 31-5.
15. Ullrich NF, Wessells H: A technique of bladder neck closure combining prostatectomy and intestinal interposition for unsalvageable urethral disease. *J Urol.* 2002; 167: 634-6.

---

*Accepted after revision:  
May 18, 2009*

---

**Correspondence address:**

Dr. N. Lumen  
Department of Urology  
Ghent University Hospital  
De Pintelaan 185  
9000, Ghent, Belgium  
E-mail: nicolaas.lumen@ugent.be