



# Umbilical KeyPort bilateral laparoscopic orchiectomy in patient with complete androgen insensitivity syndrome

Felipe P. Andrade, Pedro M. Cabrera, Felipe Cáceres, Belen Gil, José M. Rodríguez-Barbero, Javier C. Angulo

*Servicios de Urología, Genética y Anatomía Patológica, Hospital Universitario de Getafe, Fundación para la Investigación Biomédica del Hospital Universitario de Getafe, Universidad Europea de Madrid, Spain*

## ABSTRACT

**Main Findings:** A 22-year-old woman with complete androgen insensitivity syndrome (CAIS) presenting with primary amenorrhea and normal female external genitalia was referred for laparoscopic gonadectomy. She had been diagnosed several years earlier but was reluctant to undergo surgery.

**Case Hypothesis:** Diagnosis of this X-linked recessive inherited syndrome characterizes by disturbance of virilization in males with an AR mutation, XY karyotype, female genitalia and severely undescended testis with risk of malignization. The optimal time to orchidectomy is not settled; neither the real risk of malignancy in these patients. Early surgery impacts development of a complete female phenotype, with enlargement of the breasts. Based on modern diagnostic imaging using DCE-MRI and surgical technology with single port laparoscopic access we hypothesize that the optimum time for gonadectomy is not at the time of diagnosis, but once feminization has completed.

**Promising Future Implications:** An umbilical laparoendoscopic single-site access for bilateral gonadectomy appears to be the first choice approach as leaves no visible incision and diminishes the psychological impact of surgery in a patient with CAIS absolutely reassured as female. KeyPort, a single port access with duo-rotate instruments developed by Richard Wolf facilitates this surgery and allows excellent cosmetic results.

## ARTICLE INFO

### Key words:

Androgen-Insensitivity Syndrome; Magnetic Resonance Imaging; Neoplasms, Germ Cell and Embryonal; Sertoli Cell Tumor; Leydig Cell Tumor; Testis

**Int Braz J Urol. 2012; 38: 695-700**

Submitted for publication:  
April 24, 2012

Accepted after revision:  
July 27, 2012

## INTRODUCTION

Most of the patients with disorders of sexual differentiation are diagnosed on the basis of cytogenetic and biochemical tests. Patients with complete androgen insensitivity syndrome (AIS) are raised as females because they have female external genitalia. At puberty, following LH response, normal androgen amounts produced by the testis are aromatized to estrogens, thus leading to breast development (1). Untreated patients are often tall phenotypic females with well-formed breasts, scarce pubic and axillary hair and shallow vagina that consult due to primary

amenorrhea. Bilateral cryptorchidic testis, usually intra-abdominal, and absent wolffian and müllerian duct derivatives complete the clinical picture of this type of female pseudohermaphroditism also known as testicular feminization. Incomplete or partial AIS is possible in phenotypic males or in patients with ambiguous genitalia.

The pathogenetical basis of testicular feminization is androgen insensitivity, not androgen absence. Testosterone and DHT levels are normal or elevated, but unable to stimulate development of wolffian duct system and male external genitalia, due to mutations in AR gene that occur at Xq11-q12 (2). Most often absence of menarche,

sometimes consulted at the time of infertility work-up, initiates investigation. Female siblings of a patient diagnosed of AIS follow genetic counseling of this X-linked recessive disorder that often leads to an earlier diagnosis. This entity may also be discovered by the finding and biopsy of cryptorchidic testicles in infants or children with bilateral inguinal hernias. Very rarely this syndrome presents as a pelvic mass since germ cell malignancy before puberty is exceptional. On the other hand, it is accepted that 30% of untreated patients develop germ cell malignancy by the age of 50 years (3). Early laparoscopic gonadectomy with subsequent estrogen replacement is the current management of these patients.

However, the optimal timing of gonadectomy is not completely defined. When diagnosis is made before puberty there is not firm consensus upon the moment at which testis should be removed. Some authors strongly encourage the tendency to perform early orchiectomy right after diagnosis of testicular feminization and use estrogen replacement therapy straightforward (4,5). In children operated estrogen replacement with ethinyloestradiol is needed around the age of 11 on to rise normal female puberal development. Despite absence of uterus, combined estrogen-progesterone treatment in a cyclic fashion may diminish risk of breast cancer and cardiovascular disease associated with un-opposed estrogens (5).

Women with CAIS are increasingly likely to defer or decline orchiectomy (6). The most common reasons for bad acceptance of surgery include inconvenience, psychological impact, concern about the risks of surgery and reluctance to take hormone replacement therapy (6). It is understandable then that some specialists consider the optimum time for gonadectomy is not at the time of diagnosis, but once feminization has completed. After puberty, estrogen replacement in selected cases can be delivered through transdermal patches. Genetic and endocrine counseling need psychological reinforcement.

### CASE HYPOTHESIS AND RATIONAL

A single 22 years-old phenotypically female Arabic had been diagnosed of complete AIS

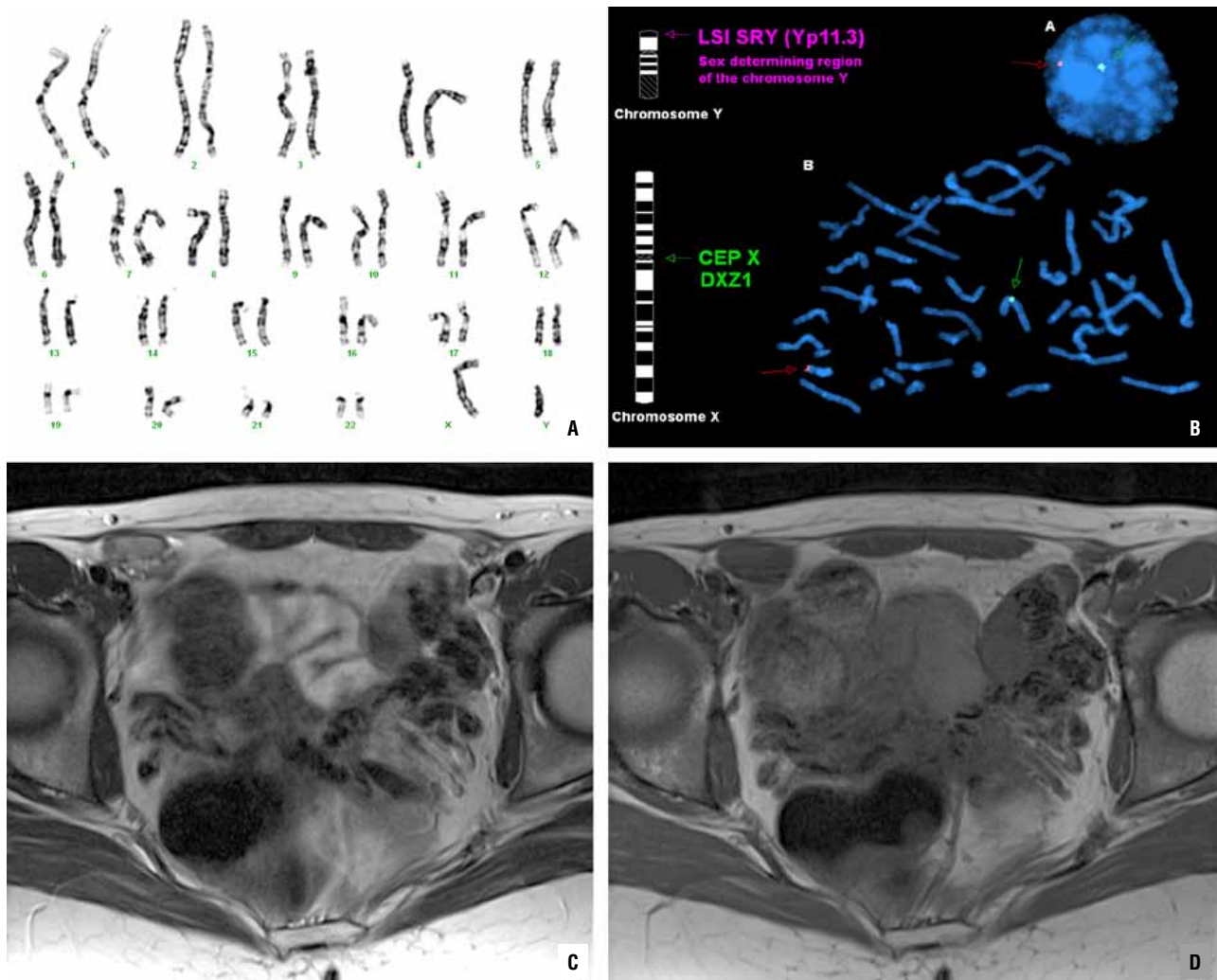
4 years earlier when she consulted due to primary amenorrhea but was reluctant to undergo surgery and refused it. She was referred to our institution for psychological counseling and to evaluate the risks and benefits of receiving bilateral orchiectomy through the umbilicus with the new KeyPort™ system (Richard Wolf, Knittingen, Germany).

Hormonal evaluation performed showed normal testosterone (6.4 ng/ml), LH (14.2 mIU/ml) and FSH (6.6 mIU/ml) levels and elevated  $\beta$ -HCG (2.8 mg/ml). Chromosomal study revealed a normal male 46-XY karyotype. FISH was performed using Vysis Probe (Izasa) that revealed the presence of the SRY gene on the short arm of the Y chromosome (Yp11.3) and also the presence of AR gene on the X chromosome (Xq11-12) (Figure-1). The patient was submitted to automatic sequencing of AR gene to show the causative mutation. This genetic study has also been proposed to her mother and sisters, and is now pending.

The external genitalia appeared entirely female and pelvic ecography highlighted absence of internal genital organs and dead-end normal vagina. No sexual glands or uterus was visible on computed tomography (CT) or magnetic resonance imaging (MRI). MRI revealed pelvic (right inguinal and left paravesical) gonads of altered signal intensity (Figure-1). Apparent diffusion coefficient (ADC) map was reconstructed from diffusion-weighted images and evidenced a nodular pattern with higher ADC values in both testes suggestive of high cellular density.

The patient accepted laparoendoscopic examination of the pelvic cavity and umbilical bilateral orchiectomy assuming diminished psychological impact caused by a scar hidden inside the umbilicus. Under general anesthesia a 25 mm long incision was performed without need of augmenting the skin or aponeurotic incision to introduce the KeyPort and create the pneumoperitoneum. A long 30° 5.3 mm lens and two duorotate curved instruments, scissors and grasping forceps, combined with Eragon system (Richard Wolf) were used (Figure-2), together with Force-triad (Covidien) 5 mm hemostatic system and transparent jelly application for lubrication. Both

**Figure 1 - Preoperative work-up: Chromosomal study with 46-XY karyotype (A); FISH using Vysis Probe (Izasa) revealed SRY (Yp11.3) and AR (Xq11-12) genes (B); Pelvic gonads on MRI of altered signal on T2 TSE (C) and homogeneous contour on T1 SE (D).**

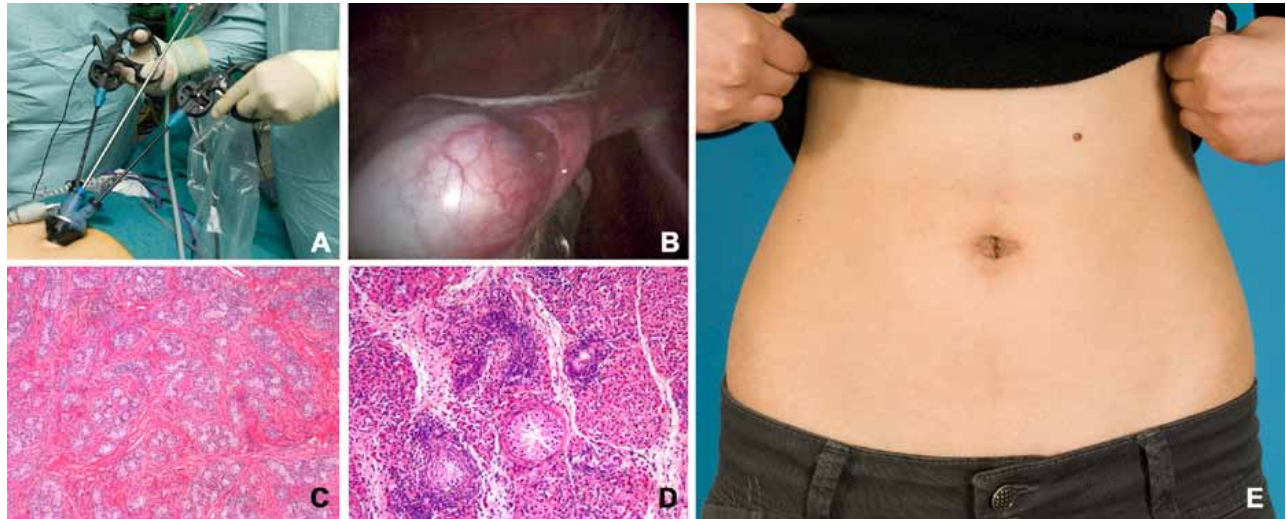


gonads were easily retracted and dissected and no inguinal hernia was evidenced. Hem-o-lok placement in the testis cord facilitated orchiectomy. The specimens were packed and extracted through the umbilicus without leaving a drain. Duration of surgery was 45 min. and bleeding was 40 cc. Postoperative recover was uneventful and the patient left hospital after 24 hours without the need of analgesics. Two weeks later the wound appeared absolutely concealed within the umbilicus (Figure-2) and the patient was very happy both with her immediate recovery to nor-

mal day-life activities and with the excellent cosmetic aspect of the incision.

Cryptorchidic testis revealed a hard consistency produced by firm, tan nodules measuring approximately 1 cm surrounded by dark brown testicular parenchyma. The nodules comprised small tubules populated by Sertoli cells, demarcated from testicular tissue with marked Leydig cell hyperplasia and a spindle-cell proliferation very similar to ovarian stroma (Figure-2). These nodules were of hamartomatous nature and histologically defined as Sertoli adenomas.

**Figure 2 - Operative and postoperative results: Umbilical KeyPort with 30o 5.3 mm lens and duo-rotate instruments (A); laparoendoscopic view of the gonad (B); hamartomatous nodule composed of small tubules filled with Sertoli cells (C); Leydig cell hyperplasia and also a spindle-cell proliferation very similar to ovarian stroma (D); absence of visible incision two weeks after surgery (E).**



Intratubular germ cells that stained positively to placental alkaline phosphatase were present inside some seminiferous tubules, thus revealing intratubular germ cell neoplasia. Three months after surgery the patient initiated estrogen replacement using transdermal patches and both genetical and molecular analysis have been proposed to all the female siblings in the family.

## DISCUSSION AND FUTURE PERSPECTIVES

Transumbilical single-port surgery has greatly evolved in the last few years in the urological literature (7). Although it is still a minority, with recent advent of new instrumentation, transumbilical laparoendoscopic single-site surgery has become more popular and the cosmetic benefit is well accepted both by physicians and patients (8).

We have proved that a great variety of laparoendoscopic surgeries can be performed through the umbilicus with the new KeyPort system (9,10). We believe this single port is specially indicated for reconstructive surgery because under these circumstances patient recovery and excellent cosmetic results are very important. Neobladder construction with orthotopic anastomosis to the urethra after cystoprostatectomy is

possibly the best example of how this new system can be used to achieve an excellent postoperative recovery (11). It is not surprising then that patient acceptance of the umbilical approach is higher than that of conventional laparoscopy and much better than open surgery to face a reconstructive procedure, because cosmetics are greatly improved. In this case no additional 3.5 mm accessory trocar was needed. However, needlescopic material can be very helpful in complicated surgeries such as partial nephrectomy, adrenalectomy or pyeloplasty.

It is well accepted that laparoscopic access is primarily indicated in intersex patients and also in the management of impalpable gonads in the normal male population (4,12). In fact, laparoscopy has been used for diagnostic biopsy of intersex patients since 1986 (13). Apart from the case here presented laparoendoscopic single site surgery to perform orchiectomy has been described in a 20-year patient to treat AIS in the Japanese literature (14). The patient we treated exemplifies that this surgery is better accepted than other conventional options to manage these complex patients that often need psychological and sociological reassurance.

Of course there is a risk of developing germ cell tumors in the testis of patients with



AIS. However accurate estimate risk of adult malignancy is not really available. With the limitations of combining historic case series, it has been recently estimated that 14% (0-22%) of untreated adults with complete AIS (6) could develop germ cell malignancy. That means the risks often quoted may have been exaggerated.

Modern diagnostic imaging using MRI and particularly DCE-MRI allows a better definition of the structure of the gonads that may justify a delayed biopsy or excision as far as there is no suspicion of malignancy (15). Delayed orchiectomy allows a better development of female characters at puberty, thus resulting in a better acceptance of the patient's condition. We therefore believe that laparoscopic access through umbilical single port is the best option to plan bilateral gonadectomy in these patients because no visible incision is left and this fact minimizes the psychological impact of surgery. The most appropriate time to perform it is after the patient has been reassured as a female with infertility alone. KeyPort system, the single port access with duo-rotate instruments developed by Richard Wolf facilitates this surgery, allows excellent cosmetic results and can be used safely after sufficient practice both in dry lab and experimental animals (9).

## ACKNOWLEDGEMENTS

The authors thank Dr. Antonio Gómez for patient referral and Mr. Jesús Arconada (Grupo Taper, Madrid), Mr. Stefan Gillé, Mr. Benjamin Seidenspinner and Mr. Juergen Steinbeck (Richard Wolf GMBH, Knittlingen) for providing instrument prototypes and constant support, and José Dominguez for photographic assistance.

## CONFLICT OF INTEREST

None declared.

## REFERENCES

1. Gottlieb B, Pinsky L, Beitel LK, Trifiro M: Androgen insensitivity. *Am J Med Genet.* 1999; 89: 210-7.
2. Brinkmann AO: Molecular basis of androgen insensitivity. *Mol Cell Endocrinol.* 2001; 179: 105-9.
3. Levin SH: Non-neoplastic diseases of the testis. In: *Genitourinary Pathology (A volume in the foundations in diagnostic pathology series, Series Edited by John R. Goldblum)*. Eds. M Zhou and C Magi-Galluzzi. Churchill Livingstone. Philadelphia, 2007; p. 477-533.
4. Gad El-Moula M, Izaki H, El-Anany F, Abd El-Moneim A, El-Moneim El-Haggagy A, Abdelsalam Y: Laparoscopy and intersex: report of 5 cases of male pseudohermaphroditism. *J Med Invest.* 2008; 55: 147-50.
5. Kravarusic D, Segulier-Lipszyc E, Feigin E, Nimri R, Nagelberg N, Freud E: Androgen insensitivity syndrome: risk of malignancy and timing of surgery in a paediatric and adolescent population. *Afr J Paediatr Surg.* 2011; 8: 194-8.
6. Deans R, Creighton SM, Liao LM, Conway GS: Timing of gonadectomy in adult women with complete androgen insensitivity syndrome (CAIS): patient preferences and clinical evidence. *Clin Endocrinol (Oxf).* 2012; 76: 894-8.
7. Canes D, Desai MM, Aron M, Haber GP, Goel RK, Stein RJ: Transumbilical single-port surgery: evolution and current status. *Eur Urol.* 2008; 54: 1020-9.
8. Humphrey JE, Canes D: Transumbilical laparoendoscopic single-site surgery in urology. *Int J Urol.* 2012; 19: 416-28.
9. Cáceres F, Cabrera PM, Mateo E, Andrés G, Lista F, García-Tello A: Onset of a Training Program for Single-Port Laparoscopic Urology. *Actas Urol Esp.* 2012; 36: 418-24.
10. Cáceres F, Cabrera PM, García-Tello A, García-Mediero JM, Angulo JC: Safety Study of Umbilical Single-port Laparoscopic Radical Prostatectomy with a New DuoRotate System. *Eur Urol.* 2012; 5. [Epub ahead of print]
11. Angulo JC, Cáceres F, Arance I, Romero I, Ramón De Fata F, Cabrera PM: Laparoendoscopic Radical Cystectomy with Orthotopic Ileal Neobladder through Umbilical Single Port. *Actas Urol Esp.* 2012; 36: 554-61.
12. Chertin B, Koulikov D, Alberton J, Hadas-Halpern I, Reissman P, Farkas A: The use of laparoscopy in intersex patients. *Pediatr Surg Int.* 2006; 22: 405-8.

13. Portuondo JA, Neyro JL, Barral A, Gonzalez-Gorospe F, Benito JÁ: Management of phenotypic female patients with an XY karyotype. *J Reprod Med.* 1986; 31: 611-5.
14. Kishimoto N, Okumi M, Miyagawa Y, Yoshioka I, Sawada K, Kimura T: A case of androgen insensitivity syndrome (AIS) treated by Laparoendoscopic single site surgery (LESS). *Hinyokika Kiyo.* 2011; 57: 657-60.
15. Kantarci M, Doganay S, Yalcin A, Aksoy Y, Yilmaz-Cankaya B, Salman B: Diagnostic performance of diffusion-weighted MRI in the detection of nonpalpable undescended testes: comparison with conventional MRI and surgical findings. *AJR Am J Roentgenol.* 2010; 195: W268-73.

---

**Correspondence address:**

Dr. Javier C. Angulo  
Jefe de Servicio de Urología  
Hospital Universitario de Getafe  
Carretera de Toledo Km 12,500  
28905 Madrid, Spain  
Fax: 34-916247309  
E.mail: [jangulo@futurnet.es](mailto:jangulo@futurnet.es)