



RE: Proximal bulbar periurethral abscess

Sarah D. Blaschko, Dana A. Weiss, Anobel Y. Odisho, Kirsten L. Greene, Matthew R. Cooperberg

Department of Urology, University of California San Francisco, CA, USA

Int Braz J Urol. 2013;39:137-8

To the editor,

We read the article by Dr. Blaschko et al. with interest (1). They reported a 67 year-old diabetic male with persistent leukocytosis despite appropriate antibiotic treatment for pneumonia. After computed tomography (CT) evaluation, a 3.5 centimeter rim enhancing fluid collection at the level of his bulbar urethra was noticed. In the next step, under the guidance of transrectal ultrasonography, they performed transrectal ultrasound-guided needle aspiration and, pus was aspirated from the lesion. The abscess fluid culture was negative. Accordingly, we presented a 63-year-old male admitted with the complaints of dysuria, difficulty in urination, pain and hyperemia in ventral side of the penile shaft for 3 months. One month later, his complaints were increased and he consulted an urologist. Under local anesthesia, the urologist treated the patient by small penile shaft incision and drained pus. As in the case reported by Dr. Blaschko et al., our patient completed a two-week antibiotic course per infectious disease recommendations. The abscess culture was also negative in our case. However, during follow-up, the complaints did not resolve. We decided to re-operate the patient. We incised the skin and obtained a biopsy from the floor of the abscess cavity. Histopathological examination showed moderately differentiated squamous cell carcinoma (SCC). The patient was a heavy smoker and circumcised at the age of 7 years. There was no previous history of genital warts and urethral discharge. During last visit, on physical examination, destruction of the urethra and possible invasion into corpus spongiosum was suspected. Partial penectomy was performed (Figures 1a and b). Histopathological examination confirmed the diagnosis of SCC (moderately differentiated) with 1.8 cm tumor free resected margins. In addition, corpus spongiosum invasion was also reported. An (18)F-FDG PET/CT exploration showed hypermetabolic lymphadenopathies in bilateral inguinal lymph nodes (SUV max=2.3). Bilateral modified radical inguinal lymphadenectomy was performed. Histopathological examination revealed reactive lymph nodes without tumoral infiltration. For today, the patient feels good without any complaints.

We think that, in suspected cases, after drainage of the abscess, the scrapings from the abscess wall or a part of any non-healing ulcer must be sent to pathological or cytological examination. In certain cases ultrasound guided biopsy can also be done. In case reported by Dr. Blaschko et al., as the patient had subsequent rapid clinical improvement after the aspiration of abscess confirmed by radiological imaging, they did not send any specimen for cytological or histological examination. But, we must keep in mind that, resistant abscess formations or non-healing ulcers especially in genital regions should be evaluated for neoplasia. Because, as we see in our case, SCC can masquerade as a periurethral abscess.

Another important point we need to mention is about the etiologic factors related to SCC of penis. As we all know, the risk factors for developing SCC on the penis include lack of circumcision,

Figure 1a - During partial penectomy, after degloving of the penis inner wall of the previously drained periurethral abscess was exposed (arrowhead).

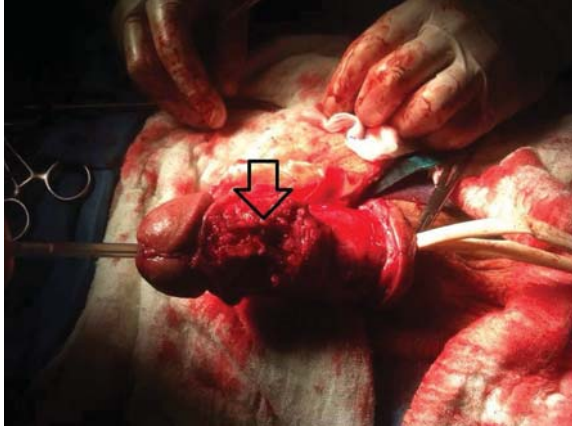


Figure 1b - Appearance of the penis 2 days after the operation.



HPV infection, chronic balanitis, smoking and phimosis. The only risk factor documented in our patient was cigarette smoking. So, smoking may have a greater impact on the development of penile SCC in populations ritual circumcision in early childhood period is common as in our country.

REFERENCES

1. Blaschko SD, Weiss DA, Odisho AY, Greene KL, Cooperberg MR. Proximal bulbar periurethral abscess. *Int Braz J Urol.* 2013;39:137-8.

*Husnu Tokgoz, MD; Ilkay Soyuncu, MD;
Soner Yalcinkaya, MD; Ozlem Tokgoz, MD;
Murat Savas, MD
Department of Urology,
Antalya Research and Training Hospital
Konyaalti, Antalya 07070, Turkey*