



New head-mounted display system applied to endoscopic management of upper urinary tract carcinomas

Junichiro Ishioka¹, Kazunori Kihara¹, Saori Higuchi¹, Takayuki Nakayama¹, Hideki Takeshita¹, Soichiro Yoshida¹, Yasukazu Nakanishi¹, Toshiki Kijima¹, Yoh Matsuoka¹, Noboru Numao¹, Kazutaka Saito¹, Yasuhisa Fujii¹

¹Department of Urology, Tokyo Medical and Dental University Graduate School, 1-5-45, Yushima, Bunkyo-ku, Tokyo, Japan

ABSTRACT

Purpose: We tested a new head-mounted display (HMD) system for surgery on the upper urinary tract.

Surgical Technique: Four women and one man with abnormal findings in the renal pelvis on computed tomography and magnetic resonance imaging underwent surgery using this new system. A high definition HMD (Sony, Tokyo, Japan) is connected to a flexible ureteroscope (Olympus, Tokyo, Japan) and the images from the ureteroscope are delivered simultaneously to various participants wearing HMDs. Furthermore, various information in addition to that available through the endoscope, such as the narrow band image, the fluoroscope, input from a video camera mounted on the lead surgeon's HMD and the vital monitors can be viewed on each HMD.

Results: Median operative duration and anesthesia time were 53 and 111 minutes, respectively. The ureteroscopic procedures were successfully performed in all cases. There were no notable negative outcomes or incidents (Clavien-Dindo grade ≥ 1).

Conclusion: The HMD system offers simultaneous, high-quality magnified imagery in front of the eyes, regardless of head position, to those participating in the endoscopic procedures. This affordable display system also provides various forms of information related to examinations and operations while allowing direct vision and navigated vision.

ARTICLE INFO

Key words:

Urinary Tract; Ureteroscopy; Natural Orifice Endoscopic Surgery; Video-Assisted Surgery

Int Braz J Urol. 2014; 40: 842-5

Submitted for publication:
January 21, 2014

Accepted after revision:
April 06, 2014

INTRODUCTION

With the development of excellent smaller and flexible ureteroscopes, the ureteroscopic management of the upper urinary tract (UUT) and upper urinary tract urothelial carcinomas (UUTUC) has become more practical, and indications for such procedures have expanded from those patients with solitary kidney or renal insufficiency to patients with normal contralateral kidney (1). In order to make ureteros-

copy more feasible and effective, we applied a novel head-mounted display (HMD) system that displays simultaneous, high-quality magnified imagery in front of the eyes, regardless of head position, to those participating in endoscopic procedures. This affordable display system also provides various forms of information related to examinations and operations while allows direct vision and navigated vision. In this study, we describe an application of the system in UUT examinations.

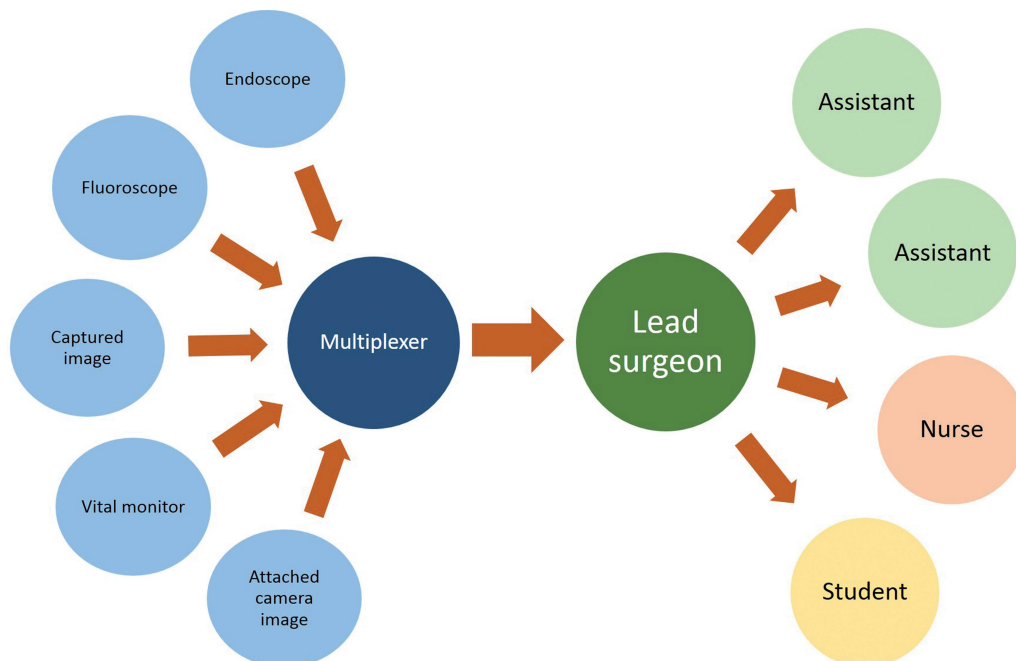
SURGICAL TECHNIQUE

Four women and one man with abnormal findings in the renal pelvis on computed tomography (CT) and magnetic resonance imaging (MRI) underwent surgery using this new system. Each patient had irregular images in the renal pelvis on CT and low T2-weighted signals and diffuse high-intensity signals on diffusion-weighted MRI imaging, leading to suspicion of urothelial carcinoma of the renal pelvis. For further evaluation, ureteroscopy and, if possible, biopsy of the abnormal urothelium tissue with reference to the narrow band image (NBI) was performed. The patients gave written informed consent to participate in a clinical trial to the institutional investigational review board of our institution.

The system presented here is used as follows (Figure-1). A high definition HMD (Sony, Tokyo, Japan) is connected to a flexible ureteroscope (Olympus, Tokyo, Japan) and the images from the ureteroscope are delivered simultaneously to various participants wearing HMDs. This monitor is fitted with 0.7-inch (18.0mm diagonal) Or-

ganic Light-Emitting Diode panels with displayed pixel count of 1280x720. The device is already commercially available in Japan and Europe. Its purchase costs are €12300. Furthermore, the devices have four different input-output terminals, including Digital Video Interface and Serial Digital Interface. Various informations in addition to that available through the endoscope, such as the NBI, the fluoroscope, input from a video camera mounted on the HMD and the vital monitors can be viewed on each head-mounted display (Figure-2A). Technical support was provided by the Sony Corporation. Two urologists (one lead surgeon and one assistant) performed the operation. Both the lead surgeon and the assistant each wore an HMD throughout the procedure. The imaging information obtained from the ureteroscope, captured narrow band image (NBI), images from the video camera attached to the HMD of the lead surgeon, and the patient's vital signs monitor are split using an imaging splitter (400-VGA003, Sanwa Supply Incorporated, Okayama, Japan) and the composite image is outputted into two multiplexers (VPM-H1, MEDIAEDGE Corporation, Hyogo, Japan).

Figure 1 - A schematic view of the head-mounted display (HMD) and personally integrated monitoring system. Multiple input information is split using an imaging splitter and integrated into one composite image using a multiplexer. Each wearer of an HMD can independently arrange the array of the displayed images.



The images are integrated using a four-split screen technique on the multiplexer and are displayed on the HMDs (Figure-2B). The lead surgeon usually opts to arrange the ureteroscopic view as the main image displayed by the HMD during the observation and biopsy, and the assistant may choose the fluoroscopic view as the main image.

Median operative duration and anesthesia time were 53 and 111 minutes, respectively. The ureteroscopic procedure was successfully performed in all cases. Tumor biopsy was performed with a 3F cup biopsy forceps for flat or sessile lesions. There were no notable negative outcomes or incidents in the postoperative courses (Clavien-Dindo grade ≥ 1) of any patients (Table-1). During the procedures, neither the lead surgeon nor the

assistant surgeon experienced any HMD-related adverse effects no reported any discomfort. Of all the patients, 3 patients were diagnosed as having urothelial carcinoma and subsequently treated with radical nephroureterectomy.

COMMENTS

This is the first study to use the HMD system in ureteroscopy and we safely completed the procedures in a reasonable time by using the features of HMD system. There were no intra-operative or postoperative complications.

Traditionally, nephroureterectomy has been the treatment of choice for UUTUC. As population of the elderly increases, the number of

Figure 2 - Photograph of ureteroscopy being performed using the head-mounted display (HMD) system. Both the lead surgeon and the assistant wear an HMD during all stages of the procedure (A). Captured images of the integrated image data include an ureteroscopic image, a fluoroscopic image, the patient’s vital signs, and the view from a camera attached to the HMD worn by the lead surgeon (B).

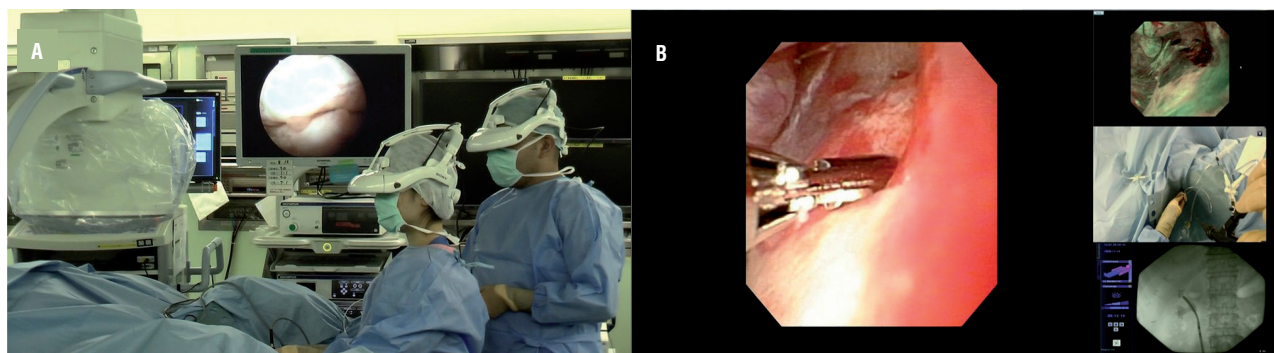


Table 1 – Patients’ clinical data and outcomes.

Age	Gender	Lesion	ASA score (min.)	Operative duration (min.)	Duration of anesthesia	Clavien-Dindo grade ≥ 1	Pathological diagnosis	Subsequent treatment
62	Female	Right RP	2	73	139	none	UC, G2	NU
45	Female	Left RP	1	19	43	none	no malignancy	observation
69	Female	Right RP	1	62	136	none	no malignancy	observation
79	Female	Right RP	1	50	120	none	UC, G2	NU
76	Male	Right RP	2	63	117	none	UC, G1	NU

RP = Renal Pelvis; ASA = American Society of Anesthesiologists; UC = urothelial carcinoma; NU = nephroureterectomy

patients with a decreased estimated glomerular filtration rate (ill compromised contralateral kidney, solitary kidney) increase, and the importance of endoscopic management is also increasing (1). Furthermore, the indications for endoscopic management have expanded to include those patients without significant renal parenchymal disease or comorbidities, and specifically those with a normal contralateral kidney as well as imperative cases (2).

Although retrograde endoscopic procedures have become more practical and efficacious with the development of new endoscopic tools, ureteroscopy is still troublesome because the procedure usually requires a variety of information from different screens. To offer better endoscopic management of UUT, we have tested a new HMD system, which we had already applied to minimally invasive endoscopic surgery (3). The HMD system has five visual functions: magnified vision, panoramic vision, multiple vision, shared vision, and navigated vision. The magnified view of the endoscopic image can be displayed in front of the user's eyes. We have not experienced serious malfunction events during the procedure because the HMD also allows direct vision without the need to remove the headset. When the user looks downward, direct unimpeded vision is possible. Multiple and shared vision can be provided by using a signal changer. The HMD can display multiple informations from several imaging sources, and this can also be delivered to many participants simultaneously (4). Navigation with composite images, such as fluoroscopic images and NBI images, make it easier for surgeons to perform various procedures.

The present study has several limitations, including the small sample, the lack of control group and the lack of cost analysis. There is still a lot to be done in order to demonstrate the actual advantages in terms of oncological outcomes and cost-effectiveness. We think that much larger cohorts and longer follow-up would be needed.

In conclusion, the HMD system can be safely applied to ureteroscopy. The HMD system offers simultaneous, high-quality magnified imagery in front of the eyes, regardless of head position, to those participating in endoscopic procedures. This affordable display system also provides various forms of information related to examinations and operations while allowing direct vision and navigated vision.

CONFLICT OF INTEREST

Dr. Kihara has received research funding from Sony Corporation (Tokyo, Japan), but the sponsor had no control over the interpretation, writing, or publication of this work.

REFERENCES

1. Cutress ML, Stewart GD, Zakikhani P, Phipps S, Thomas BG, Tolley DA. Ureteroscopic and percutaneous management of upper tract urothelial carcinoma (UTUC): systematic review. *BJU Int.* 2012; 110: 614-28.
2. Coresh J, Selvin E, Stevens LA, Manzi J, Kusek JW, Eggers P, et al. Prevalence of chronic kidney disease in the United States. *JAMA.* 2007; 298: 2038-47.
3. Kihara K, Fujii Y, Masuda H, Saito K, Koga F, Matsuoka Y, et al. New three-dimensional head-mounted display system, TMDU-S-3D system, for minimally invasive surgery application: procedures for gasless single-port radical nephrectomy. *Int J Urol.* 2012; 19: 886-9; author reply 890.
4. Yoshida S, Kihara K, Takeshita H, Nakanishi Y, Kijima T, Ishioka J, et al. Head-Mounted Display for Personal Integrated-Image Monitoring System: Ureteral Stent Placement. *Urol Int.* 2014. [Epub ahead of print]

Correspondence address:

Kazunori Kihara, MD
 Department of Urology
 Tokyo Medical and Dental University Graduate School
 1-5-45, Yushima, Bunkyo-ku, Tokyo, Japan
 Fax: +81 3 5803-5295
 E-mail: k-kihara.uro@tmd.ac.jp