

EFFECTS OF HIGH-ENERGY SHOCK WAVE ON ORGANS ADJACENT TO THE KIDNEY IN THE GROWING RAT

AGUINALDO C. NARDI, UBIRAJARA FERREIRA, JOAQUIM A. CLARO, GUSTAVO M. STOPIGLIA, N. RODRIGUES NETTO JR.

Discipline of Urology, Department of Surgery, School of Medicine, State University of Campinas, UNICAMP, Campinas, SP

ABSTRACT

Objective: To assess the effects of high-energy shock waves (HESW) on organs adjacent to the kidney, in the growing rat.

Materials and Methods: We studied 60 Wistar male rats. Upon completing 30 days of age, a radiopaque marker was placed in the animals' left renal cavity. With 40 days of age, after radiologically confirming the markers' position, the rats were divided into 2 groups: control-group – 30 rats that did not receive shock waves; experimental group– 30 rats exposed to 1000 shock waves of 17.2 KV in intensity. The rats were sacrificed 7, 90 and 180 days after exposure to HESW. The bodily growth was assessed and the analysis of macro- and microscopic morphology of liver, spleen, pancreas, lungs and adrenals.

Results: There was no statistical difference in the animals' bodily growth. The microscopic morphologic analysis demonstrated significant alterations in spleen (proliferative changes in the red pulp) and liver (cloudy swelling) of the animals submitted to HESW and sacrificed on the seventh day. These changes completely disappeared in subsequent analyses.

Conclusion: HESW applied to rat did not inhibit the animals' growth and caused transitory histological lesion in spleen (proliferative changes in the red pulp) and in liver (cloudy swelling of hepatocytes). Such changes were observed only in the group that was exposed to HESW and was sacrificed 7 days following the experiment, presenting spontaneous recovery.

Key words: kidney; high-energy shock waves; rats; spleen; liver

Int Braz J Urol. 2004; 30: 142-147

INTRODUCTION

Extracorporeal shock wave lithotripsy (ESWL) is a safe and effective method for treating renal lithiasis. However, there are still doubts about its effects over growing tissues. Though extracorporeal lithotripsy is a standard treatment for lithiasis in the childhood (1-7), some data in the literature confirm the deleterious effects of ESWL such as, for example, decrease in the glomerular filtration rate and a significant delay of renal growth (8) in children who undergo ESWL. Such data suggest the need of fol-

lowing these patients over prolonged period and continuously performing experimental studies.

This study aims to assess the effects of high-energy shockwaves (HESW) on bodily growth and on organs adjacent to the kidney in male rats.

MATERIALS AND METHODS

A total of 60 male rats ("Ratus Norvegicus", variety "Albinus", originally from Wistar race) were used. The animals were kept in proper cages, with a number of 5 rats per cage. Feeding consisted of ra-

tion and water "ad libitum". We used room temperature, with non-programmed humidity and light control alternating 12 hours in dark and 12 hours in light.

Animals were anesthetized through inhalation of ethylic ether in a proper campanula, during all manipulation periods: surgical period (insertion of radiopaque marker), during exposure to HESW and for performing the sacrifice.

With 30 days of life, an incision was performed on right flank for peritoneal approach, through clean, but not sterile, technique. The left kidney was exposed and renal cavity was marked by a rubber wire coated with barium sulphate.

With 40 days of life, animals were divided into 2 groups with 30 animals each: control group and animals that would be exposed to shock waves. The animals were then sacrificed 7, 90 and 180 days following the exposure to HESW.

One day before the experiment, a plain radiography was performed for all animals, in order to confirm the location of the radiopaque marker. The lithotripter used was the Lithostar-Siemens. This equipment has an electromagnetic shock wave generator that produces a tension ranging from 200 to 380 bar, depending on the voltage used (13 to 19 KV). In this study, we used a voltage of 17.2 KV, performing 1000 shock wave impulses, with equipment's tension focus of approximately 11 mm x 90 mm and a focal distance of 113 mm. The only modification required for applying shock waves to the rat, was the placement of a water bag between the wave generator and the animal in order to allow adjustment of the focal area over the radiopaque marker inserted in the animal's renal cavity.

The following organs were morphologically studied: right and left lungs, spleen, liver, pancreas, right adrenal and left adrenal. Sacrifice was performed with inhalatory anesthesia and through median thoraco-abdominal incision. The organs were cleaned and photographed, and then fixed in formalin. The employed staining was hematoxylin-eosin.

In order to compare the weight of rats from the control and experimental groups, the Student's "t" test was used and a significance level of 5% was adopted. The Fisher's test was used for statistical analysis of the histopathologic results.

RESULTS

In relation to bodily growth, there was no significant difference between animals exposed to HESW and those from the control group.

After opening the abdominal cavity, the radiopaque marker's location was checked, confirming its adherence to the renal cavity in all rats. There was no sign of renal or peri-renal hematoma, neither renal scarring. The inspection of the abdominal cavity did not reveal any hemorrhagic area and all organs presented normal color and surface, with no signs of trauma, scars or contusions.

The histological alterations observed in the organs examined occurred only in the group that was assessed 7 days after exposure, involving spleen and liver (Table-1).

In the majority of rats from the control group that were sacrificed on the seventh day of study, the spleen showed normal histological pattern and proper for age. In rats subjected to HESW and sacrificed on the seventh day, the splenic architecture was preserved, but the red pulp showed a markedly higher cellularity in relation to the control group. There was an evident increase in the number of megakaryocytes, appearance of erythroblasts nests and collections of immature leukocytes. Such cellular proliferation in the red pulp was designated as proliferative changes of red pulp (PCRP), occurring uniformly in all rats from the experimental group on the seventh day and in only one rat from the control group, in the same period (Figures-1 and 2).

In liver's histological sections, in all rats of the experimental group, on the seventh day, and in 4 rats from the control group during the same period, a generalized volumetric increase was verified in the hepatocytes, where the cytoplasm was clearer and more distinguished from basophilic organelles, characterizing the condition described as "cloudy swelling" of hepatocytes (Figures-3 and 4). There was no inflammatory infiltrate, reticuloendothelial proliferation, hemorrhagic areas or isolated necrosis.

Still during the 7-day period, a loose aspect of the septal connective tissue was observed in the lungs of 4 rats from the experimental group and in 2 from the control group, which was interpreted as sep-

EFFECTS OF SHOCK WAVE ON ORGANS ADJACENT TO THE KIDNEY

Table 1 – Histopathologic characteristics observed in rats exposed to HESW in left renal cavity and sacrificed 7 days after exposure.

Organs	Rats									
	1	2	3	4	5	6	7	8	9	10
Liver	Cloudy swelling	Cloudy swelling	Cloudy swelling	Cloudy swelling	Cloudy swelling	Cloudy swelling	Cloudy swelling	Zonal Cloudy swelling*	Cloudy swelling	Cloudy swelling
Pancreas	Normal	Normal	Normal	Normal	Normal	Normal	Normal	Normal	Normal	Normal
Spleen	PCRP**	PCRP	PCRP	PCRP	PCRP	PCRP	PCRP	PCRP	PCRP	PCRP
Right Lung	Normal	Normal	Normal	Normal	Normal	Normal	Septal Edema	Normal	Septal Edema	Normal
Left Lung	Septal Edema	Normal	Normal	Normal	Normal	Normal	Septal Edema	Septal Edema	Septal Edema	Normal
Right Adrenal	Normal	Normal	Normal	Normal	Normal	Normal	Normal	Normal	Normal	Normal
Left Adrenal	Normal	Normal	Normal	Normal	Normal	Normal	Normal	Normal	Normal	Normal

* Centrolobular Peri-veins; ** Proliferative Changes of the Red Pulp

tal edema. This alteration did not show a significant difference between the groups under study.

No circulatory, degenerative, necrotic or inflammatory alterations were detected in pancreas and adrenals, in both groups.

In the 90- and 180-day period, the examined organs maintained, in general, a normal histological pattern. The spleen, that showed significant alterations in the first period, presented normal histological pattern, showing reversibility of the changes previously described. The same occurs with the hepatic alterations that were described in the first period.

Two rats from the experimental group, at 180 days, presented some clusters of immature leukocytes in the splenic red pulp and in one rat a well-defined picture of PCRP was observed, similar to the one observed in rats from the experimental group on the seventh day.

DISCUSSION

The rat was chosen as experimental animal because it is a small animal, of easy handling, resistant

to diseases, has a low maintenance cost and especially because it has a relatively short life cycle (9).

The rat reaches adult age around 24 weeks and senility usually occurs from 2 years old on (10). Such data are fundamentally important for this study, because the analysis of results accompanies the rats' growth, since the animals were exposed to HESW during childhood and assessed throughout their development, until adult age.

The lithotripter used in this study (Lithostar) is an equipment that presents highly satisfactory results for fragmenting stone, with fragmentation indexes ranging from 80 to 95%. In children, the Lithostar allows to position the patient without technical modifications, in addition to providing a smaller shock wave exposure area, which makes ESWL safer (1). This equipment is used in several centers throughout the world.

Several animal experiments (11-13) analyzed the effects of ESWL. Studies with rats show that tissue lesions start from 500 shock waves on, and that there is no significant difference between the use of

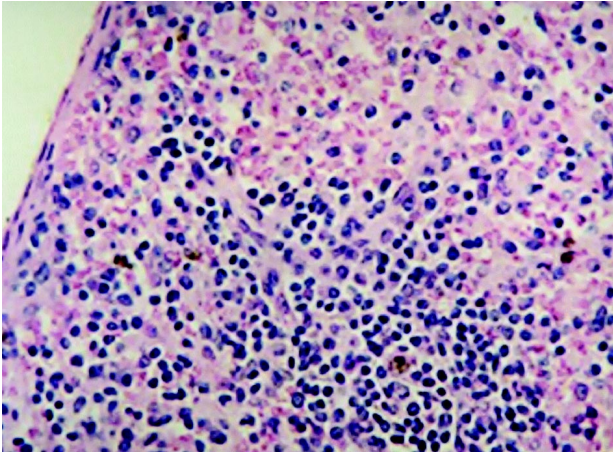


Figure 1 – Detail of splenic red pulp. Rats from the control group. Observe the scarcity of cells (HE, X160).

1000, 2000 and 3000 impulses, concerning damages to liver parenchyma (14).

In this study, the use of 1000 shock waves was preferred in order to guarantee the manifestation of potential effects, that is, using a markedly higher number than 500 impulses. The impulse intensity used in the experiment was quite high, corresponding to 350 bar.

Studies performed in rabbits (11), rats (15-16) and other animals assessed the influence of HESW over their growth, finding no significant difference between bodily and renal growth. The present study showed also that there was no change in the bodily

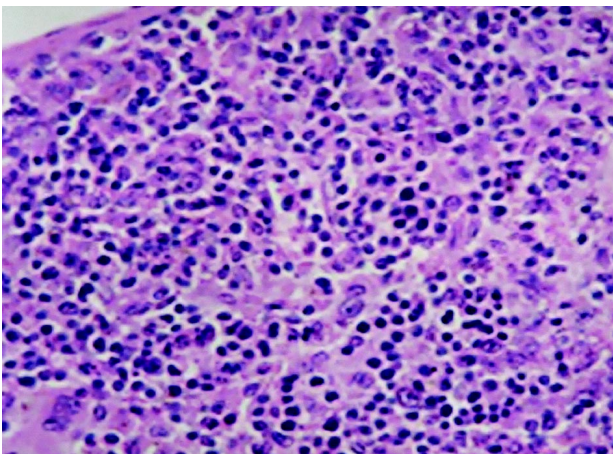


Figure 2 – Detail of splenic red pulp. Rats exposed to HESW and sacrificed 7 days after exposure. Observe the obliteration of red pulp by intense cellular proliferation constituted by erythroblasts, megakaryocytes and immature leukocytic cells (HE, X160).

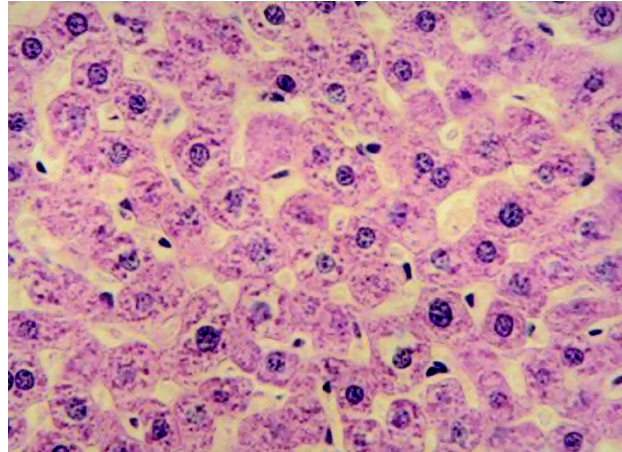


Figure 3 – Detail of liver. Rats from the control group (HE, X160).

growth of animals subjected to HESW, compared to the control group.

Lesions in organs adjacent to the kidney, during the acute phase, are well established in the literature (17). Several studies (14,18) show complete remission of macroscopic alterations in organs adjacent to the kidney, 7 days following the application of HESW. In the present study, macroscopic evaluation of organs adjacent to the kidney was normal, thus compatible with the literature.

Upon assessing the microscopic results, only those changes occurring on the seventh post-experi-

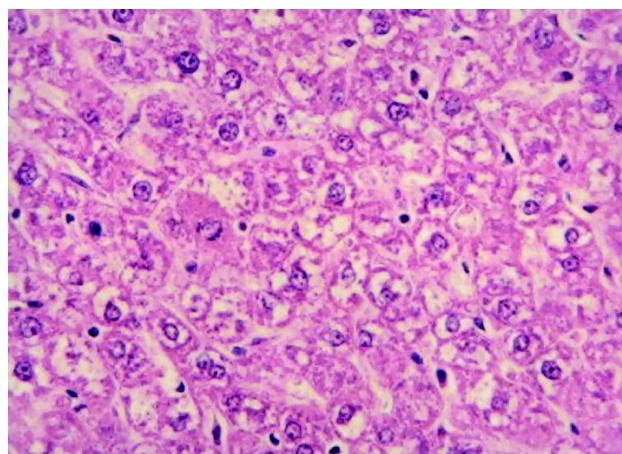


Figure 4 – Detail of liver. Rats exposed to HESW and sacrificed 7 days after exposure. Observe cloudy swelling (hydropic degeneration). Distended hepatocytes with areas of cytoplasmic rarefaction (HE, X160).

ment day can be valued and related to the experimental procedures.

In all rats from the experimental group at the seventh day, in one from the 180-day group and in one rat from the control group at the seventh day, an increased hematopoiesis was detected in the splenic red pulp, which was defined by an increase in the number of megakaryocytes and by the presence of erythroblasts nests and immature leukocytic cells. Such cellular changes were designated proliferative changes of the red pulp (PCRPP).

The increased hematopoiesis in the spleen of young rats can be related to inflammatory, neoplastic or hematopoietic stimuli (19). Evidently, there is no stimulus of neoplastic nature and we do not believe that any inflammatory stimuli existing previously to the seventh day of the experiment could be responsible for this kind of systemic response. Severe acute hemorrhage could trigger erythropoiesis and increase the production of megakaryocytes. However, in this study, no signs of current or organized hemorrhage were macroscopically detected, in the observed organs.

One hypothesis that could probably explain how shock waves alone can influence the development of extramedullary erythropoiesis in spleen lies in the fact that shock waves can release erythropoietin, which is produced by interstitial renal cells, among the tubules. Erythropoietin secretion is responsible for secondary erythrocytosis and, in such cases, hormonal action can stimulate the increase in production of cells from the hematopoietic lineage not only in bone marrow, but in the spleen as well.

Another hypothesis that could explain such changes is related to the direct action of HESW over splenic cells, due to the proximity of this organ to the kidney, in the rat. The mechanism of lesion can also be related to the release of free radicals, secondarily to the cavitation phenomenon, which can stimulate hematopoiesis in the spleen.

Whatever the cause, the hematopoiesis observed in these animals is a transitory phenomenon, and is not present in the majority of animals sacrificed in subsequent periods.

In relation to liver, in all animals that underwent HESW and sacrificed after 7 days, an alteration described as "cloudy swelling" of hepatocytes was

observed. This term is used to describe the swelling aspect of the organs involved and occurs as a result of changes in the mechanisms of cell membrane control, allowing an excessive entrance of water to the intracellular environment with consequent cell tumefaction (20). It is highly reversible, with hypoxia, severe malnutrition and toxic infectious states being the more frequent causes.

Cloudy swelling did not occur exclusively in rats subjected to HESW, but the difference between the control and experimental groups was statistically significant. An eventual direct or reflected action of HESW over the hepatic parenchyma seems unlikely, since cloudy swelling is a generalized alteration of the hepatic parenchyma. However, it could be explained by the extension of the focal zone of the lithotripter used (11 x 90 mm) and by the effects of cavitation phenomenon.

There were no significant circulatory, degenerative, necrotic and inflammatory alterations in lungs, pancreas and adrenals, meaning that such organs were not affected by shock waves.

Thus, from a histological point of view, the only changes that can be directly related to the application of HESW are those found in spleen and liver, almost exclusively in the experimental group that was sacrificed seven days following the exposure.

The findings of this study show that HESW can affect growing tissues, which are close to the focal zone and subjected to the effects of cavitation due to direct action of HESW as well as indirect mechanisms, such as release of erythropoietin and free radicals, that can be best understood through new studies.

The development of new equipments, capable of reducing the focal zone, with a better orientation of HESW and without impairing fragmentation will provide a higher safety when using this method in children.

CONCLUSIONS

Through the present study we were able to conclude that high-energy shock waves applied to the rat did not inhibit the animals' growth, since the percentage of weight gain was similar between the control and experimental groups.

High-energy shock waves caused a transitory histological lesion in spleen, characterized by proliferative changes in the red pulp, and in liver, characterized by cloudy swelling of hepatocytes. Such changes were observed only in the group that was exposed to HESW and sacrificed 7 days after the experiment. Rats that were followed for 90 and 180 days presented spontaneous recovery.

REFERENCES

1. Thomas R, Frentz JM, Harmon E, Frentz GD: Effect of extracorporeal shock wave lithotripsy on renal function and body height in pediatric patients. *J Urol.* 1992; 148:1064-6.
2. Dumont M, Marchand L, Laroche B, Robert G, Thabet M: Scintigraphic evaluation of renal function after extracorporeal shock wave lithotripsy. *J Can Assoc Radiol.* 1990; 41: 138-40.
3. Lim D, Walker RD, Ellsworth PI, Newman RC, Cohen MS, Barraza MA, et al.: Treatment of pediatric urolithiasis between 1984 and 1994. *J Urol.* 1996; 156: 702-5.
4. Nazli O, Cal C, Ozyurt C, Guinaydin G, Cureklibatir I, Aucieri V, et al.: Results of extracorporeal shock wave lithotripsy in the pediatric age group. *Eur Urol.* 1998; 33: 333-6.
5. Demirkenen O, Tansu N, Yaycioglu O, Onal B, Yalcin V, Solok V: Extracorporeal shock wave lithotripsy in the pediatric population. *J Endourol.* 1999; 13:147-50.
6. Longo JA, Netto Junior NR: Extracorporeal shock wave lithotripsy in children. *Urology.* 1995; 46: 550-2.
7. Shukla AR, Hoover DL, Homsy IL, Perlman S, Schurman S, Reisman EM: Urolithiasis in the small infant: the role and efficacy of extracorporeal shock wave lithotripsy. *J Urol.* 2000; 163: 82 (Abst. 362).
8. Lifshitz DA, Lingeman JE, Zafar FS, Hollensbe DW, Nyhuis AW, Evan AP: Alterations in predicted growth rates of pediatric kidneys treated with extracorporeal shock wave lithotripsy. *J Endourol.* 1998; 12: 469-75.
9. Denardi F: Undernutrition and Compensatory Renal Growth: Experimental Study in Rats. Doctoral Thesis, Medical School, Paulista State University, Botucatu, São Paulo, 1992. [in Portuguese]
10. Wesson LG: Compensatory growth and other growth responses of the kidney. *Nephron.* 1989; 51: 149-84.
11. Van Arsdalen KN, Kurzweil S, Smith J, Levin R: Effect of lithotripsy on immature rabbit bone and kidney development. *J Urol.* 1991; 146: 213-6.
12. Weber C, Moran ME, Braum ET, Drach GW: Injury of rat renal vessels following extracorporeal shock wave treatment. *J Urol.* 1992; 147: 476-81.
13. Banner B, Ziesmer D, Colins LA: Proliferative glomerulopathy following extracorporeal shock wave lithotripsy in the pig. *J Urol.* 1991; 146: 1425-8.
14. Goldenberg A, Nigro TJA, Netotegd GJ, Lanzone PV, Goldenberg S: Effects of shock wave on rat liver. *Acta Cir Bras.* 1994; 2: 51-64.
15. Claro JA: Shock Wave Effects in Renal Growth and Function: Experimental Study in Rats. Doctoral Thesis, Medical School, State University of Campinas, São Paulo, 1994. [in Portuguese]
16. Ferreira U, Claro JA, Denardi F, Figueiredo JF, Ricetto CLZ, Netto Junior NR: Functional and histological alterations in growing solitary rat kidney as result of extracorporeal shockwaves. *J Endourol.* 1995; 9: 45-9.
17. Chaussy C, Rondazzo RF, Fuchs JG: The effects of extracorporeal shock waves on human renal carcinoma cells and normal human embryonic kidney cells. *J Urol.* 1986; 135: 320.
18. Vergunst H, Terpstra OT, Brakel K, Lameris JS, Van Blaskenstein M, Schoereder FH: Safety and Efficacy in Biliary Lithotripsy. In: Burhenne HJ, Paumgartner G, Ferruci JT (eds.), *Biliary Lithotripsy II.* Chicago, Year Book Med Publ. 1990; pp. 25-8.
19. Ward JM: Classification of Reactive Lesions, Spleen. In: Jones TC, Ward JM, Mohr V, Hant RD (eds.): *Hemopoietic System.* Berlin, Springer-Verlag. 1990; pp. 220-6.
20. Crawford JM: The Liver and Biliary Tract. In: Cotran RS, Kumar V, Collins T: *Robbins (eds.), Pathologic Basis of Disease.* Philadelphia, W.B. Saunders. 6th ed., 1999; p. 847.

Received: February 18, 2004

Accepted after revision: April 15, 2004

Correspondence address:

Dr. Ubirajara Ferreira
Rua Conceição, 233 / 1603
Campinas, SP, 13010-916, Brazil
Fax: + 55 19 3236-1177
E-mail: ubirafer@uol.com.br