



# Prophylactic effect of coconut water (*Cocos nucifera* L.) on ethylene glycol induced nephrocalcinosis in male wistar rat

M. Gandhi, M. Aggarwal, S. Puri, S.K. Singla

*Department of Biochemistry (MG, MA, SKS), Department of Biotechnology (SP), University Institute of Engineering and Technology, Panjab University, Chandigarh, India*

## ABSTRACT

**Purpose:** Many medicinal plants have been employed during ages to treat urinary stones though the rationale behind their use is not well established. Thus, the present study was proposed to evaluate the effect of coconut water as a prophylactic agent in experimentally induced nephrolithiasis in a rat model.

**Materials and Methods:** The male Wistar rats were divided randomly into three groups. Animals of group I (control) were fed standard rat diet. In group II, the animals were administered 0.75% ethylene glycol in drinking water for the induction of nephrolithiasis. Group III animals were administered coconut water in addition to ethylene glycol. All the treatments were continued for a total duration of seven weeks.

**Results and Conclusion:** Treatment with coconut water inhibited crystal deposition in renal tissue as well as reduced the number of crystals in urine. Furthermore, coconut water also protected against impaired renal function and development of oxidative stress in the kidneys. The results indicate that coconut water could be a potential candidate for phytotherapy against urolithiasis.

## ARTICLE INFO

### Key words:

Antioxidants; Calcium Oxalate; Cocos; Phytotherapy; Urolithiasis

**Int Braz J Urol. 2013; 39: 108-17**

Submitted for publication:  
February 05, 2012

Accepted after revision:  
November 30, 2012

## INTRODUCTION

Urolithiasis is a common occurrence, affecting up to 10%-15% of the population at some point during their lifetime (1). Increased incidence of kidney stones in the industrialized world is associated with improved standards of living, race, ethnicity and geographical area (2). Studies by Trinchieri et al. (3) reported recurrence rates of 50 - 75% after 10 and 20 years, respectively. Kidney stones composed of CaOx, either alone or mixed with calcium phosphate, are hitherto the most common stones accounting for more than 80% of them (4). Earlier studies have shown that tubular cell injury facilitates calcium oxalate (CaOx) crystal formation and deposition in the renal tubules (5). Similarly

various authors demonstrated that calcium oxalate crystals increased lipid peroxidation that further led to renal epithelial injury (6,7).

Although during recent years development of modern techniques such as extracorporeal shock wave lithotripsy and percutaneous nephrolithotomy has revolutionized the surgical management of the problem, yet not much progress has been made towards the medical management of urolithiasis. Many medicinal plants have been employed during ages to treat urinary stones though their mechanism of action is not well established through systematic and pharmacological studies, except for some composite herbal drugs and plants (8-10).

Coconut water (*Cocos nucifera* L.) is the most nutritious wholesome beverage in all the

coconut producing countries. Coconut water, the liquid endosperm of coconut, contains sugars, vitamins, minerals, proteins, free amino acids and growth promoting factors. It is a natural isotonic beverage and is acclaimed in the tropics for its numerous medicinal properties. Coconut water is an essential dietary ingredient of South India where the incidence of urolithiasis is very low (11). However, so far no systematic study has been reported regarding the antiurolithiatic property of coconut water. So the present study was designed to evaluate the efficacy of coconut water on ethylene glycol induced nephrolithiasis.

## MATERIALS AND METHODS

### Collection of coconut water

Fresh coconuts were purchased from the market, broken carefully, liquid endosperm were collected and used for each day experiment. While purchasing coconuts from the market, the nuts stored in cold conditions and from the same stock were procured.

### Animals

Male Wistar rats weighing 150-170 g were housed in polypropylene cages in a room maintained at  $25 \pm 1^\circ$  C with alternate exposure to light and dark for 12 hours. The animals were acclimatized for one month in polypropylene cages under hygienic conditions. All procedures were done in accordance with ethical guidelines for care & use of laboratory animals and were approved by the local experimental animal ethical committee. The animals were provided standard animal feed and water ad libitum. The standard rat diet was acquired from Aashirwad Company (Ludhiana, Punjab, India), and the composition of the diet is given in Table-1. To induce urolithiasis in animals, they were exposed to 0.75% ethylene glycol in their drinking water for 7 weeks. The protocol to induce urolithiasis was adapted from Huang et al. (12), where the authors showed evidence that the administration of "0.75 % ethylene glycol" in drinking water can induce "urolithiasis" in male wistar rats.

Rats were divided into three groups of six rats each and fed the following diet:

Group 1: Normal rat diet (control).

Group 2: Normal rat diet + 0.75% ethylene glycol (EG) mixed with tap water for 7 weeks ad libitum (12).

Group 3: Normal rat diet + 0.75% EG + 10% Coconut water for 7 weeks ad libitum.

### Methods

A 10% of kidney homogenate was prepared in 0.1 mM tris buffer (pH 7.4) and was used for assaying lipid peroxidation (13), antioxidant enzymes superoxide dismutase (14) and catalase (15).

All the animals were kept in individual metabolic cages and urine samples were collected throughout 24hours, one day before sacrificing the animals. Blood was collected from orbital sinus under mild anesthetic conditions, using diethyl ether as an anesthetic agent and animals were sacrificed by cervical decapitation. Serum was separated by centrifugation at  $3,000 \times g$  for 15 minutes, analyzed for creatinine (code no. FRE-BCERM0082) and urea (code no. FRCER0034) by Erba Manheim diagnostic kits.

For the expression studies, total RNA was isolated from kidney of rats using Trizole reagent (Gibco BRL, UK). Single stranded cDNA was synthesized using oligo dT 12-18 as primers and AMV reverse transcriptase. The amplification of different antioxidant enzymes was carried out by using specific primers viz, SOD (forward primer 5'- GCA GAA GGC AAG CGG TGA AC-3', reverse primer 5'- TAG CAG GAC AGC AGA TGA GT-3', 446 bp), catalase (forward primer 5'- GCG AAT GGA GAG GCA GTG TAC-3', reverse primer 5'- GAG TGA CGT TGT CTT CAT TAG CAC TG-3', 652 bp). GAPDH was chosen as house keeping gene (forward primer 5'-TCT AAG AAA CAT GGC GGT CC-3' reverse primer 5'-CAG TTA GCA GGC CAG CAG AT-3', 197bp) (16-20). PCR products were resolved on 1% agarose gels. The bands were identified based on the product size using 100 bp ladder. The PCR products were quantitated by densitometric scanning using scion image software. The values were expressed as percentages with respect to control. The RT-PCR conditions were as follows: (1) reverse transcription, (30 minutes,  $55^\circ$  C for CAT, SOD and 50 minutes  $45^\circ$  C for GAPDH) (2) initial activation step, 2 minutes at  $94^\circ$  C (3) three step cycling (34 cycles for GAPDH , 26 cycles for SOD

**Table 1 - Composition of standard animal diet.**

Elements	Concentration (ppm)
V	1.5 ± 0.4
Mn	122.4 ± 0.6
Fe	817.5 ± 54
Co	0.21 ± 0.06
Ni	3.11 ± 0.04
Cu	16.99 ± 0.05
Zn	64.03 ± 1.07
As	2.22 ± 1.99
Se	0.54 ± 0.2
Br	5.67 ± 0.87
Sr	23.85 ± 1.0
Cr	2.7 ± 0.2
Ingredients	Amount (g)
Casein	18
Starch	25
Sucrose	25
Cellulose	14
Vitamin mixture	2
Salt mixture	6
Corn oil	10mL

and 30 cycles for CAT), each cycle consisting of denaturation for 45 sec at 94° C followed by annealing for 45 sec at 55.5° C and extension for 1 minutes at 68° C.

Though ideally, urine chemistry and the pH should have been noted; based on our earlier observation and those of others (21-23) it was assumed that the urine chemistry & pH did not differ significantly in the 3 groups of rats. A 24hours urine collection was done for polarization microscopy to compare calcium oxalate crystallization in the 3 groups. For analysis of crystalluria a drop of

urine sample was spread on a glass slide and visualized under polarized light using Leica DM3000 light microscope (24).

For histopathological studies, the kidneys were removed and their transverse sections were fixed in 10% buffered formalin solution (pH 7). The tissues were dehydrated and embedded in paraffin wax (68° C). The paraffin sections were then cut and finally stained with Delafield's Hematoxylin and Eosin staining (H&E staining).

### Data analysis

The results were expressed as mean ± standard deviation (S.D) for six animals in each group. Kolmogorov Smirnov test was applied to check the parametric distribution of the data. Differences between groups were assessed by one way analysis of variance (ANOVA) using the SPSS software package for Windows. Post hoc test was performed for inter-group comparisons using the least significance difference (LSD) test; significance at P-values < 0.001, < 0.01, < 0.05 have been given respective symbols in the tables and figures.

### RESULTS

To assess the renal function and injury, creatinine & urea level in the serum was determined. Creatinine level was also found to be increased significantly (P < 0.001) in urolithiatic group II animals. Urea in group II was found to be 70.92% increased compared to control. However, administration of coconut water significantly lowered the level of creatinine and urea in group III animals (Table-2). In group II, lipid peroxidation was found to be significantly elevated as compared to group I rats. MDA level was found to be increased by 191.84 % in group II compared to control group (Table-3). Treatment with coconut water in group III partly reversed this increase in MDA level. In urolithiatic animals, the gene expression of SOD and CAT was significantly increased during RT-PCR analysis (Figures 1 and 2a). Similarly, the activity of SOD and CAT was found to be increased after the administration of ethylene glycol in group II animals as compared to group I animals (Figures 3a and 3b). However, the administration

**Table 2 - Effect of various treatments on serum creatinine and urea level in experimental rats.**

	Group I	Group II	Group III
Creatinine (mg/dL)	0.46 ± 0.03	0.77 ± 0.02*** (+66.37%)	0.57 ± 0.01### (+23.86%)
Urea (mg/dL)	49.53 ± 2.94	84.66 ± 4.44*** (+ 70.92%)	68.03 ± 3.95### (+ 37.35%)

Values in brackets are percentage increase (+) or percentage decrease (-) compared with control (group I); \*p < 0.05 \*\*p < 0.01, \*\*\*p < 0.001 indicates significant change in comparison with control group I; #p < 0.05, ###p < 0.01, ###p < 0.001 indicates significant change in comparison with group II.

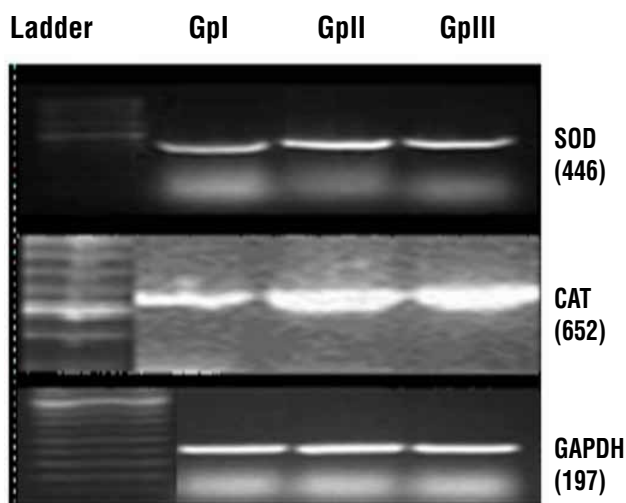
**Table 3 - Effect of coconut water on Lipid peroxidation status in the kidney.**

Animal group	Lipid peroxidation (mol MDA/mg protein/15 min.)
Group I	13.36 ± 3.36
Group II	38.99 ± 3.86*** (+191.84 %)
Group III	27.68 ± 2.45### (+107.18%)

Values in brackets are percentage increase (+) or percentage decrease (-) compared with control (group I); \*p < 0.05, \*\*p < 0.01, \*\*\*p < 0.001 indicates significant change in comparison with control group I; #p < 0.05, ###p < 0.01, ###p < 0.001 indicates significant change in comparison with group II.

of coconut water decreased the enzyme activity of the SOD and CAT in the group III compared to group II (Figures 3a and 3b) but decrease in the expression level of catalase in the group III compared to group II was not as that much as in case of SOD (Figures 1, 2a and 2b).

On observing urine samples under polarization microscope, no crystal deposition was observed in control animals (Figure-4a), whereas group II rats revealed presence of abundant CaOx crystals deposition (Figure-4b). In group III, a drastic decrease in the number of urinary crystals was observed (Figure-4c). The histopathological observation of renal tissue under light microscope showed normal architectural and intactness without

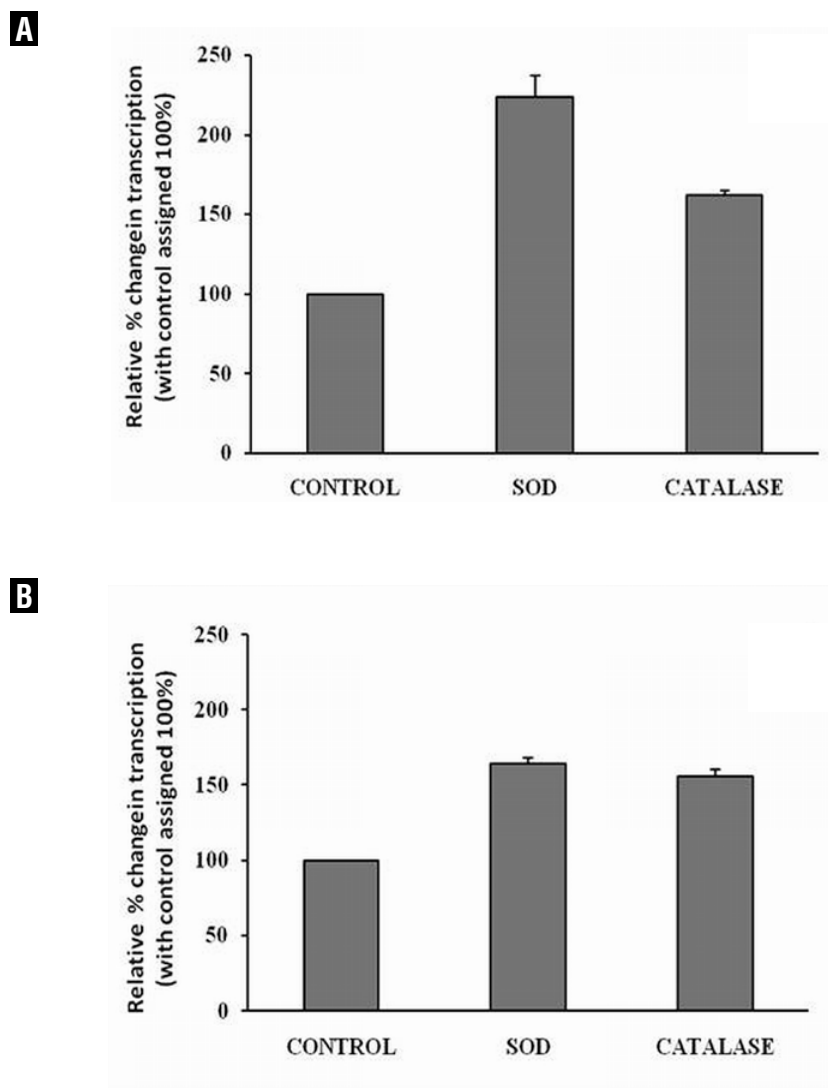
**Figure 1 - Effect of various treatment on the expression level of different antioxidant enzymes ( SOD, CAT and GAPDH).**


any apparent damage in control rats. However, the urolithiatic rats showed tubulae containing crystalline particles, mostly distal segments with consequent dilation of distal tubules, thin loop and collecting ducts. In group III, no depositions of crystalline particles were observed (Figure-5c).

## DISCUSSION

Coconut is grown and consumed largely in South India where incidence of urolithiasis is low. It is therefore pertinent to investigate the effect of coconut water in nephrocalcinosis model of male Wistar rats. Some investigators (21,25) have studied various natural therapeutic agents in vivo

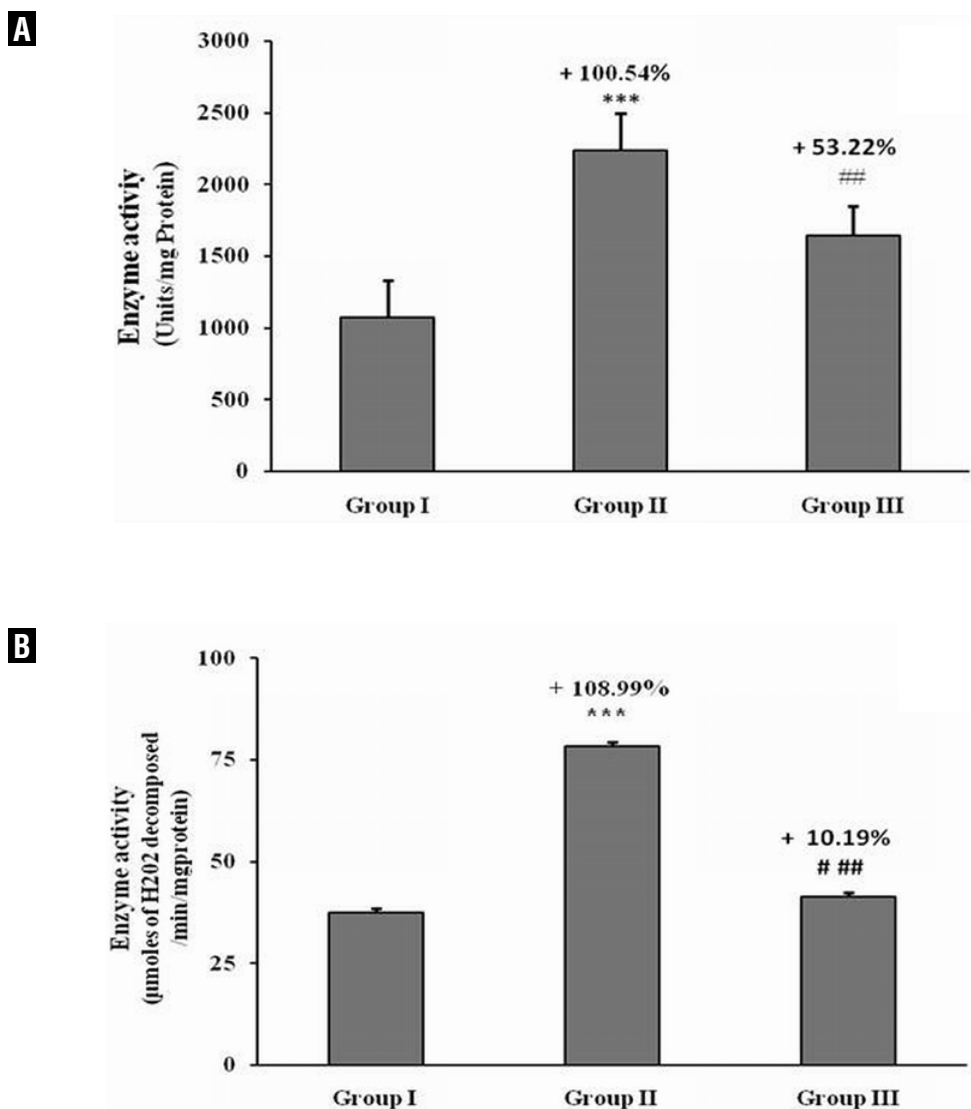
**Figure 2 - Densitometry scanning of antioxidant enzymes following RT PCR program using scion image software in different groups. (A) Urolithiatic group II vs group I(control), (B) coconut water treated vs group I (control).**



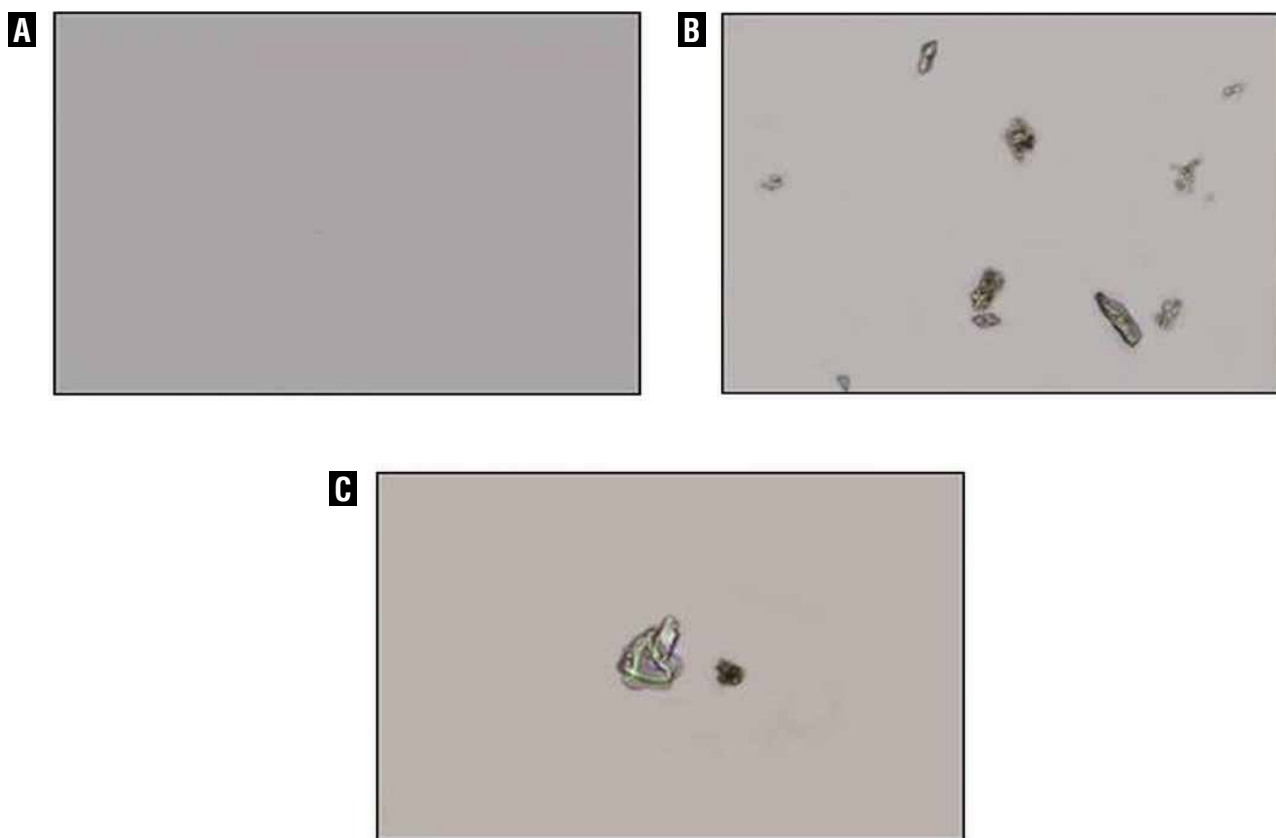
animal models. In the present study, efficacy of coconut water was evaluated on ethylene glycol induced nephrocalcinosis in male Wistar rats. Stone formation in ethylene glycol fed animals is caused by hyperoxaluria, which causes increased renal retention and excretion of oxalate (26). Under hyperoxaluric condition, oxalate has been reported to induce lipid peroxidation and to cause renal damage by reacting with polyunsaturated fatty acids in the cell membrane (27). In

the present study lipid peroxidation was found to be significantly increased during hyperoxaluria (Table-3). The increased MDA content might have resulted from an increase of free radicals as a result of stress condition in the rats with ethylene glycol intoxication. Administration of coconut water was able to reduce the levels of MDA (Table-3), thereby showing the potential of coconut water as free radical scavenger. Our results revealed that oxalate exposure resulted in

**Figure 3 - Effect of coconut water administration on Superoxide dismutase (A) and Catalase activity (B) in kidney tissue of animals in different groups.**



Values are expressed as mean  $\pm$  SD and percentage increase (+) or percentage decrease (-) compared with control (group I); \* $p < 0.05$ , \*\* $p < 0.01$ , \*\*\* $p < 0.001$  indicates significant change in comparison with control group I, # $p < 0.05$ , ## $p < 0.01$ , ### $p < 0.001$  indicates significant change in comparison with group II.

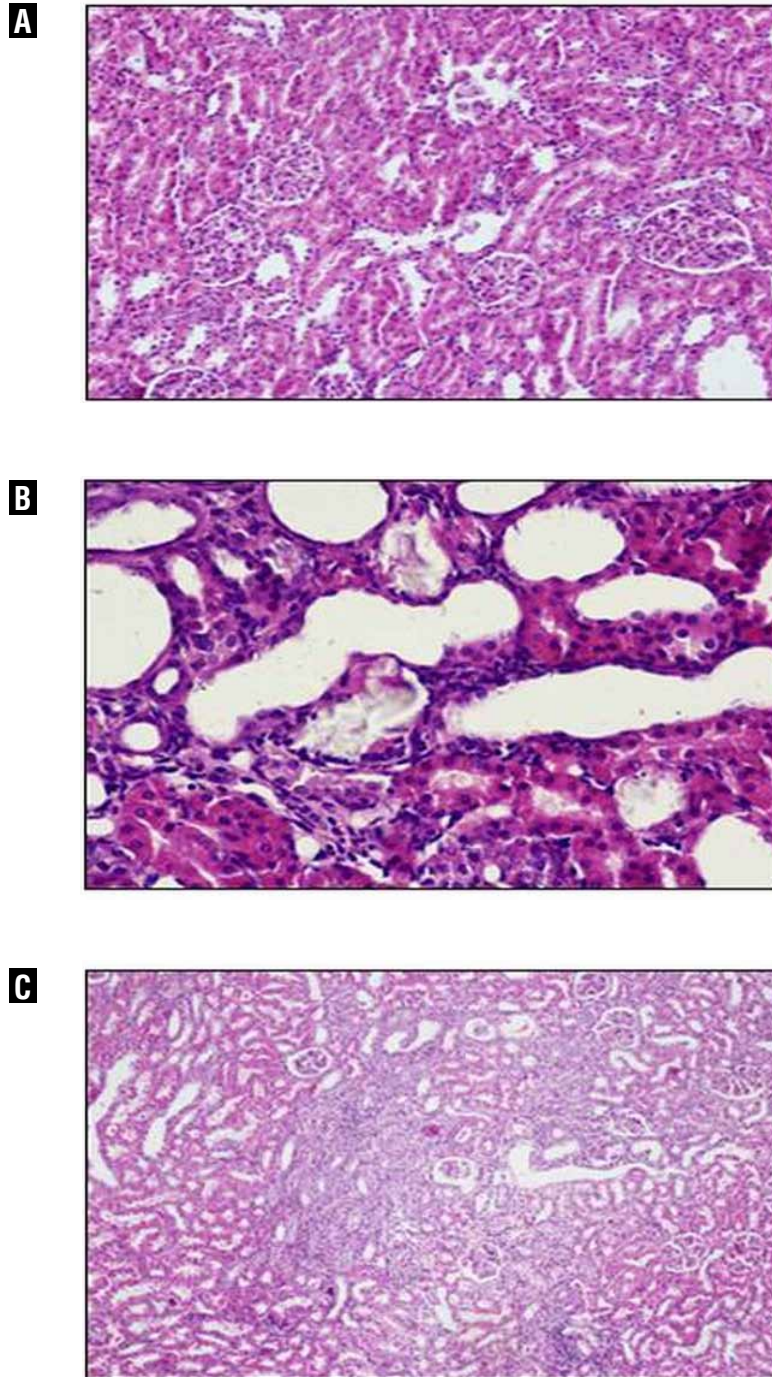
**Figure 4 - Polarization micrograph of rat's urine sample.**

(A) Urine of control rats (group I), devoid of any crystals. (B) Urine of urolithiatic rats (group II) showing CaOx crystals. (C) Urine of coconut water treated rats showing reduced crystals deposition. Original magnifications of 100x.

increased antioxidant enzymes SOD and CAT activity and their expression at mRNA level in kidney tissues (Figures 1, 2a, 2b, 3a and 3b). The increase in SOD activity as observed in our experimentation could be an adaptive response of this enzyme to increased production of superoxide ions following activation of NAD(P)H oxidase via cytokine TGF- $\beta$ 1 (transforming growth factor  $\beta$ 1) induction (28). The increase in SOD activity will further lead to high production of hydrogen peroxide ( $H_2O_2$ ). Catalase is responsible for the decomposition of hydrogen peroxide, therefore after ethylene glycol

exposure an increase in catalase activity was also observed. The rebalancing of elevated antioxidant enzyme's activity and their expression by coconut water post treatment further substantiated the protective nature of coconut water against free radical induced oxidative stress. Furthermore, ethylene glycol administration increased the level of serum creatinine and urea (Table-2) indicating renal dysfunction due to urolithiatic condition. Here again rebalancing of serum urea further unveils the potential effect of coconut water on maintaining renal functioning.

**Figure 5 - Representative microscopic examination under light microscope of renal tissue.**



(A) Renal tissue of control (group1) rats showing no sign of crystallization. (B) Renal tissue of urolithiatic rats (group 2) showing Crystals deposition mainly located in renal tubules (200×). (C) Renal tissue of group 3 treated rats showing no crystal formation.



In the present study, administration of coconut water reduced the number of crystals in the urine as compared to urolithiatic rats (Figure-4c). Our findings are consistent with the studies by Itoh et al. (29) who showed that green tea reduces CaOx crystal deposits in the kidneys of rats made hyperoxaluric by the administration of ethylene glycol.

The present histopathological studies showed EG induced crystal deposition in the renal cells (Figure-5b) and most of crystal deposition took place in the renal tubules, which corroborates the results of other studies reporting that crystals deposition mainly occur in tubules (30). Administration of coconut water to urolithiatic animals prevented supersaturation of calcium oxalate and thus decreased their deposition in renal tubules (Figure-5c).

We are aware of some limitations of the study such as absence of liquid ingestion control by the animals, yet the study does suggest beneficial effect of coconut water in nephrocalcinosis.

## CONCLUSIONS

In conclusion, coconut water has potential to inhibit the genes of oxidative stress to push the activity of these enzymes towards normal. The re-balancing of elevated antioxidant enzyme gene expression by coconut water treatment, reduced mineral deposits in kidney tissue further substantiated the prophylactic nature of coconut water in nephrolithiasis.

## ACKNOWLEDGEMENT

The Senior Research Fellowship to Manish Gandhi (Grant no. 45/10/2010-BMS) by the Indian Council of Medical Research, New Delhi is gratefully acknowledged.

## CONFLICT OF INTEREST

None declared.

## REFERENCES

1. xLong LO, Park S: Update on nephrolithiasis management. *Minerva Urol Nefrol.* 2007; 59: 317-25.
2. Stamatelou KK, Francis ME, Jones CA, Nyberg LM, Curhan GC: Time trends in reported prevalence of kidney stones in the United States: 1976-1994. *Kidney Int.* 2003; 63: 1817-23.
3. Trinchieri A, Ostini F, Nespoli R, Rovera F, Montanari E, Zanetti G: A prospective study of recurrence rate and risk factors for recurrence after a first renal stone. *J Urol.* 1999; 162: 27-30.
4. Kaufman DW, Kelly JP, Curhan GC, Anderson TE, Dretler SP, Preminger GM, et al.: Oxalobacter formigenes may reduce the risk of calcium oxalate kidney stones. *J Am Soc Nephrol.* 2008; 19: 1197-203.
5. Khan SR, Hackett RL: Retention of calcium oxalate crystals in renal tubules. *Scanning Microsc.* 1991; 5: 707-11; discussion 711-2.
6. Thamilselvan S, Khan SR: Oxalate and calcium oxalate crystals are injurious to renal epithelial cells: results of in vivo and in vitro studies. *J Nephrol.* 1998; 11(Suppl 1): 66-9.
7. Bashir S, Gilani AH: Antiurolithic effect of *Bergenia ligulata* rhizome: an explanation of the underlying mechanisms. *J Ethnopharmacol.* 2009; 122: 106-16.
8. Miyaoka R, Monga M: Use of traditional Chinese medicine in the management of urinary stone disease. *Int Braz J Urol.* 2009; 35: 396-405.
9. Atmani F, Sadki C, Aziz M, Mimouni M, Hacht B: *Cynodon dactylon* extract as a preventive and curative agent in experimentally induced nephrolithiasis. *Urol Res.* 2009; 37: 75-82.
10. Aggarwal A, Singla SK, Gandhi M, Tandon C: Preventive and curative effects of *Achyranthes aspera* Linn. extract in experimentally induced nephrolithiasis. *Indian J Exp Biol.* 2012; 50: 201-8.
11. Marickar YM, Joseph D, Abraham PA: Clinical study of 192 urinary stones in Kerala. *Ind J Surg.* 1977; 39: 144-50.
12. Huang HS, Chen CF, Chien CT, Chen J: Possible biphasic changes of free radicals in ethylene glycol-induced nephrolithiasis in rats. *BJU Int.* 2000; 85: 1143-9.
13. Buege JA, Aust SD: Microsomal lipid peroxidation. *Methods Enzymol.* 1978; 52: 302-10.
14. Kono Y: Generation of superoxide radical during autoxidation of hydroxylamine and an assay for superoxide dismutase. *Arch Biochem Biophys.* 1978; 186: 189-95.
15. Luck H: Catalase. In: Bergmeyer HU (ed.), *Methods of Enzymatic Analysis.* Academic Press, New York 1971; pp. 885-93.
16. Williams K, Frayne J, Hall L: Expression of extracellular glutathione peroxidase type 5 (GPX5) in the rat male reproductive tract. *Mol Hum Reprod.* 1998; 4: 841-8.
17. El Moutassim S, Guérin P, Ménéz Y: Mammalian oviduct and protection against free oxygen radicals: expression of genes encoding antioxidant enzymes in human and mouse. *Eur J Obstet Gynecol Reprod Biol.* 2000; 89: 1-6.

18. Cederberg J, Galli J, Luthman H, Eriksson UJ: Increased mRNA levels of Mn-SOD and catalase in embryos of diabetic rats from a malformation-resistant strain. *Diabetes*. 2000; 49: 101-7.
19. Park EJ, Park K: Gene expression profiles of cultured rat cardiomyocytes (H 9C2 cells) in response to arsenic trioxide at subcytotoxic level and oxidative stress. *J Health Sci*. 2006; 52: 512-21.
20. Liu J, Lei D, Waalkes MP, Beliles RP, Morgan DL: Genomic analysis of the rat lung following elemental mercury vapor exposure. *Toxicol Sci*. 2003; 74: 174-81.
21. Freitas AM, Schor N, Boim MA: The effect of *Phyllanthus niruri* on urinary inhibitors of calcium oxalate crystallization and other factors associated with renal stone formation. *BJU Int*. 2002; 89: 829-34.
22. Grases F, March JG, Ramis M, Costa-Bauza A: The influence of *Zea mays* on urinary risk factors for kidney stones in rats. *Phytother Res*. 1993; 7: 146-49.
23. Grases F, Ramis M, Costa-Bauzá A, March JG: Effect of *Herniaria hirsuta* and *Agropyron repens* on calcium oxalate urolithiasis risk in rats. *J Ethnopharmacol*. 1995; 45: 211-4.
24. Herrmann U, Schwille PO, Kuch P: Crystalluria determined by polarization microscopy. Technique and results in healthy control subjects and patients with idiopathic recurrent calcium urolithiasis classified in accordance with calciuria. *Urol Res*. 1991; 19: 151-8.
25. Bashir S, Gilani AH, Siddiqui AA, Pervez S, Khan SR, Sarfaraz NJ, et al.: *Berberis vulgaris* root bark extract prevents hyperoxaluria induced urolithiasis in rats. *Phytother Res*. 2010; 24: 1250-5.
26. Selvam R, Kalaiselvi P, Govindaraj A, Bala Murugan V, Sathish Kumar AS: Effect of *A. lanata* leaf extract and *Vediuppu chunnam* on the urinary risk factors of calcium oxalate urolithiasis during experimental hyperoxaluria. *Pharmacol Res*. 2001; 43: 89-93.
27. Ernester LN: Oxidation and phosphorylation. In: Ronald WE MEe (ed.), *Methods in Enzymology*. Academic Press, New York. 1967; pp; 574-80.
28. Rashed T, Menon M, Thamilselvan S: Molecular mechanism of oxalate-induced free radical production and glutathione redox imbalance in renal epithelial cells: effect of antioxidants. *Am J Nephrol*. 2004; 24: 557-68.
29. Itoh Y, Yasui T, Okada A, Tozawa K, Hayashi Y, Kohri K: Preventive effects of green tea on renal stone formation and the role of oxidative stress in nephrolithiasis. *J Urol*. 2005; 173: 271-5.
30. Khan SR, Glenton PA, Byer KJ: Modeling of hyperoxaluric calcium oxalate nephrolithiasis: experimental induction of hyperoxaluria by hydroxy-L-proline. *Kidney Int*. 2006; 70: 914-23.

---

**Correspondence address:**

Dr. S.K. Singla  
Department of Biochemistry,  
Panjab University  
Chandigarh-160014, India.  
Telephone: + 91 017 2253-4136  
E-mail: singla1951@pu.ac.in