



# Robot-assisted modified bilateral dismembered V-shaped flap pyeloplasty for ureteropelvic junction obstruction in horseshoe kidney using KangDuo-Surgical-Robot-01 system

Zhenyu Li <sup>1</sup>, Xinfei Li <sup>1</sup>, Shubo Fan <sup>1</sup>, Kunlin Yang <sup>1</sup>, Chang Meng <sup>1</sup>, Shengwei Xiong <sup>1</sup>, Silu Chen <sup>1</sup>, Zhihua Li <sup>1</sup>, Xuesong Li <sup>1</sup>

<sup>1</sup> Department of Urology, Peking University First Hospital, Institute of Urology, Peking University, National Urological Cancer Center, Beijing, China

## ABSTRACT

**Purpose:** Horseshoe kidney (HSK) is the most common renal fusion anomaly, occurring in 0.25% of the population (1). It presents technical obstacles to pyeloplasty for ureteropelvic junction obstruction (UPJO) despite robotic assistance (2, 3). KangDuo-Surgical-Robot-01 (KD-SR-01), an emerging robotic platform in China, has yielded satisfactory outcomes in pyeloplasty (4, 5). We first describe our modified technique of robotic bilateral pyeloplasty for UPJO in HSK using KD-SR-01 system in the Lithotomy Trendelenburg position.

**Materials and Methods:** A 36-year-old man with HSK and bilateral UPJO suffered right flank pain due to renal calculi (Figure-1). Repeated double-J stent insertion and ureteroscopy lithotripsy did not relieve his symptoms. A robot-assisted modified bilateral dismembered V-shaped flap pyeloplasty was performed using KD-SR-01 system in the Lithotomy Trendelenburg position.

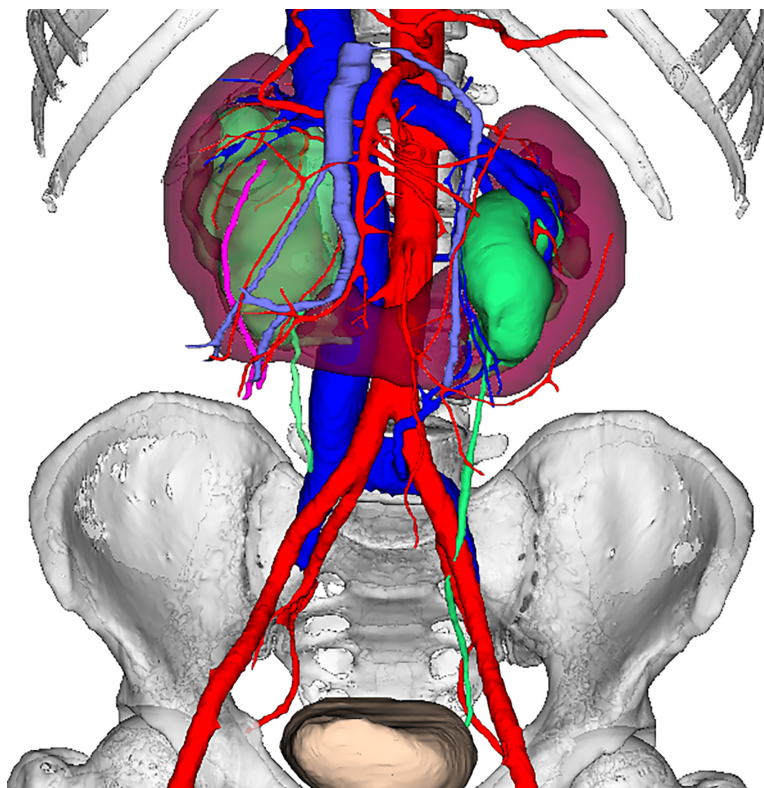
**Results:** Total operative time was 298 minutes with 50 ml estimated blood loss. There was no conversion to laparoscopic or open surgery. A follow-up of 14 months showed relieving symptoms and stable renal function. Cine magnetic resonance urography and computed tomography urography revealed improved hydronephrosis and good drainage. No intraoperative or postoperative complications occurred.

**Conclusions:** It is technically feasible to perform a KD-SR-01-assisted modified bilateral dismembered V-shaped flap pyeloplasty in the Lithotomy Trendelenburg position for HSK. This procedure achieves managing UPJO on both sides without redocking the system and provides a wider operative field. In addition, it may be associated with better ergonomics, better cosmetic outcomes, and less possibility of postoperative bowel adhesion. However, further investigation is still warranted to confirm its safety, efficacy, and advantages over traditional procedures.

## CONFLICT OF INTEREST

None declared.

**Figure 1 - The three-dimensional image reconstructed by urinary enhanced computed tomography of the patient.**



## REFERENCES

1. Sobrinho ULGP, Albero JRP, Becalli MLP, Sampaio FJB, Favorito LA. Three-dimensional printing models of horseshoe kidney and duplicated pelvicalyceal collecting system for flexible ureteroscopy training: a pilot study. *Int Braz J Urol.* 2021;47:887-9.
2. Oderda M, Callaris G, Allasia M, Dalmaso E, Falcone M, Catti M, et al. Robot-assisted laparoscopic pyeloplasty in a pediatric patient with horseshoe kidney: surgical technique and review of the literature. *Urologia.* 2017;84:55-60.
3. Esposito C, Masieri L, Blanc T, Musleh L, Ballouhey Q, Fourcade L, et al. Robot-assisted laparoscopic pyeloplasty (RALP) in children with complex pelvi-ureteric junction obstruction (PUJO): results of a multicenter European report. *World J Urol.* 2021;39:1641-7.
4. Fan S, Dai X, Yang K, Xiong S, Xiong G, Li Z, et al. Robot-assisted pyeloplasty using a new robotic system, the KangDuo-Surgical Robot-01: a prospective, single-centre, single-arm clinical study. *BJU Int.* 2021;128:162-5.
5. Fan S, Xiong S, Li Z, Yang K, Wang J, Han G, et al. Pyeloplasty with the Kangduo Surgical Robot vs the da Vinci Si Robotic System: Preliminary Results. *J Endourol.* 2022: Aug 22. Epub ahead of print.

---

**Correspondence address:**

Xuesong Li, MD  
Department of Urology,  
Peking University First Hospital,  
Institute of Urology, Peking University,  
National Urological Cancer Center  
Beijing, 100034, China  
Telephone: + 86 10 8357-5101  
E-mail: pineneedle@sina.com

---

Submitted for publication:  
October 19, 2022

---

Accepted after revision:  
October 20, 2022

---

Published as Ahead of Print:  
November 30, 2022

## ARTICLE INFO

 **Zhenyu Li**

<https://orcid.org/0000-0002-9319-2536>

**Available at:** [http://www.intbrazjurol.com.br/video-section/20220525\\_Zhenyu\\_et\\_al](http://www.intbrazjurol.com.br/video-section/20220525_Zhenyu_et_al)  
**Int Braz J Urol. 2023; 49 (Video #5): 388-90**