



Robotic-assisted repair of colovesical anastomosis after Hartmann's reversal procedure

Jaime Poncel ¹, Aref S. Sayegh ¹, Oliver Ko ¹, Rene Sotelo ¹

¹ Catherine and Joseph Aresty, Department of Urology, USC Institute of Urology, Keck School of Medicine, University of Southern California, Los Angeles, CA, USA

ABSTRACT

Purpose: Hartmann's procedure is the resection of the rectosigmoid colon with an end colostomy formation and closure of the anorectal stump (1). Its reversal has a morbidity rate up to 58% (2, 3) with an incidence of fistulae formation of 4.08% (1). Herein, we present a robotic-assisted repair of a complex fistula that occurred as complication of Hartmann's reversal when the stapler was introduced inadvertently through the vaginal canal.

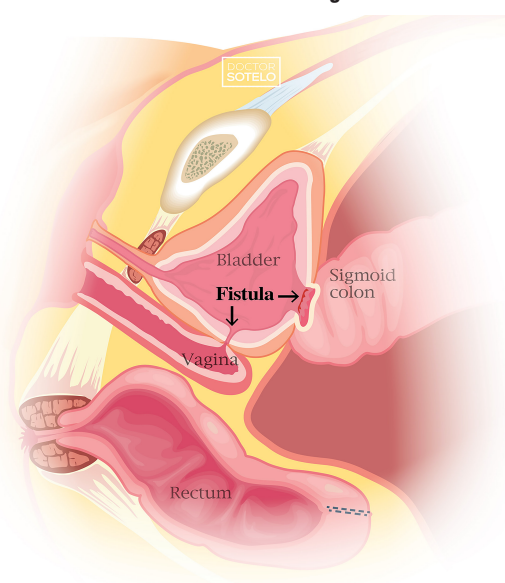
Patient and methods: Eighty-three-year-old female with past medical history of hysterectomy and ischemic colitis that required colectomy and colostomy placement in December 2020. In March 2022, the patient underwent a colostomy takedown, after which she reported fecaluria, urine leakage per vagina, and recurrent urinary tract infections. Cystoscopy and vaginoscopy revealed a large colovesical fistula, a staple in the bladder trigone, and several staples in the anterior vaginal wall. Robotically, extensive adhesiolysis was performed, the sigmoid was separated from the bladder, and the intact rectal stump was dissected free. The staple from the bladder trigone was removed. Bladder was closed in two layers with 3-0 V-Loc. Colorectal anastomosis was not feasible due to the short length of both ends. Therefore, a permanent colostomy was placed.

Results: Operative time was 454min., and estimated blood loss was 100cc. Discharged on postoperative day 4 with a JP drain and a 20Fr Foley catheter. Drain, and Foley were removed on postoperative days 9 and 23, respectively. No postoperative complications were reported.

Conclusion: Robotic-assisted repair represents an effective approach for the management of colovesical fistulae after Hartmann's reversal.

CONFLICT OF INTEREST

None declared.

Figure 1 - Colovesical and Vesicovaginal fistulae.**REFERENCES**

1. Sotelo R, Medina LG, Husain FZ, Khazaeli M, Nikkhou K, Cacciamani GE, et al. Robotic-assisted laparoscopic repair of rectovesical fistula after Hartmann's reversal procedure. *J Robot Surg.* 2019;13:339-43.
2. Mirza KL, Wickham CJ, Noren ER, Hwang GS, Ault GT, Ortega AE, et al. Outcomes of colostomy takedown following Hartmann's procedure: successful restoration of continuity comes with a high risk of morbidity. *Colorectal Dis.* 2021;23:967-74.
3. Hallam S, Mothe BS, Tirumulaju R. Hartmann's procedure, reversal and rate of stoma-free survival. *Ann R Coll Surg Engl.* 2018;100:301-7. nt of Male Urethral Stricture Disease. *Eur Urol.* 2021;80:190-200.

Correspondence address:

Rene Sotelo, MD
 Professor of Urology
 Department of Urology,
 USC Institute of Urology, Keck School of Medicine
 1441 Eastlake Ave., Suite 7416
 Los Angeles, CA, USA
 Telephone: + 1 90089-9178,
 E-mail: rene.sotelo@med.usc.edu

Submitted for publication:
 September 06, 2022

Accepted after revision:
 September 15, 2022

Published as Ahead of Print:
 November 30, 2022

ARTICLE INFO

 **Jaime Poncel**
<https://orcid.org/0000-0001-5791-9040>

Available at: http://www.int brazjurol.com.br/video-section/20220453_Poncel_et_al
Int Braz J Urol. 2023; 49 (Video #4): 271-2