

## Histological and Histochemical Changes of the Intestinal Mucosa at the Urothelial-Enteric Anastomotic Site

Marcos A. Castro, Ubirajara Ferreira, Mario H. Martins, Rafael M. Stoppiglia, N. Rodrigues Netto Jr.

*Division of Urology, State University of Campinas, UNICAMP, Campinas, Sao Paulo, Brazil*

---

### ABSTRACT

*Objective:* The incorporation of bowel segments for urinary tract reconstruction may induce intestinal mucosal changes with the development of metabolic, nutritional, gastrointestinal and carcinogenic complications. The early histological and histochemical changes of the intestinal mucosa in contact with the feces-urine mixture, are evaluated in the present study.

*Materials and Methods:* Twelve rats (operated group) were submitted to a vesico-colonic anastomosis, and 10 rats (control group) underwent a sham operation (the colon was opened and immediately sutured). On the operated group, the left colon was divided into 3 equal portions and the middle segment was used for the bladder-colonic anastomosis. After 20 weeks, the animals were sacrificed and the entire left colon in each group, as well as the bladder and the vesico-colonic anastomosis in the operated group, was removed. The proximal, middle (anastomotic site in the operated group and sutured portion in the control group) and distal colon were used for histological and histochemical studies.

*Results:* Metaplasia, chronic inflammatory process and fibrosis were significantly greater at the anastomotic site compared to the middle segment of the control group. There were no differences in both groups in terms of dysplasia, atrophy and hypertrophy either on the proximal, middle or anastomotic area and distal portion of the left colon. All animals in the operated group showed a reduced presence of sulfomucin and an increase in the sialomucin content.

*Conclusion:* The histological changes observed in this study may suggest a precancerous phenomenon.

*Key words:* urinary diversion; colonic urinary reservoirs; mucins; carcinogens; rats  
*Int Braz J Urol. 2006; 32: 222-7*

---

### INTRODUCTION

The incorporation of bowel segments for urinary tract reconstruction induces intestinal mucosal changes with the development of metabolic, nutritional, gastrointestinal and carcinogenic complications.

The association of urinary-colonic diversions, specially the ureterosigmoidostomy, and the higher incidence of colonic adenocarcinoma are well established and may be multifactorial (1).

There are several theories to explain the carcinogenesis of colon tumors following ureterosigmoidostomy. Some of these theories include the formation of nitrosamines by bacterially reduced urinary nitrate and endogenous amines in feces and urine mixture (2-4), chronic urothelial irritation by feces, epithelial instability at the anastomotic site (1), the presence of fresh colonic suture (1) and irritative changes of the colonic epithelium caused by the presence of feces-urine mixture (4-6).

A risk factor for neoplasms around the urinary-colonic anastomosis may be alterations of mucous glycoproteins in the surrounding colonic mucosa of the anastomosis. Studying these alterations would be of great value to find a marker of premalignant change in patients at risk of developing these colonic tumors (7).

The aim of this study is to assess the early histological and histochemical changes of the intestinal mucosa in contact with the feces-urine mixture.

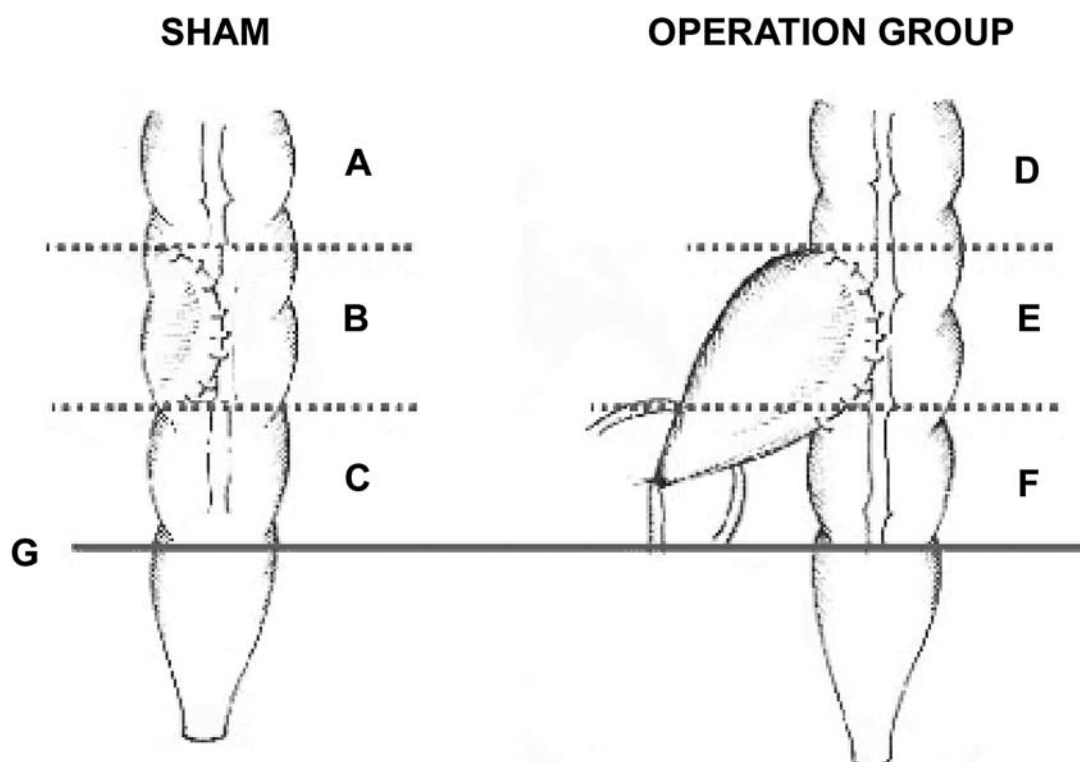
### MATERIALS AND METHODS

Two groups of adult female Wistar rats (Botucatu, Brazil) weighing 190 to 280g were used. All rats were fed with water ad libitum and standard rat chow.

All rats were anesthetized, after a 12-hour fast, by intraperitoneal injection of pentobarbital sodium (4 mg / 100g of body weight).

Ten rats in the first group (control group) underwent a sham operation (the middle part of the left colon was opened and immediately closed by a running 6-0 polyglycolic suture) (Figure-1).

In the second group (operated group), a vesico-colonic anastomosis was created in 12 rats, according to the ureterosigmoidostomy model already described in the literature (3,8). The left colon was divided into three equal portions of 1.8 cm (Figure-1) above the rectal peritoneal reflection. On the operated group, the middle portion was used for the bladder-colon anastomosis. First, the bladder neck was closed with 4-0 silk suture, the dome of the bladder was opened and a vesico-colonic fistula



**Figure 1** – Diagram of division of the proximal segments of the left colon above the peritoneal reflection used to collect tissue fragments on the rat's distal colon. Note the vesico-colonic anastomosis and the suture in the left colon. A = proximal colon; B = middle colon; C = distal colon; D = proximal colon; E = anastomotic site; F = distal colon e G = rectal peritoneal reflection.

was created by a running 6-0 polyglycolic suture (Figure-1).

Antibiotic therapy (cefalexin 1-3 mg / 100 g / day) was added to the drinking water and administered in the experiment.

After 20 weeks all animals were sacrificed and inspected grossly for colonic or bladder lesions. At this time, the body weight of the animals was not different. The entire left colon of the animals in both groups as well as the bladder-colon anastomosis in the operated group were removed in bloc for histological and histochemical studies.

For histological studies, the biopsy specimens were fixed in 10% formalin solution and imbedded in paraffin. Five micrometers thick sections were stained with hematoxylin-eosin for evaluation of the morphology of the epithelial cells and the lamina propria. The epithelial cell sections were examined for the presence of dysplasia and metaplasia. In the lamina propria the amount of fibrosis, and either acute or chronic inflammatory process, were registered. The muscularis propria was examined for atrophy and hypertrophy.

The histochemical studies performed were periodic acid-Schiff (PAS) and alcian blue (AB) stains for the evaluation of neutral mucin and the overall acid mucin content, respectively. The high iron-diamine alcian blue - pH 2.5 - (HIDAB) (7,9) was used to differentiate acid sulfomucins from sialomucins.

The variables were divided into six grades: moderately and mildly reduced or increase (for histochemical studies); and normal, mild, moderate or severe changes (histopathological analysis).

Two pathologists reviewed all slides. Results obtained were evaluated and the statistical differences were analyzed by the non-parametric Mann-Whitney test.

## RESULTS

There was no statistical difference on dysplasia in tissue sections between the two groups (Table-1). The metaplasia changes were significantly greater at the anastomosis site compared to the middle segment sutured on the control group ( $p < 0.05$ ) (Table-1).

Although the acute inflammatory process on the lamina propria had been greater in all the three intestinal segments of the animals in the operated group, no statistical differences were noted. The same results were seen with the chronic inflammatory process on the proximal and distal portions of the operated group. However, this process was significantly greater on the anastomotic area as compared to the middle segment of the control group ( $p < 0.05$ ) (Table-1) (Figure-2).

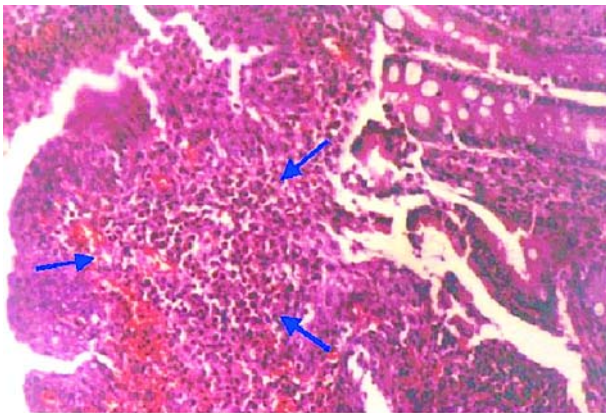
An interesting finding was the presence of mild fibrosis on the proximal and distal segments of the left colon in the operated group. An increased amount of fibrosis was registered at the anastomotic site when compared with the sham group ( $p < 0.05$ ) (Table-1). The muscle layers were normal in the operated group.

A significant reduction in the amount of acid and neutral mucins was noted at the anastomotic site of the operated group ( $p < 0.001$ ). In contrast, only a

**Table 1** – Presence of histological mucosal findings at the anastomotic area.

	Control Group	Operation Group
Dysplasia	0	+
Metaplasia	0	+++ ♣
Acute inflammatory process	+	++
Chronic inflammatory process	0	+++ ♣
Fibrosis	+	+++ ♣
Atrophy	0	0
Hypertrophy	0	0

0 = not present; + = middle change; +++ = severe change; ♣ = significant difference ( $p < 0.05$ ) (Mann Whitney U-test).



**Figure 2** – Histologic section of the anastomotic site taken from an animal showing marked chronic inflammatory process on the lamina propria, arrows (HE, X100).

mild amount of acid and neutral mucins was present in the proximal and distal segments of the left colon (Table-2) (Figure-3).

All animals in the operated group presented a decrease in the amount of sulfomucin and an increase in the sialomucin content in the left colon. However, this change in secretion of sulfomucin and sialomucin, was significant only at the anastomotic site ( $p < 0.05$ ) (Table-2) (Figure-3).

## COMMENTS

The mucosa of the intestinal segments used in the reconstruction of the urinary tract undergoes structural changes along time. The most important is the appearance of neoplasia, the incidence of colon

**Table 2** – Presence of histochemical mucosal findings at the anastomotic area.

Mucines	Control Group	Operation Group
Acid	0	↓↓ *
Neutral	0	↓↓ *
Sulfomucins	0	↓↓ ♣
Sialomucins	0	++ ♣

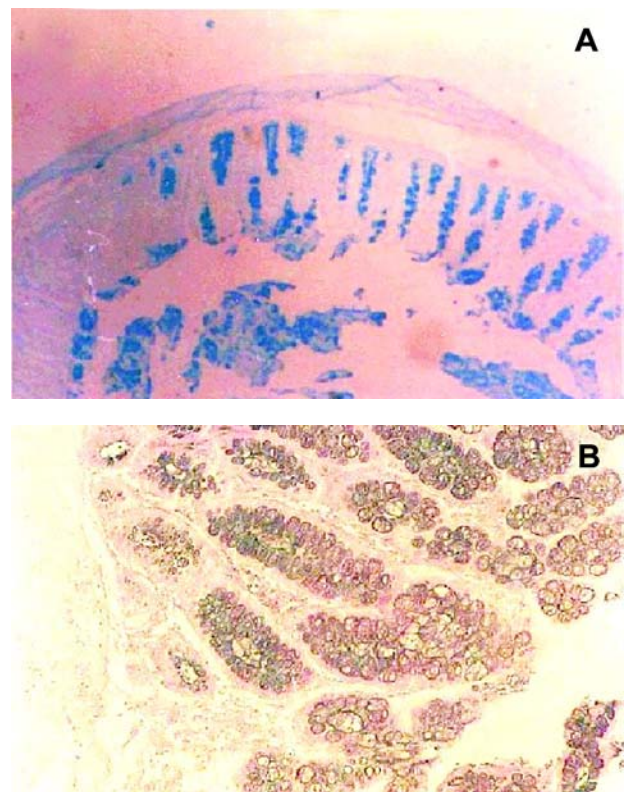
0 = not present; ↓↓ = reduced amount; ++ = moderate increase; ♣ = significant difference ( $p < 0.05$ , Mann Whitney U-test); \* = significant difference ( $p < 0.001$ , Mann Whitney U-test).

cancer in the area of the anastomosis is 100 to 500 times higher than in the general population (10-12). In humans, the latency period of the onset of tumors ranges from five to forty-five years, average twenty years (7).

Several theories have been proposed to explain the genesis of the tumors after ureterosigmoidostomy, but the presence of the mixture of urine and feces, the role of bacteria in production of N-nitrosamines, and changes in mucous secretion into the intestines, deserve special attention (7,13,14).

Under experimental conditions, the therapy with ascorbic acid has reduced the production of dimethyl-nitrosamines with no apparent reduction in the incidence of tumors (8).

The surge of cancer at the level of the ureterosigmoidostomy anastomosis is prevented by a



**Figure 3** – Histologic section of biopsy taken from the anastomotic site showing marked reduction of acid mucins in the goblet cells (A), (AB, X40), and an increase of sialomucins and a mild reduction of sulfomucins (B), (HIDAB, X100).

colostomy proximal to the anastomotic site, which may suggest the existence of fecal carcinogens eventually activated by the urine or by the urothelial epithelium (3).

Previous studies have shown that the intestinal mucosa in contact with the urine undergoes changes beginning three years after surgery (10,12). It is known that the rat lifespan ratio to human is estimated to be 1:30 (15).

The presence of dysplasia is expected after vesico-colonic anastomosis in rats (2,16). In our investigation the presence of dysplasia was not significantly different from the controls, which could possibly be attributed to the timing of the experiment. However, metaplasia was found in the animals of the operated group. Other experimental reports confirm this finding and have suggested the presence of an unstable, artificially produced borderline tissue between transitional cell epithelium and mucosal irritation (17,18). Also chronic inflammation in 15 children submitted to colon-ureterostomies has been reported and established as a precursor of malignancy (5). The same changes were found in the lamina propria, in the present study.

The overall presence of fibrosis was significantly greater at the anastomotic site of the operated group. This finding was also observed in ileo-colonic segments in rats, which perhaps reflects a chronic tissue repair due to aggression (12).

Mucins are high-molecular weight glycoproteins secreted and produced by the goblet cells of the gastrointestinal tract and have a protective effect on the gut. They may be categorized histochemically as neutral or acid and, according to their content of sialic acid or sulphate, the acid mucins are subdivided into sialomucins and sulphomucins.

The decrease in the content of acid and neutral mucins at the anastomotic area with AB and PAS staining was also observed elsewhere (19-21).

The histochemical changes of the content of the goblet cell mucin with the HIDAB staining demonstrated a shift on the standard distribution, that is, an increase on sialomucins and a great decrease of the sulfomucins at the anastomotic area forming the so-called "transitional mucosa". Some investigators suggested that the presence of sialomucins may be

primary or a precancerous phenomenon and not secondary to the tumor (7,22-25).

Although other reports claim that this shift on the sialic mucin content could represent only an unstable colon epithelium exposed to additional aggression, there is enough evidence that greater increases in sialomucin are related to higher risk of developing colon cancer (7,26-29).

Intensive research is required for a better understanding of this subject.

## CONCLUSION

The histological and histochemical changes observed in this study may suggest a precancerous phenomenon.

All urinary diversions that include bowel need regular evaluation, and, whenever possible, biopsies must be taken from the surrounding mucosa of the anastomosis for histological and histochemical analysis, looking for premalignant changes.

## CONFLICT OF INTEREST

None declared.

## REFERENCES

1. Gittes RF: Carcinogenesis in ureterosigmoidostomy. *Urol Clin North Am.* 1986; 13: 201-5.
2. Cohen MS, Hilz ME, Davis CP, Anderson MD: Urinary carcinogen [nitrosamine] production in a rat animal model for ureterosigmoidostomy. *J Urol.* 1987; 138: 449-52.
3. Crissey MM, Steele GD, Gittes RF: Rat model for carcinogenesis in ureterosigmoidostomy. *Science.* 1980; 207: 1079-80.
4. Kalble T, Tricker AR, Mohring K, Berger MR, Geiss H, Staehler G: The role of nitrate, nitrite and N-nitrosamines in carcinogenesis of colon tumours following ureterosigmoidostomy. *Urol Res.* 1990; 18: 123-9.
5. Moorcraft J, DuBoulay CE, Isaacson P, Atwell JD: Changes in the mucosa of colon conduits with particular reference to the risk of malignant change. *Br J Urol.* 1983; 55: 185-8.

6. Starling JR, Uehling DT, Gilchrist KW: Value of colonoscopy after ureterosigmoidostomy. *Surgery*. 1984; 96: 784-90.
7. Shimamoto C, Hirata I, Takao Y, Takiuchi H, Morikawa H, Nakagawa Y, et al.: Alteration of colonic mucin after ureterosigmoidostomy. *Dis Colon Rectum*. 2000; 43: 526-31.
8. Shands C 3rd, McDougal WS, Wright EP: Prevention of cancer at the urothelial enteric anastomotic site. *J Urol*. 1989; 141: 178-81.
9. Spicer SS: Diamine methods for differentiating mucosubstances histochemically. *J Histochem Cytochem*. 1965; 13: 211-34.
10. Philipson BM, Kock NG, Hockenstrom T, Norlen LJ, Ahren C, Hansson HA: Ultrastructural and histochemical changes in ileal reservoir mucosa after long-term exposure to urine. A study in patients with continent urostomy (Kock pouch). *Scand J Gastroenterol*. 1986; 21: 1235-44.
11. Carlen B, Willen R, Mansson W: Mucosal ultrastructure of continent cecal reservoir for urine and its ileal nipple valve 2-9 years after construction. *J Urol*. 1990; 143: 372-6.
12. Davidsson T, Carlen B, Bak-Jensen E, Willen R, Mansson W: Morphologic changes in intestinal mucosa with urinary contact—effects of urine or disuse? *J Urol*. 1996; 156: 226-32.
13. Habs M, Schmahl D: Diet and cancer. *J Cancer Res Clin Oncol*. 1980; 96: 1-10.
14. Stewart M, Hill MJ, Pugh RC, Williams JP: The role of N-nitrosamine in carcinogenesis at the ureterocolic anastomosis. *Br J Urol*. 1981; 53: 115-8.
15. Peckham JC: Experimental oncology. In: Baker HJ, Lindsey JR, Weisbroth SH, The laboratory rat. Orlando, Academic Press. 1980; pp. 119-46.
16. Daher N, Gautier R, Abourachid H, Decaens C, Bara J: Rat colonic carcinogenesis after ureterosigmoidostomy: pathogenesis and immunohistological study. *J Urol*. 1988; 139: 1331-6.
17. Weber TR, Westfall SH, Steinhardt GF, Webb L, Sotelo-Avila C, Connors RH: Malignancy associated with ureterosigmoidostomy: detection by mucosa ornithine decarboxylase. *J Pediatr Surg*. 1988; 23: 1091-4.
18. Miersch WD, Vogel J: Induction of carcinoma at ureterosigmoid anastomosis—with and without faecal stream. *Br J Urol*. 1992; 69: 499-506.
19. Rubio CA, Rivera F: Quantification of acid mucins in the descending colon of rats having simultaneously growing colonic tumors. *APMIS*. 1991; 99: 993-6.
20. Shamsuddin AK, Trump BF: Colon epithelium. I. Light microscopic, histochemical, and ultrastructural features of normal colon epithelium of male Fischer 344 rats. *J Natl Cancer Inst*. 1981; 66: 375-88.
21. Schauffert MD, Simoes MJ, Juliano Y, Novo NF, Ortiz V: Long term histomorphometric evaluation of the villous and ileal goblet cells after ileocystoplasty in female rats. *Int Braz J Urol*. 2000; 26: 91-6.
22. Filipe MI, Branfoot AC: Abnormal patterns of mucus secretion in apparently normal mucosa of large intestine with carcinoma. *Cancer*. 1974; 34: 282-90.
23. Filipe MI: Mucous secretion in rat colonic mucosa during carcinogenesis induced by dimethylhydrazine. A morphological and histochemical study. *Br J Cancer*. 1975; 32: 60-77.
24. Dawson PM, Habib NA, Rees HC, Williamson RC, Wood CB: Influence of sialomucin at the resection margin on local tumour recurrence and survival of patients with colorectal cancer: a multivariate analysis. *Br J Surg*. 1987; 74: 366-9.
25. Wood CB, Dawson PM, Habib NA: The sialomucin content of colonic resection margins. *Dis Colon Rectum*. 1985; 28: 260-1.
26. Mori M, Shimono R, Adachi Y, Matsuda H, Kuwano H, Sugimachi K, et al.: Transitional mucosa in human colorectal lesions. *Dis Colon Rectum*. 1990; 33: 498-501.
27. Isaacson P, Attwood PR: Failure to demonstrate specificity of the morphological and histochemical changes in mucosa adjacent to colonic carcinoma (transitional mucosa). *J Clin Pathol*. 1979; 32: 214-8.
28. Strachan JR, Rees HC, Williams G: Histochemical changes after ureterosigmoidostomies and colonic diversion. *Br J Urol*. 1985; 57: 700-2.
29. Strachan JR, Matthews J, Rees HC, Cooke T: Kinetic changes in experimental colonic urinary diversion. *Br J Surg*. 1987; 74: 1046-8.

---

*Accepted after revision:  
January 4, 2006*

---

**Correspondence address:**

Dr. Ubirajara Ferreira  
Rua Vital Brasil, 250, 2o. Andar  
Departamento de Cirurgia / Urologia  
Cidade Universitária Zeferino Vaz - Barão Geraldo  
Campinas, SP, 13083-888, Brazil  
Fax: + 55 19 3788-7481  
E-mail: ubirafer@uol.com.br