

## Quantification of Myocardial Ischemia: Comparison between Myocardial SPECT and $^{13}\text{NH}_3$ PET/CT

Angelica Mazzeletti,<sup>1</sup> Francesco Dondi,<sup>1</sup> Maria Gazzilli,<sup>1</sup> Raffaele Giubbini<sup>2</sup>

University of Brescia and Spedali Civili Brescia - Nuclear Medicine,<sup>1</sup> Brescia - Italy  
Azienda Socio Sanitaria Territoriale degli Spedali Civili di Brescia,<sup>2</sup> Brescia - Italy

### Introduction

Myocardial perfusion is a very important tool to diagnose and quantify hypoperfusion related to coronary artery disease (CAD). Single-photon emission computed tomography (SPECT) myocardial perfusion imaging (MPI) is a widely available nuclear medicine imaging tool. Cardiac  $^{13}\text{N}$ -ammonia positron emission tomography/computed tomography ( $^{13}\text{NH}_3$  PET/CT) has increased its capability to provide quantitative measures of myocardial blood flow at rest and under stress, as well as of coronary flow reserve (CFR), in addition to better image quality.

### Case report

A 61-year-old male patient with a history of hypertension, dyslipidemia and previous atrial fibrillation underwent a kidney transplant in 2001 because of post-pyelonephritic chronic kidney disease.

In 2007, in the presence of typical angina with anterior ST-depression, he underwent coronary angiography, which showed critical stenosis in the Left Anterior Descending Artery (LAD). He also underwent percutaneous transluminal coronary angioplasty (PTCA) and stenting.

From 2007 to 2017 he remained asymptomatic and all cardiac examinations he underwent did not reveal any abnormalities.

### Keywords

Myocardial Ischemia/diagnosis; Coronary Artery Disease/diagnostic imaging; Tomography Emission-Computed Single-Photon/methods; Positron-Emission Tomography/method.

In January 2018, a treadmill stress test demonstrated ST-depression in the anterior and lateral leads that appeared only during the recovery and disappeared after 3 minutes. Therefore, he was submitted to a pharmacological stress-rest SPECT-MPI using a CZT gamma camera; an intravenous infusion of 400  $\mu\text{g}$  regadenoson was performed, followed by the  $^{99\text{m}}\text{Tc}$ -tetrofosmin injection at 7 minutes. Stress acquisition started 15-25 minutes after the radiotracer administration. Rest injection was administered 2 hours later, and images were obtained about 15-30 minutes later. Both stress and rest studies were acquired in list mode for 9 minutes using a gated 16 frame-per-cycle acquisition.

The images showed a small hypoperfusion area in the lateral wall, while it was not possible to evaluate the inferior wall because of the presence of artifacts due to persistent diaphragmatic attenuation (Figure 1). The inducible ischemia in the LCX coronary territory was reported as 16%. CFR was also evaluated during the test : it was normal in the LAD and CDX territory, whereas it was 1.58 in the LCX territory.

A subsequent  $^{13}\text{NH}_3$  PET/CT study was performed to better define the perfusion and coronary blood flow measurement of the left ventricular inferior wall (Figure 2). The examination was performed again at stress and at rest with 400  $\mu\text{g}$  of regadenoson and the dose was 370 MBq of  $^{13}\text{NH}_3$  both at stress and at rest. The PET studies were acquired in 3D and list mode for 10 minutes, starting acquisition immediately before  $^{13}\text{NH}_3$  injection using a Discovery PET/CT 690 (GE Healthcare, Milwaukee, Wisconsin, USA). A low-dose CT attenuation correction (140 kV, 120-150 mA) was acquired for optimal imaging position on a CT scout scan and for attenuation correction. The examination result was an increased area of inducible ischemia in the LCX coronary territory of 46%. The global CFR was also evaluated during the PET/

**Mailing Address: Angelica Mazzeletti**

Piazzale Spedali Civili, 1. Postal Code: 25123, Brescia – Italy.  
E-mail: mazzolettiantgelica@gmail.com

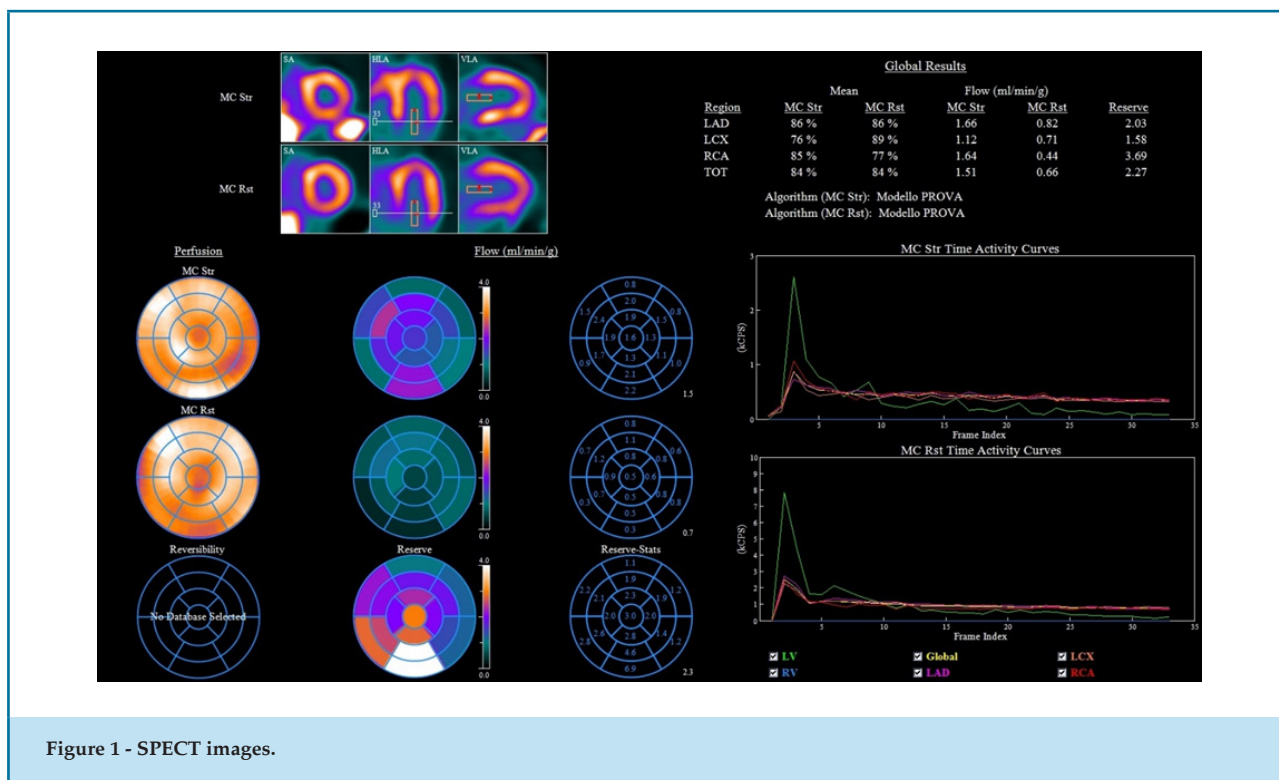


Figure 1 - SPECT images.

CT test : the values were normal in the LAD and CDX territories, but pathological in the LCX territory (1,45). The patient was asymptomatic during the examination and there were no alterations in the ECG.

## Discussion

Coronary anatomy and myocardial blood flow have been identified as independent prognostic factors in patients with stable CAD.<sup>1</sup> Frequently, these anatomical and physiological assessments are used as complementary techniques for risk stratification and clinical decision-making.<sup>2</sup> Nuclear methods such as SPECT with  $^{99m}\text{Tc}$ -tetrofosmin and cardiac PET/CT with  $^{13}\text{NH}_3$  are among the most frequently used tools for myocardial perfusion assessment. However, some disadvantages of the SPECT imaging related to the presence of image artifacts, long duration of the examination and the possibility of underestimating the ischemic severity in patients with multivessel disease should be considered.<sup>3</sup> These negative issues can be avoided by using cardiac PET/CT study, which has shown high accuracy and enables the quantification of perfusion and determination of CFR, which means high sensitivity and high predictive value in coronary artery disease detection and small vessel disease.

Myocardial perfusion PET is an important and appropriate test for patients in which CFR quantification is useful for patient management.<sup>4</sup> CFR has an important impact on the prognosis of the patient: an analysis of the association between CFR and cardiac mortality suggests an excellent prognosis for a CFR > 2 and a steady increase in cardiac mortality for a CFR lower than this value.<sup>5</sup>

Much attention now is being devoted to the possibility of evaluating CFR with CZT-SPECT. This technique is very promising and recently, the WATERDAY study results were published demonstrating that the sensitivity, specificity, accuracy, positive and negative predictive value of CZT-SPECT were, respectively, 83.3, 95.8, 93.3, 100 and 85.7% for the detection of ischemia in comparison with  $^{15}\text{O}$ -H<sub>2</sub>O PET.<sup>6</sup> Unfortunately, in our case, the results of CZT-SPECT images were not completely accurate because of the presence of diaphragmatic attenuation and the identification of a small area of inducible ischemia in the LCX territory.

Therefore, it was suggested to the patient to undergo a  $^{13}\text{NH}_3$  PET/CT study, which was able to better define the results of the quite unclear SPECT MPI test. The PET scan result showed an important area of inducible ischemia in the LCX coronary territory (46%) and the CFR of this territory was estimated at 1.45, which confirmed

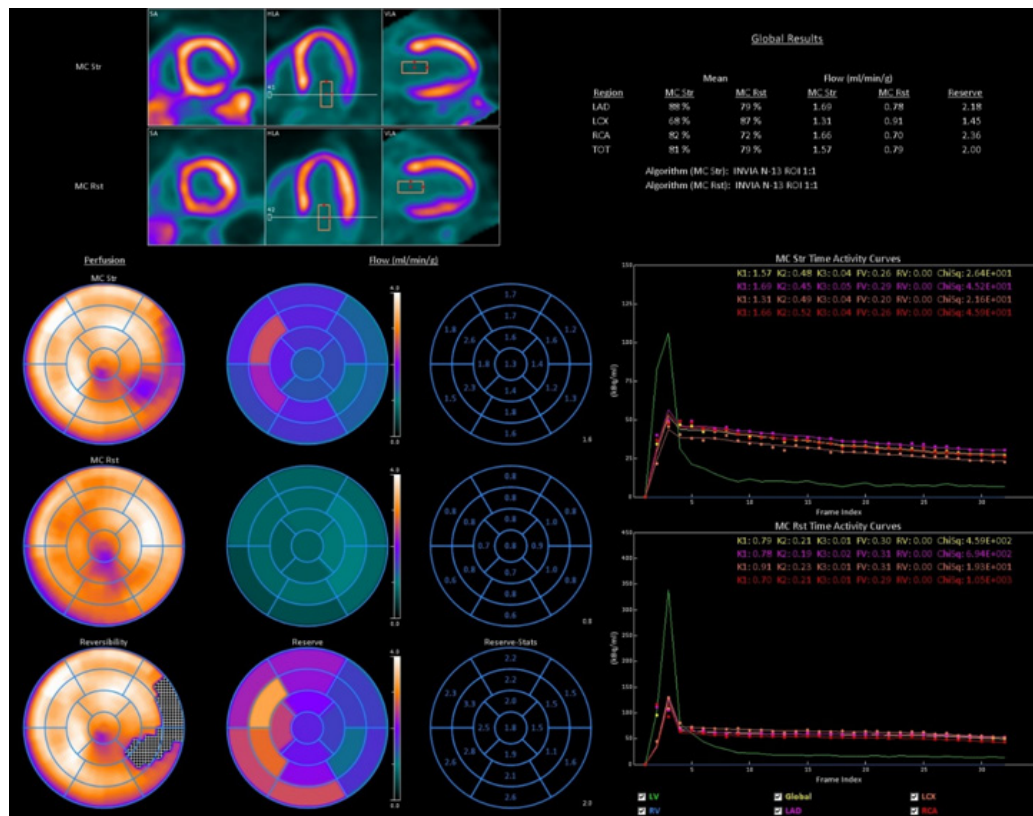


Figure 2 - <sup>13</sup>N-NH<sub>3</sub> PET/CT images.

the significant diagnosis of ischemia: this information has an important impact on patient prognosis and management. We believe that this case highlights the need to perform more studies evaluating the role of CZT-SPECT in myocardial blood flow reserve assessment with a larger number of subjects using attenuation and scatter correction. Until further proven, PET results should be considered the gold standard for the quantification of myocardial blood flow.

### Author contributions

Conception and design of the research: Mazzoletti A, Mesquita CT, Giubbini R. Acquisition of data: Mazzoletti A, Dondi F. Analysis and interpretation of the data: Mazzoletti A, Dondi F, Giubbini M. Statistical analysis: Giubbini M. Writing of the manuscript: Mazzoletti A, Dondi F. Critical revision of the manuscript for intellectual content: Mesquita CT, Giubbini R.

### Potential Conflict of Interest

No potential conflict of interest relevant to this article was reported.

### Sources of Funding

There were no external funding sources for this study.

### Study Association

This study is not associated with any thesis or dissertation work.

### Ethics approval and consent to participate

This article does not contain any studies with human participants or animals performed by any of the authors.

## References

1. Douglas PS, Hoffmann U, Patel MR, Mark DB, Al-Khalidi HR, Cavanaugh B, et al. Outcomes of anatomical versus functional testing for coronary artery disease. *N Engl J Med* 372(14):1291–300.
2. Cremer P, Hachamovitch R, Tamarappoo B. Clinical decision making with myocardial perfusion imaging in patients with known or suspected coronary artery disease. *Semin Nucl Med* 44(4):320–9.
3. Yoshinaga K, Katoh C, Manabe O, Klein R, Naya M, Sakakibara M, et al. Incremental diagnostic value of regional myocardial blood flow quantification over relative perfusion imaging with generator-produced rubidium-82 PET. *Circ J*. 2011;75(11):2628–34.
4. American Society of Nuclear Cardiology and Society of Nuclear Medicine and Molecular Imaging Joint Statement on the Clinical Indications for Myocardial Perfusion PET. *J Nucl Med*, 2016;57(10):1654–6.
5. Murthy VL, Lee BC, Sitek A, Naya M, Moody J, Polavarapu V, et al. Comparison and prognostic validation of multiple methods of quantification of myocardial blood flow with  $^{82}\text{Rb}$  PET. *J Nucl Med*. 2014;55(12):1952–8.
6. Agostini D, Roule V, Nganoa C, Roth N, Baavour R, Parienti JJ, et al. First validation of myocardial flow reserve assessed by dynamic ( $^{99\text{m}}$ ) Tc-sestamibi CZT-SPECT camera: head to head comparison with ( $^{15}$ ) O-water PET and fractional flow reserve in patients with suspected coronary artery disease. The WATERDAY study. *Eur J Nucl Med Mol Imaging*. 2018;45(7):1079–90.

