

## CASE REPORT

## Catheter Ablation in Neonate with Heart Failure Due to Incessant Atrioventricular Reentrant Tachycardia

Sissy Lara de Melo,<sup>1</sup> José Nilo de Carvalho Neto,<sup>2</sup> Nathalia Maria Segovia Monge, Italo Bruno dos Santos Sousa, Cristiano Faria Pisani,<sup>3</sup> Mauricio Scanavacca<sup>4</sup>

Universidade de São Paulo - Instituto do Coração, São Paulo, SP – Brazil

### Abstract

The atrioventricular (AV) reentrant tachycardia (AVRT) is the most common cause of supraventricular tachycardia (SVT) in the young pediatric population. Some newborns might present with congestive heart failure and require interventional treatment. Catheter ablation in small infants (<6 months and <5 kg) is still poorly performed and controversial due to high complications rate in this group of patients.<sup>1</sup> We report a case of a 28 days old infant (3,5 kg) with a drug-refractory left accessory pathway mediated tachycardia and severe hemodynamic compromise, who underwent catheter ablation. Radiofrequency ablation should be part of the therapeutic arsenal in a context of drug-resistant supraventricular tachycardia with hemodynamic compromise, despite the greater risks of complications in this special population.

### Case Report

A female neonate, 13 days old, diagnosed with fetal tachycardia, without registries of tachyarrhythmias after birth and no 12-lead ECG record at delivery, was admitted to the emergency department with incessant supraventricular tachycardia, with a heart rate of 250 beats per minute (bpm) (Figure 1).

At the admission in the intensive care unit, adenosine (0.05 mg/kg) was unsuccessfully administered twice.

### Keywords

Newborn; Supraventricular Tachycardia; Heart Failure; Catheter ablation.

So, electrical cardioversion was performed (0.5J/kg + 1J/kg), with immediate interruption of the arrhythmia, however with prompt recurrence. During sinus rhythm, it was possible to identify ventricular pre-excitation. Echocardiogram showed a left ventricular ejection fraction (LVEF) of 46%.

Due to hemodynamic instability, orotracheal intubation was performed and dopamine started. Loading dose of amiodarone (5mg/kg) was administered in 40 minutes, followed by a maintenance infusion of 10mg/kg daily. In the following days, the patient evolved with acute kidney failure and hydroelectrolytic disturbance. In this context, the newborn developed severe bradycardia requiring the interruption of the amiodarone infusion and peritoneal dialysis. Thereafter, epinephrine and dobutamine were administered.

Amiodarone was restarted after the correction of the hydroelectrolytic disorders, at a dose of 5 mg/kg/day, with dose progression over the next days, reaching up to 30 mg/kg/day. It was not possible to prescribe other available antiarrhythmic drugs due to the ventricular dysfunction, and to the need of vasoactive drugs. Despite that, the 28-day old infant evolved with incessant AV tachycardia, being then decided to attempt RF ablation.

The electrophysiological study was performed after 8h of fasting and under general anesthesia. A single standard 5 French, 4-millimetre tip deflectable quadripolar catheter (5 FR RF – Medtronic Marinr steerable catheter) was



Sissy Lara de Melo, MD, PhD  
Assistant Physician of the Arrhythmia Group  
Incor - Instituto do Coração, Hospital das  
Clínicas, FMUSP

### Mailing Address: Sissy Lara de Melo

Universidade de São Paulo - Instituto do Coração - Arritmia  
Av. Dr. Enéas de Carvalho Aguiar, 44. Postal Code: 05403-000, São Paulo, SP – Brazil.  
Email: sissy.lara@incor.usp.br

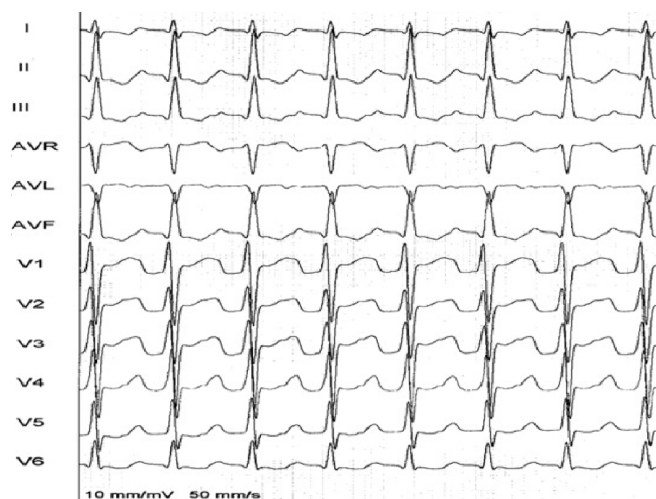


Figure 1 – Electrocardiogram of the neonate showing supra-ventricular tachycardia at a heart rate of 250bpm.

introduced through the left femoral vein for mapping and ablation purposes. Tachycardia was interrupted during programmed stimulation and revealed a left posterior accessory-pathway pre-excitation pattern on the surface EKG (Figure 2). The foramen ovale was used for left atrium access (Figure 3). After administration of 100 units per kilogram of intravenous heparin, RF application was successfully delivered at the targeted site, with immediate conduction block through the accessory pathway (Figure 4). RF application was maintained for one minute with 30W. There were no intra-procedural complications. Right bundle branch block occurred due to mechanical trauma with spontaneous recovery.

During the following hours, the hemodynamic condition improved markedly. The neonate was extubated and inotropic drugs were discontinued after 72h. Patient was discharged 6 days later. No more tachycardias or pre-excitation recurrence have been registered so far. The child remains with no arrhythmias, without pharmacological treatment, 6 years after the procedure. EKG shows sinus rhythm and Echocardiogram has normal ventricular function without segmental lesions.

## Discussion

The incidence of tachycardias in the neonatal period is between 1% and 5%.<sup>1,2</sup> AVRT and atrial flutter account for 90% of the fetal and neonatal tachyarrhythmias.<sup>3</sup> In most of these cases pharmacological and eventually

electrical cardioversion may be sufficient to obtain satisfactory clinical control. When the arrhythmia recurs, its frequency decreases in the first year of life (90% of patients), and invasive interventions are rarely needed.<sup>4</sup>

It is important to take into account that supraventricular tachycardia may be unrecognized in newborns until heart failure (HF) symptoms emerge; thus, neonates may present a decrease in LV function, or even cardiogenic shock if the correct diagnosis is not given.<sup>5</sup> In this case, despite the diagnosis of fetal tachycardia, an adequate investigation was not performed after birth, and the newborn was discharged without EKG. The SVT diagnosis was only obtained on the 13th day of life, when the child was taken to the emergency room in the context of cardiogenic shock.

To prevent recurrence, antiarrhythmic prophylaxis is recommended during the first year of life. Digoxin or propranolol are generally considered as the initial antiarrhythmic therapy for concealed accessory pathways. In case of first-line drugs failure, class IA (quinidine), class IC (flecainide), or class III (amiodarone or sotalol) drugs can be considered. In manifest accessory pathways, oral propafenone is reasonable for ongoing management in patients without structural or ischemic heart diseases. Oral amiodarone may be considered in patients with AVRT in whom propafenone is ineffective or contraindicated.<sup>6</sup>

The first reports demonstrating safety and efficacy of RF ablation in children were published by the Pediatric

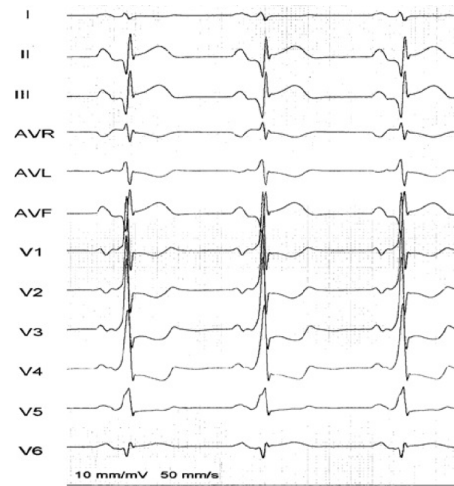
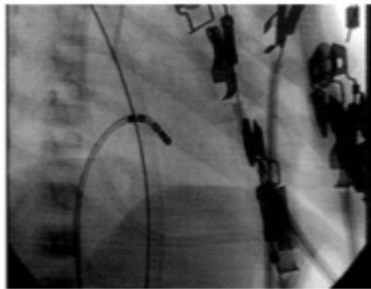


Figure 2 – Post cardioversion ECG in sinus rhythm showing left side ventricular pre-excitation.

Right Anterior Oblique View



Left Anterior Oblique View

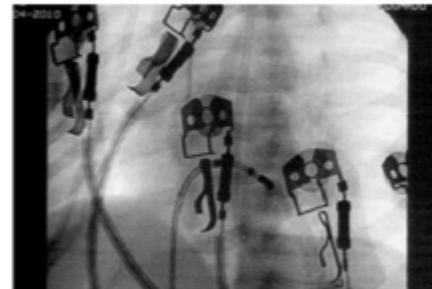


Figure 3 – Right and left oblique fluoroscopic view showing ablation catheter on the mitral annulus accessed through patent foramen ovale.

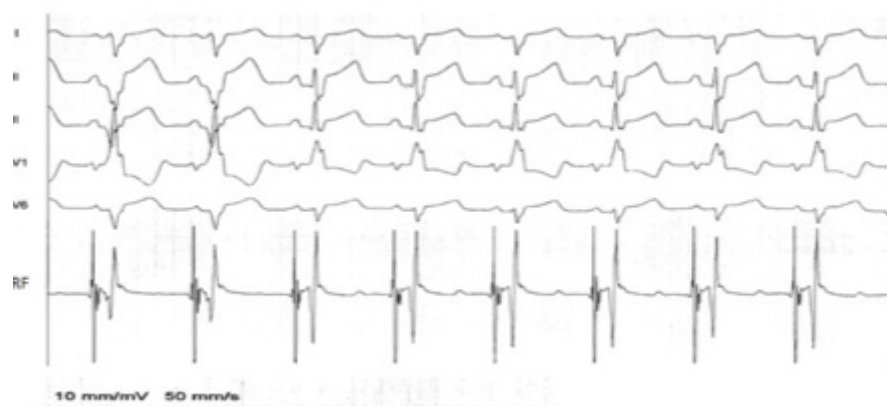


Figure 4 – Surface ECG and endocavitary bipolar signal at the tip of ablation catheter (RF) showing pre-excitation elimination (3rd QRS complex) with maintenance of the mechanical right bundle branch block.

Electrophysiology Society in 1994.<sup>1</sup> In recent periods, publications have shown an evolution in the success rate and a decrease in the number of complications.<sup>7-15</sup>

According to the 2016 HRS SVT guideline, ablation is recommended for documented SVT, recurrent or persistent, when medical therapy is either not effective or is associated with intolerable adverse effects. One must take into account that for very young children, the threshold for ineffectiveness and intolerability should be higher.

Death and major complications are rare, usually related to underlying heart diseases, lower patient weight, greater number of RF applications, and left-sided procedures.<sup>1</sup>

In general, radiofrequency ablation in small infants (less than 5 kg and younger than 6 months of age) should be reserved for life threatening, or refractory arrhythmias, such as the presented case.<sup>1,6</sup>

In conclusion, systematic investigation and a close follow-up is needed in newborns diagnosed with fetal tachycardia. In specific cases, radiofrequency ablation should be considered as the therapeutic approach, having in mind the greater risks of complications in this population.

## References

- Saul JP, Kanter RJ, Abrams D, Asirvatham S, Cohen YB, Blaufox AD, et al. PACES/HRS expert consensus statement on the use of catheter ablation in children and patients with congenital heart disease. *Heart Rhythm*. 2016 Jun;13(6):e251-89.
- Ban JE. Neonatal arrhythmias: diagnosis, treatment, and clinical outcome. *Korean J Pediatr*. 2017 Nov; 60(11):344-52.
- Jaeggi E, Öhman A. Fetal and Neonatal Arrhythmias. *Clin Perinatol*. 2016 Mar;43(1):99-112.
- Cohen MI, Triedman JK, Cannon BC, Davis AM, Drago F, Janousek J, et al. PACES/HRS Expert Consensus Statement on the Management of the Asymptomatic Young Patient with a Wolff-Parkinson-White (WPW, Ventricular Preexcitation) Electrocardiographic Pattern. *Heart Rhythm*. 2012 Jun;9(6):1006-24.
- Gopinathannair R, Etheridge SP, Marchlinski FE, Spinale FG, Lakkireddy D, Olshansky B. Arrhythmia-Induced Cardiomyopathies: Mechanisms, Recognition, and Management. *J Am Coll Cardiol*. 2015 Oct 13;66(15):1714-28.
- Brugada J, Blom M, Brugada G, Lundqvist C, Deanfield J, Janousek J, et al. Pharmacological and non-pharmacological therapy for arrhythmias in the pediatric population: EHRA and AEPIC-Arrhythmia Working Group joint consensus statement. *Europace*. 2013 Sep;15(9):1337-82
- Sahin GT, Ozturk E, Kasar T, Guzeltas A, Ergul Y. Sustained tachyarrhythmia in children younger than 1 year of age: Six year single-center experience. *Pediatr Int*. 2018 Feb;60(2):115-121.
- AN HS, Choi EY, Kwon BS, Kim GB, Bae EJ, Noh C, et al. Radiofrequency Catheter Ablation for Supraventricular Tachycardia: A Comparison Study of Children Aged 0-4 and 5-9 Years. *Pacing Clin Electrophysiol*. 2013 Dec;36(12):1488-94.
- Backhoff D, Klehs S, Muller MJ, Schneider H, Kriebel T, Paul T, et al. Radiofrequency Catheter Ablation of Accessory Atrioventricular Pathways in Infants and Toddlers ≤ 15 kg. *Pediatr Cardiol*. 2016 Jun;37(5):892-8.
- Svintsova LI, Popov SV, Kovalev IA. Radiofrequency ablation of drug-refractory arrhythmias in small children younger than 1 year of age: single-center experience. *Pediatr Cardiol*. 2013 Aug; 34(6):1321-9.
- Akdeniz C, Ergul Y, Kiplapinar N, Tuzcu V. Catheter ablation of drug resistant supraventricular tachycardia in neonates and infants. *Cardiol J*. 2013; 20(3):241-6.
- Turner CJ, Lau KC, Sholler GF. Outcomes of interventional electrophysiology in children under 2 years of age. *Cardiol Young*. 2012 Oct; 22(5):499-506.
- Jiang HE, Li XM, Li YH, Zhang Y, Liu HJ. Efficacy and Safety of Radiofrequency Catheter Ablation of Tachyarrhythmias in 123 Children Under 3 Years of Age. *Pacing Clin Electrophysiol*. 2016 Aug; 39(8):792-6.
- Femenía F, Sarquella-Brugada G, Brugada J. Single-catheter radiofrequency ablation of a permanent junctional reciprocating tachycardia in a premature neonate. *Cardiol Young*. 2012 Oct;22(5):606-9.
- Karmegeraj B, Namdeo S, Sudhakar A, Krishnan V, Kunjukutty R, Vaidyanathan B. Clinical presentation, management, and postnatal outcomes of fetal tachyarrhythmias: A 10-year single-center experience. *Ann Pediatr Card* 2018;11(1):34-9.

## Potential Conflict of Interest

No potential conflict of interest relevant to this article was reported.

## Sources of Funding

There were no external funding sources for this study.

## Study Association

This study is not associated with any thesis or dissertation work.

## Author contributions

Conception and design of the research: Melo, SL.. Acquisition of data: Sousa, IBS; Melo, SL. Writing of the manuscript: Melo, SL; Carvalho Neto, JN; Monge, NMS. Critical revision of the manuscript for intellectual content: Scanavacca, MI; Pisani, CF; Melo, SL.

## Ethics approval and consent to participate

This article does not contain any studies with human participants or animals performed by any of the authors.

