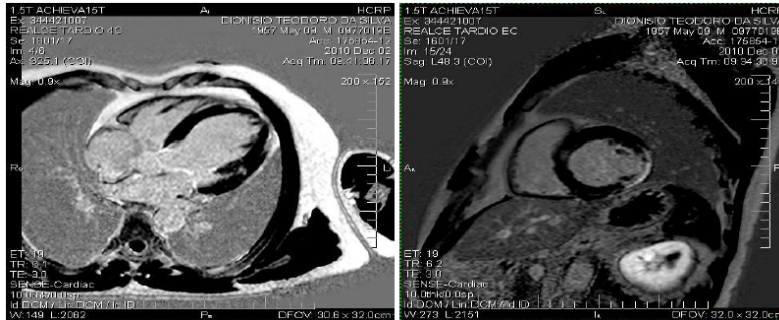


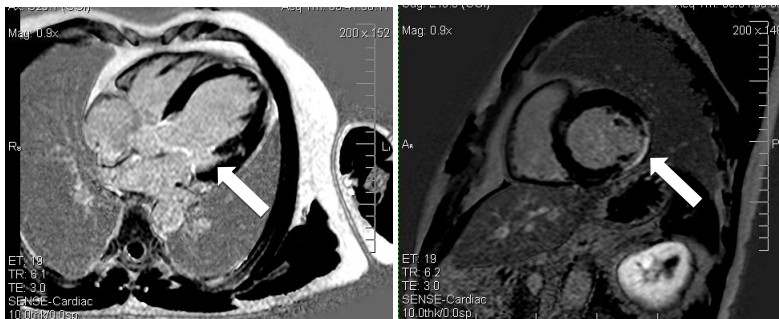In the March / April (2018) issue vol. 31(2), p. 183

In the manuscript “Chagas Disease Cardiomyopathy”, DOI number : 10.5935/2359-4802.20180011, published in the International Journal of Cardiovascular Sciences, 2018;31(2)173-189, on page: 183, Figure 5 – Delayed enhanced images where fibrosis can be seen as the white area inserted in the (dark) muscle, indicated by arrows. Left panel shows a small mesomyocardial area in the LV lateral wall in a four-chambered image. Right panel shows extensive transmural impairment of the posterolateral wall.

Where it read:



Now it reads:



DOI: 10.5935/2359-4802.20190019



This is an open-access article distributed under the terms of the Creative Commons Attribution License