

CASE REPORT

Coxiella Burnetti Infective Endocarditis – Detection and Cure

Manuel Martins Barbosa,¹ Carla Dias,¹ Elsa Araújo,¹ Raquel Costa¹

Unidade Local de Saúde do Alto Minho EPE, Viana do Castelo – Portugal

Introduction

Infective endocarditis (IE) is one of the first diagnostic hypotheses for patients admitted for acute heart failure and evidence of infection. Blood samples are collected for culture, and empiric, broad-spectrum antimicrobial therapy is initiated. Emergent cardiac surgery may be required depending on the severity of the case.

These procedures reduce bacteremia and improve clinical condition, which, in turn, may lead to discontinuation of diagnostic investigation in the presence of blood culture-negative endocarditis. Some of these patients, however, will have another episode of endocarditis.

This is typically seen in the infection by *Coxiella burnetii* (*C. burnetii*), a rare cause of blood culture-negative endocarditis, characterized by recurrent IE and valve dysfunction until the correct diagnosis is established. The condition is recognized by the combined analysis of epidemiological, clinical, serological, and imaging data, with emphasis to echocardiography. The infection is effectively treated only with a long treatment period with hydroxychloroquine and doxycycline.

We present two cases of IE which underwent multiple surgeries before the diagnosis was established and a literature review to understand the difficulty in diagnosing and treating in time these patients.

Case 1

Male patient aged 67 years, with type 2 diabetes mellitus, arterial hypertension, obesity and severe

aortic stenosis. At the age of 64, the patient underwent elective surgery for placement of Trifecta® bioprosthetic valve. Less than ten months after the surgery, the patient required reintervention for acute severe aortic insufficiency caused by IE and was started on empiric treatment with gentamicin and vancomycin. The patient took metformin, ramipril and bisoprolol. From the epidemiological point of view, the patient had contact with goats during adolescence.

The patient sought emergency care for dyspnea on exertion with progressive worsening and night sweating for one week. At physical examination, the patient had warm skin, sweating, regular tachycardia of 110 beats per minute (bpm), blood pressure (BP) of 135/73mmHg and axillary temperature of 38.2°C. No other relevant findings were detected, such as embolic phenomena or splenomegaly. The patient reported no recent dental or endoscopic procedures.

The patient presented hemolytic anemia, increased inflammatory markers and acute renal injury (Table 1). Transthoracic echocardiography (TTE) and transesophageal echocardiography (TEE) were performed, showing new acute severe aortic insufficiency with partial dehiscence of the prosthetic valve (Figure 1). Blood culture was performed and empiric therapy with gentamicin and vancomycin was initiated.

The patient was screened for blood culture-negative endocarditis, including serology for the detection of *C. burnetii*. The serology was positive for acute infection, with phase I IgM antibody 1:512 and phase I IgG antibody 1:512, and phase II IgM antibody < 1:32 and phase II IgG antibody 1:512 (Table 1).

The definite diagnosis of IE was established based on modified Duke criteria, with one major criterion (new valve dehiscence) and three minor criteria (fever >38°C, predisposing valvular abnormality, serological levels of *C. Burnetii* that do not meet the major criteria).

Keywords

Endocarditis; *Coxiella burnetii*; Q Fever; Heart Valve Diseases; Echocardiography/methods; Valvular Prosthesis; Antibiotics/therapeutic use.

Mailing Address: Manuel Martins Barbosa

Unidade Local de Saúde do Alto Minho EPE - Medicina 2
Rua Conde de Bertiandos, S/N. Postal Code: 4990-041, Ponte de Lima – Portugal
E-mail: martinsbarbosa.manuel@gmail.com

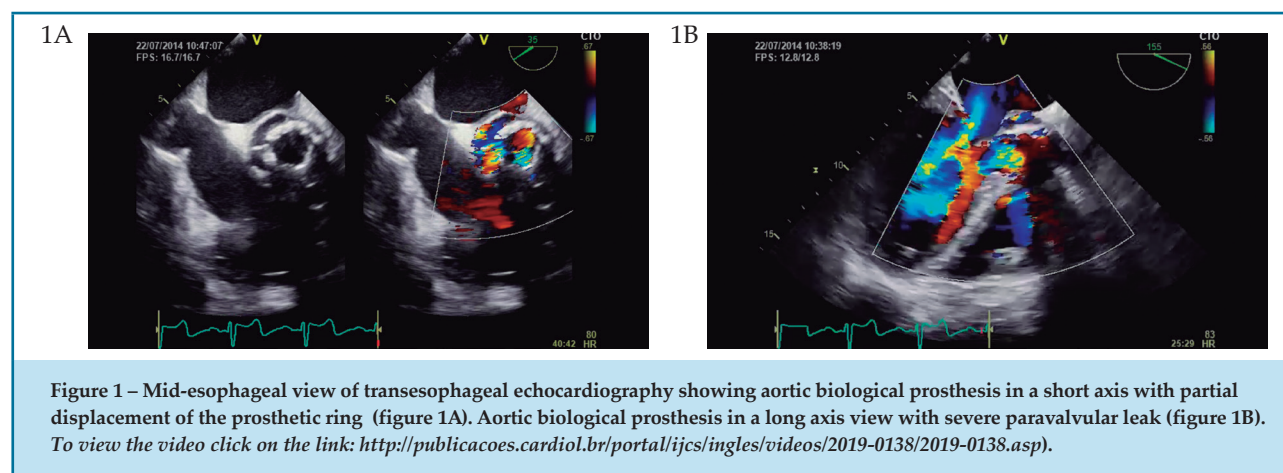


Table 1 - Laboratory results of case 1 and case 2

	Reference value	Case 1	Case 2
Hemoglobin (g/dL)	13.2-17.2	9.1	11.4
Mean globular volume (fL)	80.1-96.1	86.1	87.2
Mean globular hemoglobin (pg)	26.7-30.7	28.8	27.6
Leukocytes $\times 10^9/L$ (%neutrophils; % lymphocytes)	4.0 - 10.0	17.780 (N: 60%; L: 24.1%)	7.86 (N: 43.8%; L:44.1%)
Platelets $\times 10^9/L$	150-400	292	208
Peripheral blood smear		Presence of schistocytes; platelet anisocytosis	Platelet anisocytosis
Reticulocytes (%)	0.5-1.5	6.44%	1.94%
Creatinine (mg/dL)	0.8-1.3	1.10	1.51
Total/ Direct bilirubin (mg/dL)	0.3-1.2 / <0.3	2.79 / 0.58	0.82/0.36
Alanine transaminase ALT (UI/L)	8-35	16	25
Aspartate aminotransferase AST (UI/L)	10-45	14	17
Lactate dehydrogenase LDH (UI/L)	125-225	282	317
High sensitivity troponin i (pg/mL)	<34.2	323.5	57.4
C-reactive protein (mg/dL)	<0.5	2.96	2.32
Sedimentation rate	2-8	39	45
Haptoglobin (g/dL)	16-20	< 8.0	ND
Serology for <i>C.burnetii</i> Phase I IgG; phase II IgG	Positive \geq 128 Or Positive > 1:256	16.000; 32.000	1:512; 1:512
Serology for <i>C.burnetii</i> Phase I IgM; phase II IgM	Positive \geq 64 Or Positive > 1:256	256; 512	1:512; 1:32
Serology for <i>Brucella spp.</i>		Negative	Negative
Blood cultures (3 sets)		No growth	No growth
Imunoglobulin A,G,M	60-400; 300-1500; 40-230	Not available	497.9; 1684.0; 345.0

The patient was referred for cardiothoracic surgery for replacement of the bioprosthesis with the 21mm St. Jude Medical Regent prosthetic valve. The patient was treated with hydroxychloroquine and doxycycline for 24 months; normalization of immunofluorescence antibody titers against *C. burnetii* was achieved, and the infection was cured.

Case 2

Male patient aged 54 years, hepatitis C virus carrier, with history of recurrent tonsilitis in childhood and hypertension. At the age of 43 years, the patient was diagnosed with severe mitral stenosis and underwent replacement of valve with Medtronic Hall® mechanical prosthesis. Less than one year after the surgery, the patient was empirically treated for IE with gentamicin and vancomycin, without identification of the causative agent. After the treatment period, a perivalvular leak and moderate tricuspid insufficiency were detected by TTE, which led to an elective intervention for closure of the leak and De Vega annuloplasty. Eighteen months later, due to another valve dysfunction, implantation of a double-disc mechanical prosthesis and tricuspid annuloplasty with partial ring were performed.

The patient was under therapy with carvedilol, ramipril, furosemide and warfarin. He had had contact with goats and cattle until the age of 30 years.

After eight years of clinical stability since the last valve intervention, the patient was admitted to the emergency department with dyspnea on exertion with progressive worsening even during mild exertion, non-productive cough, myalgia and fever (>38.5°C) during the previous two weeks. The patient reported no weight loss, alcohol consumption, or recent dental or endoscopic procedures.

At physical examination on admission, the patient was sweating, and had tachypnea (25 breaths per minute), crepitations on lung auscultation, prosthetic sounds and grade 3-6 holosystolic murmur on cardiac auscultation. Abdominal palpation revealed hepatomegaly 3cm below costal margin and spleen was not palpable. BP of 112/54mmHg and mean heart rate of 144 bpm.

Electrocardiography showed atrial fibrillation and non-specific changes in intraventricular conduction. Analytical study showed anemia and increased inflammatory parameters (Table 1). A TTE was performed and revealed moderate periprosthetic leak,

which was later confirmed by TEE, with no evidence of vegetations or abscesses.

An study was conducted for blood culture-negative endocarditis, including immunofluorescence serology for *C. burnetii*. Empiric therapy with gentamicin and vancomycin was initiated and the patient was hospitalized at the Division of Internal Medicine for continuation of follow-up and treatment.

The infection by *C. burnetii* was confirmed by titers of phase II IgG antibody of 1:16.384 and phase II IgM antibody of 1:256, and phase I IgG and IgM antibodies of 1:32768 and 1:512, respectively. The definite diagnosis of IE was established based on two major Duke criteria (phase I IgG antibody >1:800 and new valvular dysfunction on echocardiogram).

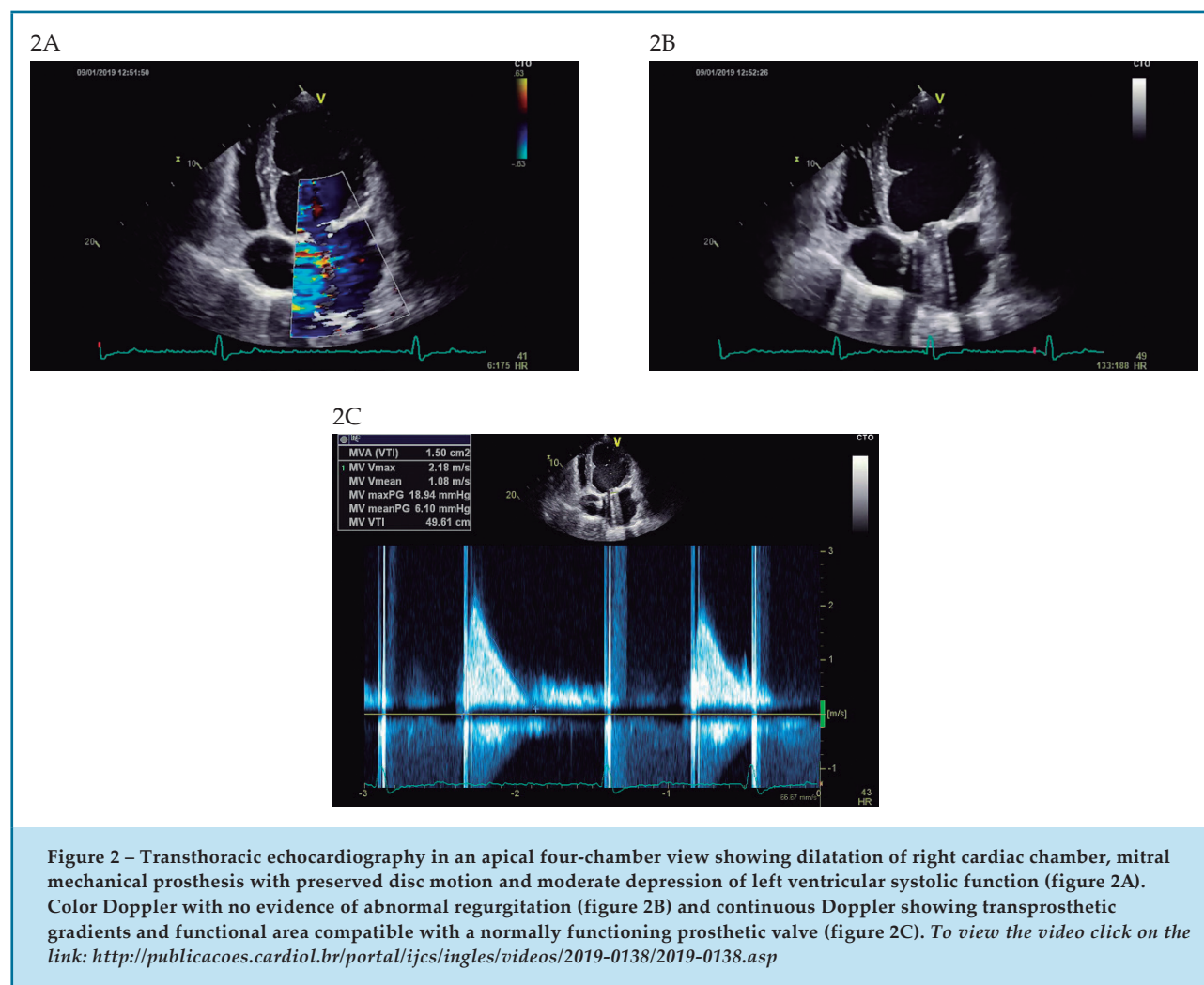
The patient was seen by the cardiothoracic surgery group, confirming the need for another replacement of mitral valve prosthesis, which was performed without complications. Detection of *C. burnetii* DNA from resected valvular material was confirmed by polymerase chain reaction (PCR).

Antibiotic therapy was changed, and the patient completed 24 months of treatment with hydroxychloroquine and doxycycline, with normalization of immunofluorescence antibody titers against *C. burnetii*, and completion of treatment of hepatitis C infection. On follow up, the patient presented New York Heart Association (NYHA) class II congestive heart failure, normal functioning of the mitral mechanical prosthesis and moderate depression of left ventricular systolic function of TTE (Figure 2).

Discussion

blood culture-negative endocarditis accounts for up to 70% of all cases, according to some series.¹ Negative blood cultures may be caused by variables associated with the method (inadequate collection of the sample, administration of antibiotics, local protocols) types of agents involved (fastidious, intracellular), and local epidemiological features.²

A French prospective study by Fournier et al.,³ developed a multimodal strategy for diagnosis of blood culture-negative endocarditis. The methodology included the classical serology and PCR of blood samples, and culture and PCR assay of valvular biopsies whenever possible, as well as blood PCR for the most common causative agents in the population.



The method allowed an increment in diagnostic efficiency by 24.3%, and the authors suggested that these tests should be used as standard in studies of In a population of 283 cases of blood culture-negative endocarditis, *C. burnetii* was responsible for 27 cases (9,5%) in this study.³

Although *C. burnetii* IE is considered a rare condition, it is more common compared with other causative agents including *Bartonella spp.*, *Brucella spp.*, *Tropheryma whippelii*, *Mycoplasma spp.* and *Legionella spp.*, accounting for 5% of all infective endocarditis diagnoses. According to some series, *C. burnetii* represents up to 48% of all diagnosed cases of IE with negative blood culture.⁴

C. burnetii is an obligate intracellular bacterium, and its common reservoirs are cattle, sheep and goats. The pathogen is transmitted by inhalation of aerosolized particles of biological products that can travel many kilometers, without direct contact in many cases.⁵

The most common disease caused by *C. burnetii* infection is acute Q fever, characterized by pneumonia and hepatitis. In some countries, outbreaks of more than 3,000 simultaneous cases of Q fever have been reported, constituting a public health problem (French in 2007 and Holland in 2010).⁶ Most outbreaks, however, are episodic, and in most cases, the illness spontaneously resolves. Therefore, many cases are not properly diagnosed or registered, thereby increasing the number of chronic asymptomatic carriers of *C. burnetii*.⁵

Parreira⁷ assessed the prevalence of *C. burnetii* in a group of 150 healthy blood donors in Portugal and found a seropositivity rate of 28.7%. The results suggest that *C. burnetii* infection is endemic in the country, in both urban and rural areas, which is similar to other countries in Europe.⁷

Chronic Q fever is rarer than the acute form, corresponding to 1-5% of the infections by *C. burnetii*.¹

In 70% of the cases, the chronic disease presents as IE. The latency period between the first contact with the agent and clinical manifestations may vary from one year to more than a decade.⁸

Risk factors associated with *C. burnetii* IE are male sex (75%), age between 40 and 70 years, heart valve disease (91%) particularly in the presence of prosthetic valve (between 30 and 55%, depending on the series) and immunocompromised patients (32%). History of previous exposure to animals was reported in 70% of the cases. Associated comorbidities include alcohol consumption, diabetes, renal failure and hepatitis C virus infection.⁹

Presentation of *C. burnetii* IE is non-specific, which hinders a timely diagnosis. Almost 50% of patients have symptoms of acute heart failure, and most patients have fever (70%), weight loss, fatigue and anorexia (50%). Other manifestations include purpuric rash on extremities and mucosa, digital clubbing, splenomegaly, renal injury caused by immunocomplex deposits and embolic events.¹⁰

The diagnosis of IE is made using the modified Duke criteria.¹¹ Serological diagnosis by indirect immunofluorescence is considered a major criterion for *C. burnetii* IE, corroborating its importance. The diagnosis of chronic infection is made by phase I IgG antibody titers >1:800, with specificity of 99.6%, and values lower than that are classified as minor criteria.^{1,12}

Endocardial involvement shown by imaging test is another Duke major criterion, which determines the crucial role of echocardiography in detecting vegetations, new heart valve insufficiency or worsening of a pre-existing valvular insufficiency. However, the available literature shows that both TTE and TEE have low sensitivity (12% and 33%, respectively) in detecting changes in heart valve structure, which reinforces the difficulty in obtaining elements for the diagnosis of *C. burnetii* IE.¹³

The diagnosis of *C. burnetii* infection can also be made by DNA sequence analysis or anatomopathological findings of *C. burnetii* in the fragments of valvular vegetation. However, these methods have low cost-effectiveness due to several histological changes these fragments may have.¹²

The risk factors for mortality include delay in treatment, male sex, older age, acute coronary syndrome, prosthetic valve endocarditis, and elevated IgG titers after one year.¹⁴

Early mortality decreased in the last four decades (from 60% to 5%) in populations diagnosed within six months since introduction of the combined therapy of

hydroxychloroquine (200 mg three times per day) and doxycycline (200 mg twice per day). Duration of treatment is 18 months for native valve endocarditis and 24 months for prosthetic valves.¹⁵

The recommended follow-up period is five years, and the cure is achieved when the IgG phase I titer is reduced by four times from the diagnostic value and the IgM phase II titer is undetectable.

In addition, literature shows a progressive decrease in the need for valve surgery, from 60% in the 70's to 46% today, which is in line with the establishment of early diagnosis, increasing the chances of cure by pharmacological intervention alone. In case of elective surgeries, it is recommended antibiotic therapy for three weeks before the surgery. Emergent surgery is indicated for patients with high hemodynamic instability and advanced valve dysfunction.¹⁶

Conclusions

There are important messages that can be drawn from these case reports and literature review. The prevalence of Q fever is high in its acute form, but the disease is underdiagnosed and underreported. This increases the number of asymptomatic carriers that may develop chronic Q fever in the presence of risk factors such as heart valve disease, male sex, age between 40 and 70 years, and comorbidities such as hepatitis C, diabetes and hypertension. *C. burnetii* IE has an indolent nature, characterized by non-specific presentation and a long period of destruction of perivalvular tissue.

In the first stages of the disease, bacteremia may respond to empiric antibiotic therapy for IE, which, together with surgical excision of the infected material, may lead to a favorable but temporary condition. Due to its intracellular nature, the chronic infection by *C. burnetii* is not effectively treated and the patient will most likely develop another valvular dysfunction with time.

This seems to be the case of these two of these two reports, who came from a small population of approximately 250,000 inhabitants, and were observed within a short time interval. Although *C. burnetii* is considered a rare causative agent of IE, it is important to highlight that is recognized as the most common cause of blood culture-negative IE. Also, the epidemiological context should be carefully considered.

Therefore, it is worth reinforcing that the hypothesis of *C. burnetii* IE should be considered for the first differential diagnoses, particularly in the presence of blood culture-negative IE and unexplained valvular dysfunction that requires repeat surgeries. The cure of the infection is achieved only with hydroxychloroquine and doxycycline for 18 months for native valve endocarditis and 24 months for prosthetic valve.

Potential Conflict of Interest

No potential conflict of interest relevant to this article was reported.

Sources of Funding

There were no external funding sources for this study.

Study Association

This study is not associated with any thesis or dissertation work.

Ethics approval and consent to participate

This article does not contain any studies with human participants or animals performed by any of the authors.

Author contributions

Conception and design of the research: Barbosa MM, Dias C, Araújo E. Acquisition of data: Barbosa MM, Dias C. Analysis and interpretation of the data: Barbosa MM, Dias C. Writing of the manuscript: Barbosa MM, Dias C. Critical revision of the manuscript for intellectual content: Barbosa MM, Dias C, Araújo E, Costa R.

References

- Habib G, Lancellotti P, Antunes MJ, Bongiorno MG, Casalta JP, Del Zotti F, et al. ESC Scientific Document Group 2015 ESC Guidelines for the management of infective endocarditis: The Task Force for the Management of Infective Endocarditis of the European Society of Cardiology (ESC). Endorsed by: European Association for Cardio-Thoracic Surgery (EACTS), the European Association of Nuclear Medicine (EANM). *Eur Heart J*. 2015;36(44):3075-128.
- Brouqui P, Raoult D. New Insight into the diagnosis of fastidious bacterial endocarditis. *FEMS Immunol Med Microbiol*. 2006;47:1-13.
- Fournier PE, Gouriet F, Casalta JP, Lepidi H, Chaudet H, Thunny F, et al. Blood culture-negative endocarditis: Improving the diagnostic yield using new diagnostic tools. *Medicine (Baltimore)*. 2017;96(47):e8392.
- Houpikian P, Raoult D. Blood culture-negative endocarditis in a reference center: etiologic diagnosis of 348 cases. *Medicine (Baltimore)*. 2005;84(3):162-73.
- Maurin M, Raoult D. Q fever. *Clin Microbiol Rev*. 1999;12(4):518-53.
- Hanssen DAT, Morroy G, de Lange MMA, Wienders CCH, Vander Hoek W, Dijkstra F, et al. Notification data and criteria during a large Q-fever epidemic reassessed. *Epidemiol Infect*. 2019;147:e191.
- Parreira, PA Estudo da prevalência de anticorpos anti Coxiellaburnetii numa amostra de doadores de sangue de uma região portuguesa. Dissertação.Lisboa: Faculdade de Medicina da Universidade de Lisboa; 2008.
- Deyell MW, Chiu B, Ross DB, Alvarez N. Q fever endocarditis: a case report and review of the literature. *Can J Cardiol*.2006;22(9):781-5
- Fenollar F, Fournier PE, Carrieri MP, Habib G, Messana T, et al. Risks factors and prevention of Q fever endocarditis *Clin Infect Dis*. 2001; 33 (3):312.
- Houpikian P, Habib G, Mesana T, Raoult D. Changing clinical presentation of Q fever endocarditis. *Clin Infect Dis*. 2002;34(5):E28-31.
- Li JS, Sexton DJ, Mick N, Nettles R, Fowler VG, Ryan T, et al. Proposed Modifications to the Duke Criteria for the Diagnosis of Infective Endocarditis. *Clin Infect Dis*.2000;30(4):633-8.
- Dupont HT, Thirion X, Raoult D. Q fever serology: cutoff determination for microimmunofluorescence. *Clin Diagn Lab Immunol*. 1994; (2):189-96.
- Jortner R, Demopoulos LA, Bernstein NE, Tunick PA, Shapira Y, Shaked Y, et al. Transesophageal echocardiography in the diagnosis of Q-fever endocarditis. *Am Heart J*. 1994;12(4):827-31.
- Kampschreur LM, Hcornenborg E, Renders NH, Oosterheert JJ, Haverman JF, Elsmann P. Delayed Diagnosis of Chronic Q Fever and Cardiac Valve Surgery. *Emerg Infect Dis*. 2013; 19(5):768-73.
- Raoult D. Treatment of Q fever. *Antimicrob Agents Chemother*. 1993;37:1733-6.
- Million M, Thunny F, Richet H, Raoult D. Long-term outcome of Q fever endocarditis: a 26-year personal survey. *Lancet Infect Dis*. 2010;8:527-35.