

Improvement of Pacing-Induced Dyssynchrony by Right Ventricular Septal Stimulation in a Child with Tetralogy of Fallot

Alexander González Guillen, Michel Cabrera Ortega, Francisco Díaz Ramírez, Dunia Bárbara Benítez Ramos

Cardiocentro Pediátrico "William Soler", Boyeros, Havana – Cuba

Introduction

Complete atrioventricular block (CAVB) is not an uncommon complication after surgical correction of tetralogy of Fallot (TOF). The choice of the ventricular pacing site in patients requiring pacemaker therapy depends on factors such as age, weight, presence of a venous anomaly, and intracardiac short-circuit. The harmful effects of ventricular pacing are most pronounced during right ventricular (RV) stimulation. Even then, RV pacing sites have been determined to be optimal in some patients with and without congenital heart disease.¹

Case report

A 4-year-old boy with a history of surgically repaired TOF had a single-chamber pacemaker with rate response mode (VVIR) implanted in the left ventricular (LV) epicardium due to a postoperative CAVB (Figure 1a). During LV pacing, the electrocardiogram (ECG) demonstrated an increased QRS complex duration and a marked right bundle-branch block (RBBB) pattern with negative paced QRS complexes in inferior leads (Figure 1b). Subsequent echocardiographic evaluations showed interventricular and right intraventricular dyssynchrony, which was associated with progressive RV dilatation. After 1 year of ventricular pacing, the patient developed RV dysfunction with a fractional area change (FAC) of 28% and a tricuspid annular plane systolic excursion (TAPSE) of 12 mm.

Keywords

Heart Defects, Congenital; Tetralogy of Fallot / surgery; Atrioventricular Block; Ventricular Dysfunction, Right; Cardiac Resynchronization Therapy.

Furthermore, two-dimensional strain reflected an RV dyssynchrony index of 56 msec, with the worse QS delay at the RV mid-septum (195 msec). Considering the beneficial effects of septal stimulation,^{1,2} the patient underwent lead and pacemaker replacement. An active ventricular lead (Medtronic CapSureFix, Medtronic Limited, Watford, UK) was fixed in the RV mid-septum (Figure 2), obtaining appropriate sensing and pacing thresholds. Following single-site RV midseptal pacing, a 12-lead surface ECG revealed a shorter duration of the QRS complex and a left bundle-branch block pattern with positive paced QRS complexes in inferior leads. Additionally, there was an immediate decrease in interventricular dyssynchrony to 31 msec and RV dyssynchrony index to 27 msec. An echocardiographic assessment showed an increase in FAC (39%) and TAPSE (15 mm), with a reduction in the RV diameters 3 months after the therapy.

Discussion

The LV is the optimal pacing site in the pediatric population.³ However, Karpawich et al.¹ demonstrated that the optimal lead implantation site varies among patients and congenital heart diseases (CHD). In our case, LV pacing produced a dyssynchronous RV contraction, evidenced by an increased QRS duration and echocardiographic parameters.

Correction of TOF is often followed by RV conduction delay and RBBB. A study in an animal model of repaired TOF evidenced the activation sequence related with RBBB, first with activation of the basolateral LV region and last with activation of the area of the RV free wall.⁴ Moreover, LV pacing enhances a baseline RBBB, and the delayed electrical activation observed may induce a dyssynchronous RV contraction with a negative impact on the RV function.

Mailing Address: Michel Cabrera Ortega

Calle 100 y Perla, Postal Code: 10800. Altahabana. Boyeros. La Habana, Boyeros – Cuba
E-mail: michel@cardiows.sld.cu; anrossca@yahoo.es

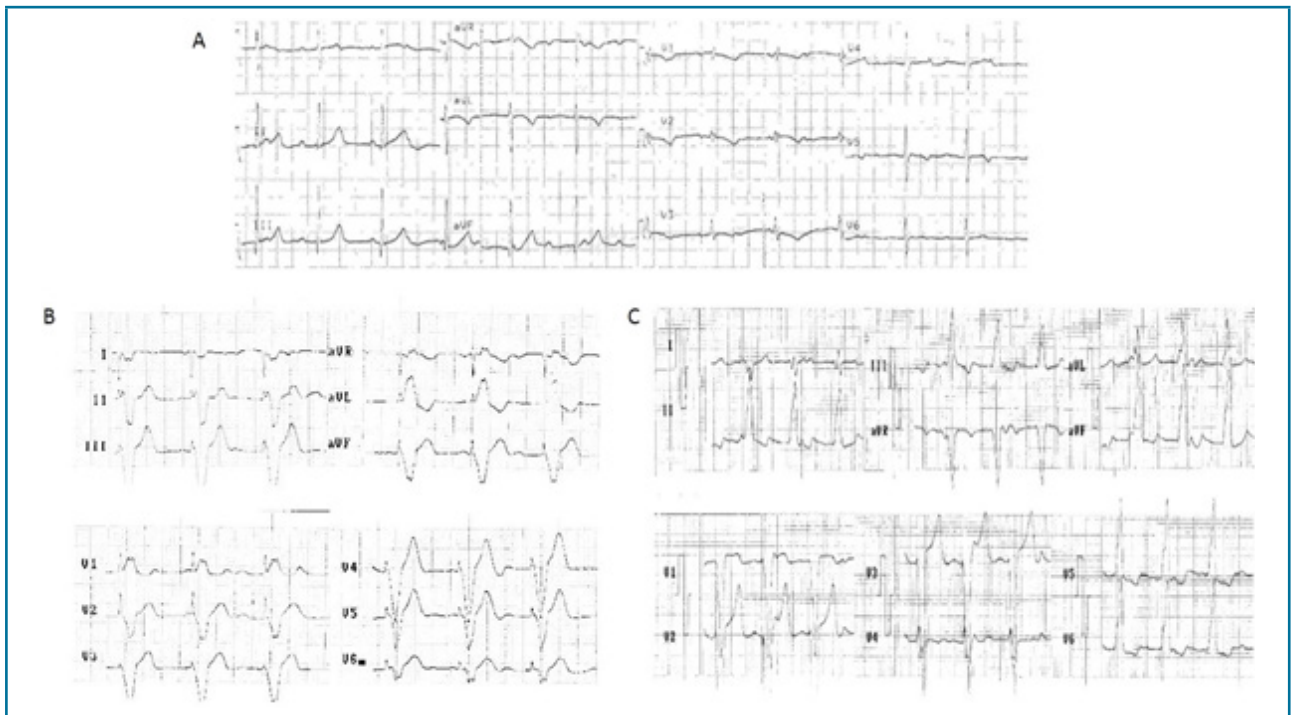


Figure 1 – A 12-lead electrocardiogram showing (A) complete atrioventricular block with a right bundle-branch block, (B) VVIR pacing mode from the left ventricle with a wide QRS complex of 160 msec and a marked right bundle-branch block, and (C) VVIR pacing mode from the right ventricular mid-septum with a QRS complex of 120 msec and left bundle-branch block pattern.

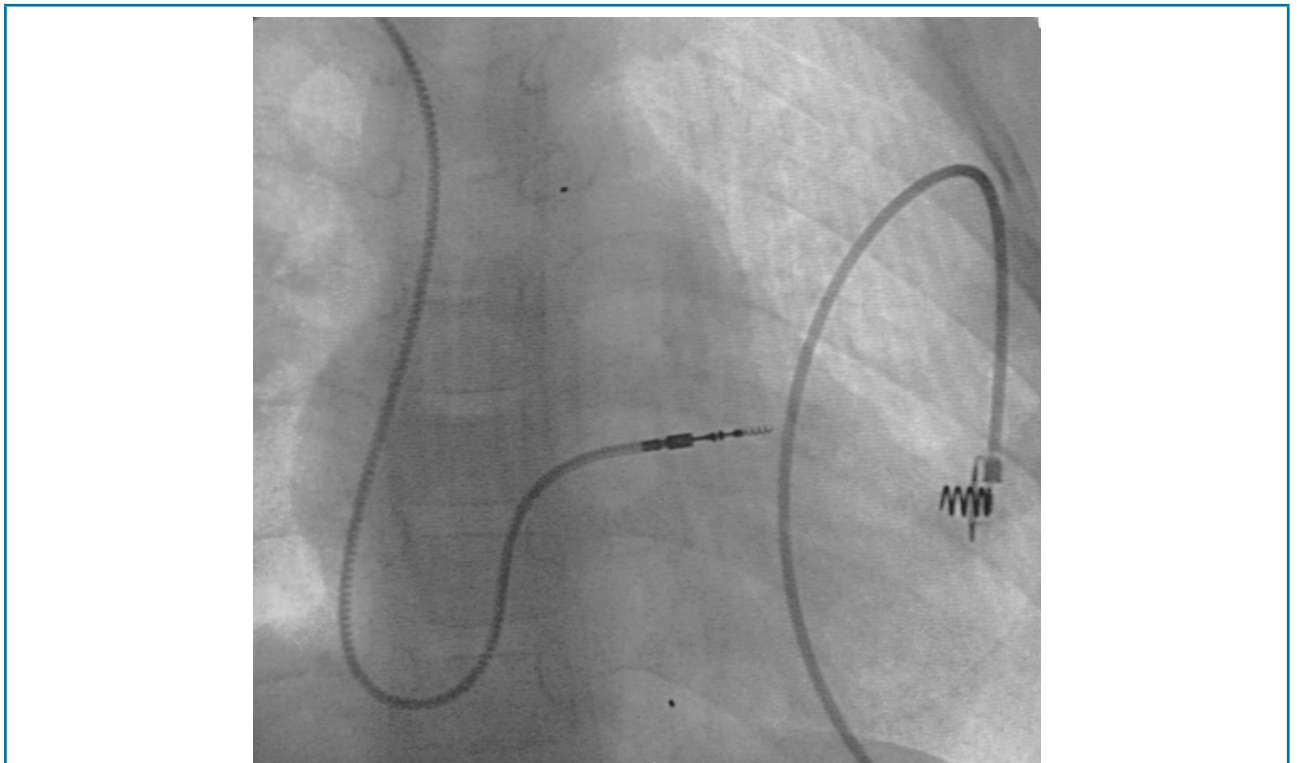


Figure 2 – Fluoroscopic appearance showing the final position of the lead in the right ventricular mid-septum.

This RBBB may actually respond better with pacing in the RV when compared with the LV. Placement of the pacing electrode in close proximity to the normal conduction system reestablishes the intraventricular synchrony and offers the potential to improve the ventricular function. Karpawich et al.¹ evaluated the physiological variables of contractility (dP/dt and dP/dt/p) at various sites in younger patients with and without CHD.¹ Their results demonstrated that the mid-septal ventricular implantation site offers the best paced ventricular contractility.¹ In addition, the authors recommend that biventricular (Biv) pacing may not be necessary if the pacing site associated with the best contractility response can be established.¹ Moreover, two studies evidenced that both RV and Biv pacing improved RV dP/dt in patients with repaired TOF and clinical signs of RV failure.^{4,5} These findings confirm the beneficial effects of RV stimulation in subjects with right heart dysfunction and RBBB, with a preference for Biv pacing when concomitant LV failure is present.

We advocate the use of single-site pacing based on the advantage that a single ventricular lead in small children prolongs battery longevity and reduces vascular complications and lead-associated problems. Data in children with LV failure suggest that single-site pacing may be sufficient for resynchronization therapy.^{6,7} Changing the site of pacing should be considered if routine echocardiographic tests demonstrate ventricular dilatation or dysfunction. Nevertheless, an individual approach may be best to identify the optimal pacing site in order to

prevent future negative effects on electrical activation and cardiac performance.

Stimulation from a midseptal site is associated with the best hemodynamic responses and ventricular synchrony compared with other RV pacing sites. This explains the successful resynchronization observed in our patient and confirms that the ventricular pacing site is the major determinant of cardiac pump function.

Author contributions

Conception and design of the research: Guillen AG, Ortega MC. Acquisition of data: Ortega MC, Ramos DBB. Analysis and interpretation of the data: Ramos DBB, Ramírez FD. Writing of the manuscript: Guillen AG, Ortega MC. Critical revision of the manuscript for intellectual content: Guillen AG, Ortega MC, Ramírez FD, Ramos DBB.

Potential Conflict of Interest

No potential conflict of interest relevant to this article was reported.

Sources of Funding

There were no external funding sources for this study.

Study Association

This study is not associated with any thesis or dissertation work.

References

1. Karpawich PP, Singh H, Zelin K. Optimizing paced ventricular function in patients with and without repaired congenital heart disease by contractility-guided lead implant. *Pacing Clin Electrophysiol*. 2015;38(1):54-62. doi: 10.1111/pace.12521.
2. Shimony A, Eisenberg MJ, Filion KB, Amit G. Beneficial effects of right ventricular non - apical vs. apical pacing: a systematic review and meta - analysis of randomized - controlled trials. *Europace*. 2012;14(1):81-91. doi: 10.1093/europace/eur240.
3. Janousek J, van Geldorp IE, Krupicková S, Rosenthal E, Nugent K, Tomaske M, et al. Permanent cardiac pacing in children: choosing the optimal pacing site: a multicenter study. *Circulation*. 2013;127(5):613-23. doi: 10.1161/CIRCULATIONAHA.112.115428.
4. Thambo JB, Dos Santos P, De Guillebon M, Roubertie F, Labrousse L, Sacher F, et al. Biventricular stimulation improves right and left ventricular function after Tetralogy of Fallot repair: Acute animal and clinical studies. *Heart Rhythm*. 2010;7(3):344-50. doi: 10.1016/j.hrthm.2009.11.019.
5. Dubin AM, Feinstein JA, Reddy VM, Hanley FL, Van Hare GF, Rosenthal DN. Electrical resynchronization: a novel therapy for the failing right ventricle. *Circulation*. 2003;107(18):2287-9. doi: 10.1161/01.CIR.0000070930.33499.9F.
6. Tomaske M, Breithardt OA, Balmer C, Bauersfeld U. Successful cardiac resynchronization with single-site left ventricular pacing in children. *Int J Cardiol*. 2009;136(2):136-43. doi: 10.1016/j.ijcard.2008.04.048.
7. Vanagt WY, Prinzen FW, Delhaas T. Reversal of pacing induced heart failure by left ventricular apical pacing. *N Engl J Med*. 2007;357(25):2637-8. doi: 10.1056/NEJMc072317.

