

CASE REPORT

Persistent Primitive Hypoglossal Artery Associated with Brain Stem Ischemia in an Elderly Patient

Rafael Mansur Souto,^{1,2} Alair Augusto Sarmet Moreira Damas dos Santos,^{1,2} Marcelo Souto Nacif^{1,2}

Centro de Imagem, Complexo Hospitalar de Niterói,¹ Niterói, RJ - Brazil

Programa de Pós-graduação em Ciências Cardiovasculares, Universidade Federal Fluminense,² Niterói, RJ - Brazil

Introduction

The primitive hypoglossal artery (PHA) crosses the hypoglossal canal, being one of the four vessels that acts as anastomosis between the primitive dorsal aorta and longitudinal neural arteries. The PHA typically retracts 40 days after pregnancy but may persist in some situations.¹

Direct anastomoses between the basilar and carotid arteries are rare.¹⁻³ These vessels retreat during the fortieth day of fetal development, when the emergence of the posterior communicating arteries occurs.¹ Among these primitive communicating vessels are the trigeminal, the primitive hypoglossal, the proatlantal and the ophthalmic vessels.^{1,2,4} The persistence of the primitive hypoglossal artery has an incidence of 0.01% to 0.03%, being the second most frequent among the four vessels.^{4,6}

Persistent PHA (PPHA) occurs when it emerges at the level of C1 to C3 and enters the posterior fossa, crossing the hypoglossal canal, and ending at the basilar artery.⁴ The posterior communicating artery is hypoplastic or absent. The diagnosis may be attained through angiotomography and angiography assessments.¹

Case report

An 80-year-old man, a patient with systemic arterial hypertension and diabetes mellitus, had malaise with lipothymia for two days, and therefore sought medical assistance. After he showed no improvement, he returned

Keywords

Cerebrovascular Disease, persistent primitive hypoglossal artery; primitive arteries, carotid-basilar anastomoses, Arteriosclerosis.

to the emergency unit a few days later, with persistent symptoms of dysarthria and apathy, as well as right hemiparesis. During his clinical evolution, he showed worsening of the condition and homolateral dysmetria.

Initially, the patient was diagnosed with left-sided cerebrovascular accident (CVA) in the brainstem, with diffusion restriction disclosed by a skull MRI (Figure 1A). Subsequently, the carotid and vertebral Doppler showed the following findings: calcified plaques in both carotid bulbs with approximately 50% of bilateral obstruction and preserved flow in both vertebral arteries.

In the angiotomography of the carotid and vertebral arteries, PHA persistence was shown combined with the basilar artery (Figures 1B and 1C), as well as atherosclerotic arterial disease with slight carotid bulb lumen reduction on the right and moderate on the left.

In most cases, PPHA occurs only as an incidental finding at an examination indicated for other reasons. It is important, however, to be aware that when a carotid endarterectomy is intended for some other reason, there are some risks in the presence of such condition. Among these are the high carotid exposure and the challenges of maintaining cerebral perfusion.¹

In our case, the patient developed brainstem CVA, with subsequent hemorrhagic transformation. At the angiotomography, the patient showed the presence of mixed plaque, affecting the distal end of the left common carotid, bulb and ostium of the internal carotid artery, generating moderate luminal reduction of the internal carotid on this side. He also showed signs of contralateral carotid bulb atherosclerotic disease. This fact is described in the literature,⁶ according to which patients with persistent hypoglossal artery have high risks of atherosclerotic disease and cerebrovascular accidents, as well as subarachnoid hemorrhage and aneurysms.

Mailing Address: Rafael Mansur Souto

Rua Farne de Amoedo, n 149, Postal Code: 22420-020, Rio de Janeiro, RJ - Brazil.

E-mail: rafaelmansur1250@hotmail.com

DOI: 10.5935/2359-4802.20180053

Manuscript received on August 18, 2017; revised on February 05, 2018; accepted on March 27, 2018.

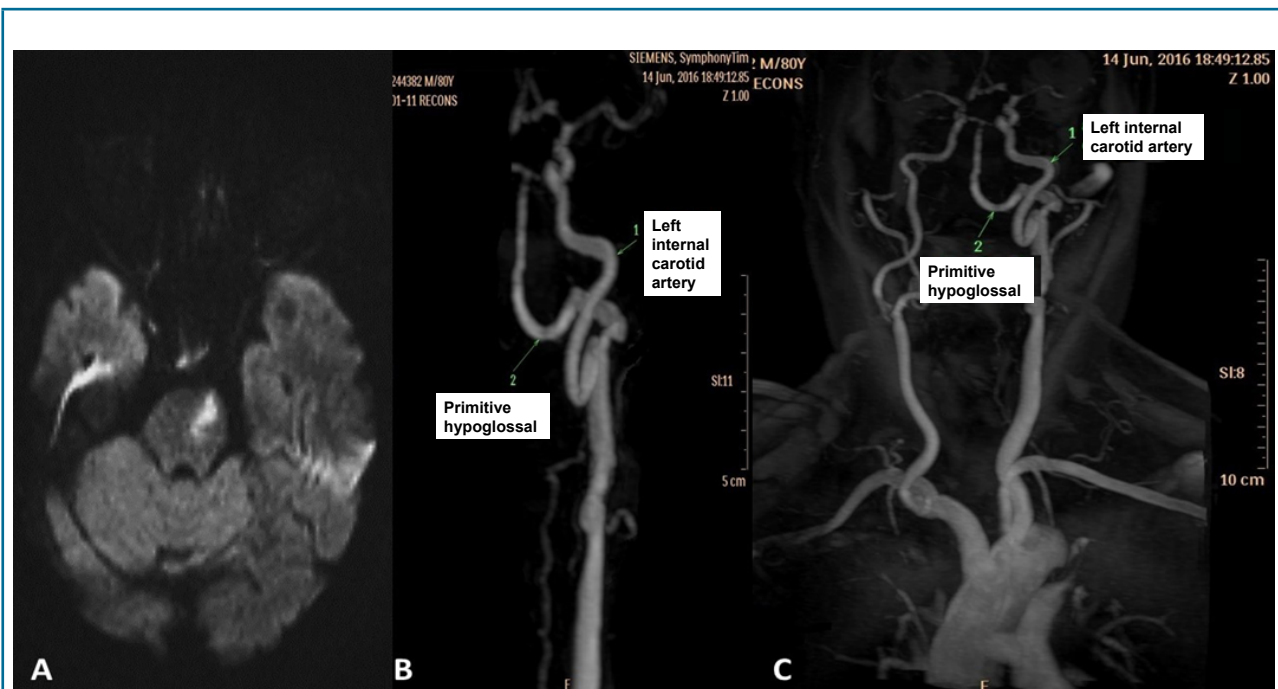


Figure 1 - (A) Magnetic resonance showing diffusion restriction in the brain stem on the left. (B) Angiotomography with MIP reconstruction and bone subtraction, demonstrating the emergence of the hypoglossal artery and the left internal carotid artery. (C) Comparative image between the two carotid arteries and the emergence of the primitive hypoglossal on the left.

PPHA is often identified in imaging tests; however, in the presence of atherosclerotic disease, it may be of clinical importance due to the increased chance of developing cerebral infarction.^{6,7} Associated with this condition, the passage of emboli from the internal carotid artery to the vertebrobasilar system becomes possible.⁸

Our patient did not receive dual antiplatelet therapy due to the hemorrhagic transformation of the CVA and was submitted to an expectant conduct, as recommended by the literature.⁹ The drainage of bulky hematomas is essential for the maintenance of life, but more discrete hemorrhagic events can be followed without major interventions,⁹ as in this case.

Conclusion

The above case report showed the clinical importance of the persistence of primitive arteries, more specifically the primitive hypoglossal artery, in a context of cerebrovascular accident and its consequences.

Author contributions

Conception and design of the research: Souto RM, Santos AASMD, Nacif MS. Acquisition of data: Souto RM, Nacif MS. Analysis and interpretation of data: Souto RM, Nacif MS. Writing of the manuscript: Souto RM, Nacif MS. Critical revision of the manuscript for intellectual content: Souto RM, Santos AASMD, Nacif MS.

Potential Conflict of Interest

No potential conflict of interest relevant to this article was reported.

Sources of Funding

There were no external funding sources for this study.

Study Association

This article is part of the thesis of master submitted by Rafael Mansur Souto, from Universidade Federal Fluminense (UFF).

References

1. Huang M, Moisi M, Zwillman ME, Volpi JJ, Diaz O, Klucznik R. Transient ischemic attack in the setting of carotid atheromatous disease with a persistent primitive hypoglossal artery successfully treated with stenting: a case report. *Cureus*. 2016;8(1):e464.
2. Silva CE, Romero AD, Freitas PE, Cantali DU, Melo LS, Parda E, et al. Persistent primitive hypoglossal artery associated with brain stem ischemia in a young patient. *Arq Neuro Psiquiatr*. 2013;71(3):194-5.
3. Voronovich Z, Grandhi R, Zwagerman NT, Jadhav AP, Jovin TG. Manual aspiration thrombectomy for basilar infarction in the setting of a persistent primitive hypoglossal artery: case report and review of the literature. *Surg Neurol Int*. 2014 Dec 19;5:182.
4. Meguro T, Terada K, Hirotsune N, Nishino S, Asano T. Unusual variant of persistent primitive hypoglossal artery. *Br J Radiol*. 2007;80(960):e314-6.
5. Zhang L, Song G, Chen L, Jiao L, Chen Y, Wang Y. Concomitant asymptomatic internal carotid artery and persistent primitive hypoglossal artery stenosis treated by endovascular stenting with proximal embolic protection. *J Vasc Surg*. 2016;63(1):237-40.
6. Srinivas MR, Vedaraju KS, Manjappa BH, Nagaraj BR. Persistent Primitive Hypoglossal Artery (PPHA) – a rare anomaly with literature review. *J Clin Diagn Res*. 2016;10(1):TD13-4.
7. Souza LV, Castro CC, Cerri GG. Avaliação da aterosclerose carotídea por intermédio de ultra-sonografia e ressonância magnética. *Radiol Bras*. 2005;38(2):81-94.
8. Conforto AB, de Souza M, Puglia P Jr, Yamamoto FI, da Costa Leite C, Scaff M. Bilateral occipital infarcts associated with carotid atherosclerosis and a persistent hypoglossal artery. *Clin Neurol Neurosurg*. 2007;109(4):364-7.
9. Powers WJ, Derdeyn CP, Biller J, Coffey CS, Hoh BL, Jauch EC, et al; American Heart Association Stroke Council. 2015 American Heart Association / American Stroke Association Focused Update of the 2013 Guidelines for the Early Management of Patients With Acute Ischemic Stroke Regarding Endovascular Treatment. *Stroke: a guideline for healthcare professional from the American Heart Association / American Stroke Association*. 2015;46(10):3020-35.

