

# Randomized controlled clinical trial of long-term chemo-mechanical caries removal using Papacarie™ gel

Lara Jansiski MOTTA<sup>1</sup>, Sandra Kalil BUSSADORI<sup>2</sup>, Ana Paula CAMPANELLI<sup>3</sup>, André Luis da SILVA<sup>3</sup>, Thays Almeida ALFAYA<sup>4</sup>, Camila Haddad Leal de GODOY<sup>2</sup>, Maria Fideia de Lima NAVARRO<sup>5</sup>

1- School of Dentistry, University Nove de Julho (UNINOVE), São Paulo, SP, Brazil.

2- Rehabilitation Sciences Post Graduation Program, University Nove de Julho (UNINOVE), São Paulo, SP, Brazil.

3- Department of Biological Sciences, Bauru School of Dentistry, University of São Paulo, Bauru, SP, Brazil.

4- Dental Clinic Post Graduation Program, Federal Fluminense University (UFF), Niterói, RJ, Brazil.

5- Department of Operative Dentistry, Endodontics and Dental Materials, Bauru School of Dentistry, University of São Paulo, Bauru, SP, Brazil.

**Corresponding address:** Sandra Kalil Bussadori - R. Vergueiro, 235/249 - Liberdade - São Paulo - SP - 01504-001 - Brazil - Phone: +55 11 3385 9222 - e-mail: sandra.skb@gmail.com

**Submitted:** October 18, 2013 - **Modification:** January 17, 2014 - **Accepted:** February 28, 2014

## ABSTRACT

Advances in the field of cariology and the philosophy of minimally invasive intervention have led to transformations in the restorative treatment of dental caries. Objectives: Compare the effectiveness of Papacarie™ gel for the chemo-mechanical removal of carious lesions on primary teeth to conventional caries removal with a low-speed bur with regard to execution time, clinical aspects and radiographic findings. Material and Methods: A randomized controlled clinical trial with a split-mouth design was carried out. The sample was composed of 20 children aged four to seven years, in whom 40 deciduous teeth were randomly divided into two groups: chemo-mechanical caries removal with Papacarie™ and removal of carious dentin with a low-speed bur. Each child underwent both procedures and served as his/her own control. Restorations were performed with glass ionomer cement. The time required to perform the procedure was also analyzed. The patients underwent longitudinal clinical and radiographic follow-up of the restorations. Results: No statistically significant difference between groups was found regarding the time required to perform the procedures and the radiographic follow up. Statistically significant differences between groups were found in the clinical evaluation at 6 and 18 months after treatment. Conclusion: Papacarie™ is as effective as the traditional method for the removal of carious dentin on deciduous teeth, but offers the advantages of the preservation of sound dental tissue as well as the avoidance of sharp rotary instruments and local anesthesia.

**Keywords:** Dental caries. Papain. Dental atraumatic restorative treatment

## INTRODUCTION

Advances in the field of cariology and the philosophy of minimally invasive intervention have led to transformations in the restorative treatment of dental caries. The most striking change involves the selective removal of carious tissue and maximal preservation of healthy dental tissue. Traditional methods involving a drill and a bur are incompatible with this philosophy<sup>1,4,19</sup>.

Chemo-mechanical caries removal (CMCR) is an alternative to the conventional method and consists

of the application of a proteolytic substance that softens carious dentin tissue and facilitates its removal using manual instruments<sup>17</sup>. This method can be employed without the use of local anesthesia or burs, thereby preserving sound dental tissue<sup>4-6</sup>.

Papacarie™ is one of the products marketed for CMCR. This gel contains papain and chloramine. Papain is an enzyme similar to human pepsin that acts as a debriding agent with no harm caused to healthy tissue. This substance accelerates the healing process and exhibits bactericidal, bacteriostatic and anti-inflammatory properties<sup>10,18</sup>.

Chloramine has properties related to disinfection<sup>11</sup>. A number of studies have demonstrated the efficacy of Papacarie™ and report that its cost is lower than similar products found on the market<sup>6,10,16,23</sup>.

There is a scarcity of well-standardized clinical trials comparing the traditional cavity preparation method to chemo-mechanical caries removal with the use of Papacarie™ gel. Thus, the aim of the present study was to compare the effectiveness of Papacarie™ gel for the chemo-mechanical removal of carious lesions on primary teeth to conventional caries removal with a low-speed bur with regard to execution time, clinical aspects and radiographic findings, using a longitudinal design.

## MATERIAL AND METHODS

A randomized, controlled, clinical trial with a "split-mouth" design was carried out to assess the efficacy of Papacarie™ gel. The investigation was designed, analyzed and interpreted according to the Consolidated Standards of Reporting Trials (CONSORT) (Figure 1). Thirty children aged four to seven years who sought dental treatment at the Pediatric Dentistry Clinic of the University Nove de Julho (Brazil) were recruited. The control group was submitted to the traditional method (bur) for the removal of carious tissue. All parents/guardians received information on the objectives

and procedures of the study and signed a statement of informed consent in compliance with Resolution 196/96 of the Brazilian National Health Board. This study received approval from the Human Research Ethics Committee of the University Nove de Julho (Brazil) under process nº 219047. The clinical trial registration number is NCT01811420.

### Sample size calculation

The sample size was calculated using the Dinam 1.0 program with data from a pilot study. Calculations were performed considering time, discomfort, colony-forming bacteria and radiographic density. As the variable colony-forming bacteria required the largest number of teeth *per* group, this variable was chosen as the reference ( $n=19$  teeth *per* group).

### Calibration exercise

The calibration exercise was carried out during the pilot study. An operator performed the treatment and a "gold standard" examiner performed the clinical evaluation of the removal of carious tissue. The examiner was blinded to the technique applied (chemo-mechanical caries removal with Papacarie™ and removal of carious dentine with low-speed bur). The "gold standard" examiner evaluated all cavities following the respective interventions and was responsible for testing the hardness of the

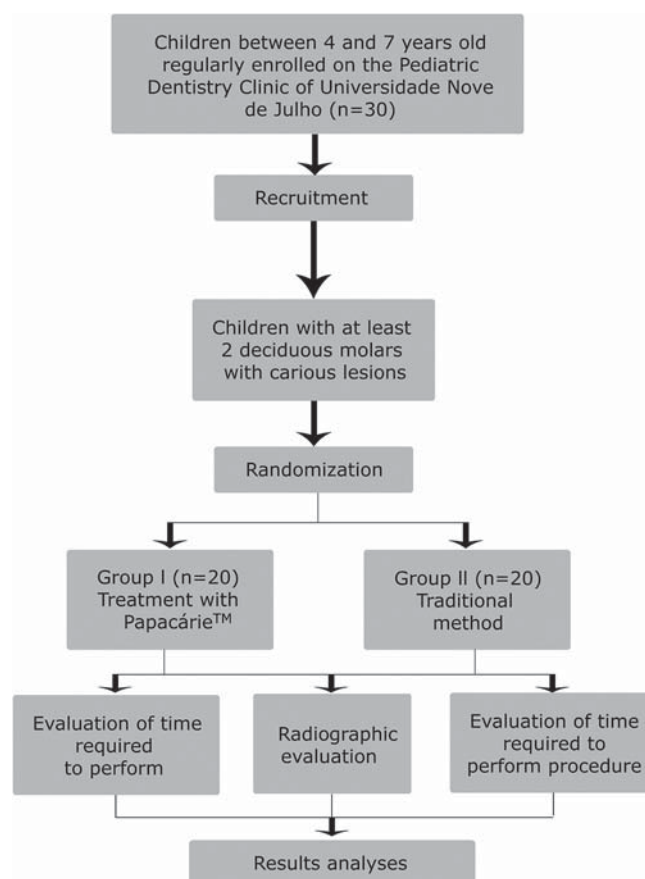


Figure 1- Flowchart of the protocol

remaining dentin. The clinical evaluation involved an inspection of the texture of the remaining dentin with a blunt exploratory probe, observing the vitreous aspect (cavity free of carious tissue). Caries removal was only considered complete when agreement was achieved between the operator and examiner. Intra-examiner agreement was determined using the Kappa statistic and was considered excellent ( $K=0.92$ ).

### Sample selection

Twenty children aged four to seven years participated in the study. The sample was made up of 40 primary teeth (two *per* child). The following were the inclusion criteria: good health, with no systemic conditions and good behavior. Clinically, the children need to have at least two primary molars with active, acute carious lesions not surpassing 2/3 of the dentin and involving only the occlusal facet, with no clinical or radiographic signs or symptoms of pulp involvement (spontaneous pain, pain upon palpation, fistula, abscess, sensation of enlarged tooth, periapical radiolucency, increase in the space of the periodontal ligament in the apical region, periapical radiopacity, lateral lesions and lesions in the furcation due to the impairment of accessory canals). The exclusion criteria were Class II, III or IV carious lesions in the Black classification, clinical impossibility of restorations, carious lesion involving the enamel, presence of deficient restorations, small carious lesions in dentin (without access for manual excavators) and hidden caries.

Each child underwent both procedures and served as his/her own control. Randomization of the techniques was determined by lots using numbered tiles. For each individual, one tooth was randomly selected for one treatment (also randomly selected) and the other tooth automatically received the other form of treatment.

Group 1 (G1) – chemo-mechanical caries removal with Papacarie™

Group 2 (G2) – removal of carious dentin with low-speed bur (traditional method - TM)

### Treatments

Treatments were performed by a single dentist who had previously undergone the calibration exercise (Kappa statistic: 0.92). All procedures were initiated without the prior administration of local anesthesia, but the patients were informed that anesthesia was available if needed.

#### G1 – Chemo-mechanical caries removal with Papacarie™

Initially, periapical radiographs were taken and prophylaxis was performed with a Robinson brush and fluoride toothpaste, followed by relative isolation (lip bumper, cotton roll and saliva aspirator) of the tooth. The starting time was then recorded. The Papacarie™ gel was applied. After 30 to 40 seconds, the softened carious tissue was removed with the blunt end of a curette. The gel was reapplied, if necessary, until the complete removal of the carious tissue. Successful removal was determined by clinical examination involving the inspection of the texture of the remaining dentine with the use of an exploratory probe (Figure 2). The finishing time was then recorded. The restorative procedure was performed with glass ionomer cement (Ketac Molar Easy mix – 3M ESPE™, São Paulo, SP, Brazil). The treated teeth were submitted to clinical and radiographic follow-up.

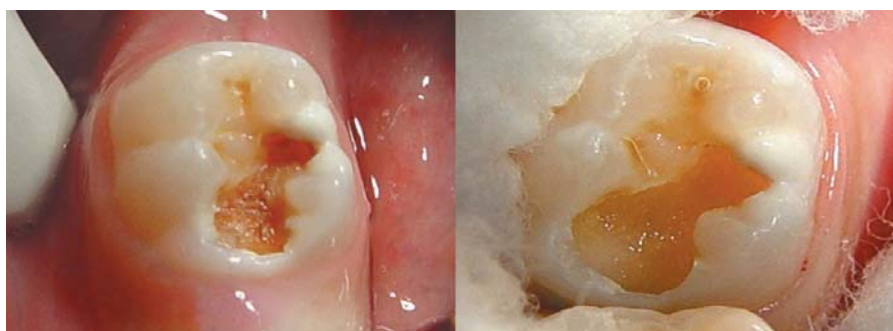#### G2 – Removal of carious dentin tissue with low-speed bur (traditional method)

The initial protocol was the same as that used for G1. Once the starting time was recorded, caries removal was performed with low-speed burs, followed by a clinical evaluation and recording of the finishing time. The restorative procedure was the same as that used in G1 and the treated teeth were submitted to clinical and radiographic follow-up.

### Evaluations

#### Evaluation of time required to perform procedure

The time required to perform the procedure was measured in minutes and seconds using a digital chronometer (Kenko®).



**Figure 2-** Clinical aspect of cavity before and after removal of carious tissue with chemo-mechanical caries removal

### Radiographic evaluation

Periapical radiographs were first taken to include or exclude teeth based on the previously-defined criteria. Immediately after the clinical procedure, the first interproximal radiograph was taken. This procedure was repeated in a standardized fashion on three different occasions. The radiographic evaluation was performed using the radiographic subtraction method and the assessment of the density of the remaining dentin immediately following the caries removal procedure as well as after one (T1), six (T2) and 18 (T3) months. Radiographic density was determined by gray-scale analysis.

A positioner for interproximal radiographs was used for standardization. A portion of self-curing acrylic resin was placed on the surface of the tooth analyzed and its antagonist for the impression of the anatomy of the surfaces and adapted to the positioner to allow the same positioning of the film in the different evaluations as well as the standardization of the same incidence of x-rays, the same vertical and horizontal angles and the same distance on all radiographs of the same patient. The interproximal radiographic images were scanned to allow the analysis of the difference in density between the different evaluation times using the Imagelab 2.3 program. Therefore, a greater degree of density on the image denoted greater success.

### Clinical evaluation

The clinical evaluation of the restorations followed the criteria of atraumatic restorative treatment<sup>22</sup>, based on the retention of the material in the cavity and the presence of secondary caries. The scoring system was as follows: 0=present, without defect; 1=present, small defects on the margin measuring less than 0.5 mm in depth, with no need for repair; 2=present, small defects on the margin measuring 0.5 to 1.0 mm in depth, with need for repair; 3=present, gross defects on the margin measuring 1.0 mm or more in depth, with need for repair; 4=absent, restoration completely lost, need for treatment; 5=absent, other treatment had been performed for some reason; 6=tooth absent for some reason; 7=present, wear on surface less than 0.5 mm, with no need for replacement; 8=present, wear on surface greater than 0.5 mm, with need for replacement; 9=diagnosis impossible<sup>12</sup>.

### Statistical analysis

The SPSS 12.0 program for Windows was used for the statistical analysis. The following tests were performed: t-test complemented by the Mann-Whitney test for differences in the mean time required for treatment; Wilcoxon test for data related to the clinical evaluation and differences between evaluation times; and analysis of variance

(ANOVA) complemented by Tukey's test for differences in mean radiographic density.

## RESULTS

The sample was made of 20 children (10 girls and 10 boys) between four and seven years of age.

No statistically significant difference was found between groups regarding the time required for the procedure ( $p=0.144$ ) (Table 1). The use of anesthesia was only necessary in one case (G2). The administration of anesthesia was considered in the analysis of the time required for treatment, but did not significantly increase the duration of the overall procedure.

Restorations having received a score of 0, 1 or 7 were considered successful and those having received a score of 2, 3, 4 or 8 were considered failures. Those having received a score of 5, 6 or 9 were excluded from the analysis. Evaluations were performed at one, six and 18 months after treatment. Table 2 displays the results of the evaluation of the restorations performed by an examiner who was blinded to the form of treatment employed prior to the restoration. Statistically significant differences between groups were found in the clinical evaluation at the six-month and 18-month evaluations.

At the one-month evaluation, all restorations in both groups were considered successful. At the six-month evaluation, 5% ( $n=1$ ) of the restorations in G1 and 10% ( $n=2$ ) of the restorations in G2 had failed and were repaired. At the 18-month evaluation, 95% of the restorations in G1 and 80% in G2 were successful, with no occurrence of secondary caries (Table 3).

In the radiographic analysis, mean density of the affected dentin was 80.02 in G1 and 80.13 in G2 immediately following treatment. Significant gains in density in the radiolucent zones (affected dentin) were found in the entire sample (Table 4), with no differences between groups at the different evaluation times (T1:  $p=0.874$ ; T2:  $p=0.661$ ; T3:  $p=0.653$ ).

**Table 1-** Time (in minutes) required for treatment in both groups

	CMCR	TM	p-value
Mean	4.66	3.30	
Standard deviation	3.13	2.03	0.144
Minimum	2.12	1.05	
Maximum	16.48	10.30	

CMCR=Chemo-mechanical caries removal  
TM=Traditional method

**Table 2-** Distribution of restoration scores at different clinical evaluations

Score	T1 (1 month)			T2 (6 months)			T3 (18 months)		
	CMCR n (%)	Trad. Method n (%)	p-value	CMCR n (%)	Trad. Method n (%)	p-value	CMCR n (%)	Trad. Method n (%)	p-value
0	13 (65.0)	13 (65.0)		6 (30.0)	13 (65.0)		6 (30.0)	7 (35.0)	
1	4 (20.0)	4 (20.0)		7 (35.0)	3 (15.0)		7 (35.0)	7 (35.0)	
2	1 (5.0)	0 (0.0)		0 (0.0)	2 (10.0)		1 (5.0)	4 (20.0)	
3	0 (0.0)	0 (0.0)		0 (0.0)	0 (0.0)		0 (0.0)	0 (0.0)	
4	0 (0.0)	0 (0.0)		0 (0.0)	0 (0.0)		0 (0.0)	0 (0.0)	
5	0 (0.0)	0 (0.0)	0.936	0 (0.0)	0 (0.0)	0.010	0 (0.0)	0 (0.0)	0.023
6	0 (0.0)	0 (0.0)		0 (0.0)	0 (0.0)		0 (0.0)	0 (0.0)	
7	2 (10.0)	3 (15.0)		7 (35.0)	2 (10.0)		6 (30.0)	2 (10.0)	
8	0 (0.0)	0 (0.0)		0 (0.0)	0 (0.0)		0 (0.0)	0 (0.0)	
9	0 (0.0)	0 (0.0)		0 (0.0)	0 (0.0)		0 (0.0)	0 (0.0)	
Total	20 (100.0)	20 (100.0)		20 (100.0)	20 (100.0)		20 (100.0)	20 (100.0)	

CMCR=Chemo-mechanical caries removal

**Table 3-** Clinical classification at different evaluation times

	T1		T2		T3	
	CMCR n (%)	Trad. Method n (%)	CMCR n (%)	Trad. Method n (%)	CMCR n (%)	Trad. Method n (%)
Success	20 (100.0)	20 (100.0)	19 (95.0)	18 (90.0)	19 (95.0)	16 (80.0)
Failure	0 (0.0)	0 (0.0)	1 (5.0)	2 (10.0)	1 (5.0)	4 (20.0)
Total	20 (100.0)	20 (100.0)	20 (100.0)	20 (100.0)	20 (100.0)	20 (100.0)

CMCR=Chemo-mechanical caries removal

**Table 4-** Mean radiographic density (gray scale) of radiolucent zone in both groups at different evaluation times

	CMCR			TM		
	T1	T2	T3	T1	T2	T3
Mean density	800.295	873.340	1.021.260	801.385	883.555	1.017.745
Standard deviation	130.223	173.329	184.447	139.732	141.939	262.140
p-value T1 X T2	<0.01			<0.01		
p-value T2 X T3	<0.01			<0.01		

CMCR=Chemo-mechanical caries removal

TM=Traditional method

## DISCUSSION

No statistically significant difference between groups was found regarding the time required to perform the different procedures. This is in agreement with findings described by Kotb, et al.<sup>16</sup> (2009). However, other researchers have investigated this issue and report that CMCR with Papacarie™ requires a shorter execution time in comparison to conventional treatment<sup>8,13</sup>. While

execution time is essential in any dental procedure, especially in the treatment of children, anxious adults and individuals with disabilities<sup>7</sup>, CMCR should be considered based on the fact that it causes less patient discomfort<sup>3,20</sup> and is in line with the philosophy of minimally invasive treatment<sup>4-6</sup>. This was evidenced by Bohari, et al.<sup>3</sup> (2012), who compared four methods (burs, Carisolv™, Papacarie™ and Laser), as CMCR and laser are minimally invasive methods and considered less

painful. Similar results are described in another study<sup>15</sup>.

In all the cases examined in the present study, the radiographic analysis revealed an increase in density in the affected dentin, demonstrating the success of treatment. The philosophy of minimally invasive treatment involves the maximum preservation of sound dental tissue that is capable of remineralization<sup>11,21</sup>, which is what remains after the use of the gel. The outermost layer – denominated the infected dentin tissue – is irreversibly denatured, infected, incapable of remineralization and dead. The innermost layer – denominated the affected dentin tissue – is reversibly denatured, slightly infected or non-infected, capable of remineralization, sensitive and vital. In minimally invasive treatment, the former layer should be removed and the latter should be preserved<sup>14</sup>. Assessments of the mineral content following the use of Papacarie™ on deciduous teeth suggest that this gel only acts on carious tissue<sup>2</sup>.

Studies have also shown the lack of a smear layer after the use of Papacarie™, along with the deposition of minerals around the dentinal tubules<sup>10,13</sup>, which may have contributed to the clinical success of the restorations following CMC. The conventional method achieved an 80% success rate after 18 months. This may have occurred due to the fact that the use of a bur removes more enamel, which can affect the subsequent adhesion of the restoration and inherently leads to the formation of a smear layer. The cavity size is the same, but the support structure may be more compromised. It should be stressed that the manufacturer's recommendations were followed for the restorative procedure in both groups, including the use of polyacrylic acid for 15 seconds in the pretreatment of the surface. This is a weak acid and there may have been residual remnants after its use, which would also affect the adhesion mechanism<sup>26</sup>. With the use of Papacarie™, there is no formation of a smear layer. Moreover, studies addressing bond strength report satisfactory results with Papacarie™<sup>12,17</sup>, whereas polyacrylic acid is a weak acid and partially removes the smear layer, which implies lesser mechanical imbrication.

Clinical success has also been reported in a study carried out by Bussadori, et al.<sup>5</sup> (2011) involving young permanent molars treated with Papacarie™ and restored with glass ionomer cement, for which 13 of the 14 cases were successful throughout the 24-month follow-up period.

Survival rates of the restoration materials are related to factors such as the presence of secondary caries, fractures, type of tooth and pulp vitality<sup>26</sup>. Despite the occurrence of failed restorations, no secondary carious lesions were found in either of the groups. This may be attributed to the inherent

properties of the restoration material, such as adhesiveness to dental tissue, biocompatibility and the release of fluoride ions<sup>9</sup>. A previous study involving restorations on the occlusal-proximal surface reports the susceptibility to the loss of restoration material in proximal areas. Defects in this region resemble carious lesions and plaque is thought to play an important role in this process<sup>24</sup>.

Based on the present findings, both Papacarie™ and the traditional caries removal method are effective on deciduous teeth. However, Papacarie™ offers the advantages of preserving sound dental tissue, as the disorganized tissue is removed with blunt manual instruments, thereby avoiding the use of a bur and local anesthesia.

## ACKNOWLEDGMENTS

The authors would like to thank the volunteers for their participation. This study was funded by FAPESP – São Paulo Research Foundation (Grant no. 2008/08642-3).

## REFERENCES

- 1- Balciuniene I, Sabalaite R, Juskiene I. Chemo-mechanical caries removal for children. *Stomatologija*. 2005;7:40-4.
- 2- Bittencourt ST, Pereira JR, Rosa AW, Oliveira KS, Ghizoni JS, Oliveira MT. Mineral content removal after Papacarie application in primary teeth: a quantitative analysis. *J Clin Pediatr Dent*. 2010;34:229-31.
- 3- Bohari MR, Chunawalla YK, Ahmed BM. Clinical evaluation of caries removal in primary teeth using conventional, chemo-mechanical and laser technique: an *in vivo* study. *J Contemp Dent Pract*. 2012;13:40-7.
- 4- Bussadori SK, Castro LC, Galvão AC. Papain gel: a new chemo-mechanical caries removal agent. *J Clin Pediatr Dent*. 2005;30:115-9.
- 5- Bussadori SK, Guedes CC, Bachiega JC, Santis TO, Motta LJ. Clinical and radiographic study of chemical-mechanical removal of caries using Papacarie: 24-month follow up. *J Clin Pediatr Dent*. 2011;35:251-4.
- 6- Bussadori SK, Guedes CC, Hermida Bruno ML, Ram D. Chemo-mechanical removal of caries in an adolescent patient using a papain gel: case report. *J Clin Pediatr Dent*. 2008;32:177-80.
- 7- Caro TE, Aguilar AA, Saavedra JH, Alfaya TA, França CM, Fernandes KP, et al. Comparison of operative time, costs and self-reported pain in children treated with atraumatic restorative treatment and conventional restorative treatment. *Med Sci Tech*. 2012;53:159-63.
- 8- Carrillo CM, Tanaka MH, Cesar MF, Camargo MA, Juliano Y, Novo NF. Use of papain gel in disabled patients. *J Dent Child (Chic)*. 2008;75:222-8.
- 9- Chadwick BL, Evans DJ. Restoration of class II cavities in primary molar teeth with conventional and resin modified glass ionomer cements: a systematic review of the literature. *Eur Arch Paediatr Dent*. 2007;8:14-21.
- 10- Corrêa FN, Rocha RO, Rodrigues Filho LE, Muench A, Rodrigues CR. Chemical versus conventional caries removal techniques in primary teeth: a microhardness study. *J Clin Pediatr Dent*. 2007;31:187-92.
- 11- Ericson D, Kidd E, McComb D, Mjör I, Noack MJ. Minimally Invasive Dentistry - concepts and techniques in cariology. *Oral Health Prev Dent*. 2003;1:59-72.

- 12- Gianini RJ, Amaral FL, Florio FM, Basting RT. Microtensile bond strength of etch-and-rinse and self-etch adhesive systems to demineralized dentin after the use of a papain-based chemo-mechanical method. *Am J Dent.* 2010;23:23-8.
- 13- Jawa D, Singh S, Somani R, Jaidka S, Sirkar K, Jaidka R. Comparative evaluation of the efficacy of chemo-mechanical caries removal agent (Papacarie) and conventional method of caries removal: an *in vitro* study. *J Indian Soc Pedod Prev Dent.* 2010;28:73-7.
- 14- Kidd EA, Joyston-Bechal S, Beighton D. Microbiological validation of assessments of caries activity during cavity preparation. *Caries Res.* 1993;27:402-8.
- 15- Kochhar GK, Srivastava N, Pandit IK, Gugnani N, Gupta M. An evaluation of different caries removal techniques in primary teeth: a comparative clinical study. *J Clin Pediatr Dent.* 2011;3:5-9
- 16- Kotb RM, Abdella AA, El Kateb MA, Ahmed AM. Clinical evaluation of Papacarie in primary teeth. *J Clin Pediatr Dent.* 2009;34:117-23.
- 17- Lopes MC, Mascarini RC, Silva BM, Flório FM, Basting RT. Effect of a papain-based gel for chemomechanical caries removal on dentin shear bond strength. *J Dent Child (Chic).* 2007;74:93-7.
- 18- Martins MD, Fernandes KP, Motta LJ, Santos EM, Pavesi VC, Bussadori SK. Biocompatibility analysis of chemo-mechanical caries removal material Papacarie on cultured fibroblasts and subcutaneous tissue. *J Dent Child (Chic).* 2009;76:123-9.
- 19- Mathre S, Kumar S, Sinha S, Ahmed BM, Thanawala EA. Chemo-mechanical method of caries removal: a brief review. *IJCDs.* 2011;2:52-7.
- 20- Mickenautsch S, Yengopal V, Banerjee A. Atraumatic restorative treatment versus amalgam restoration longevity: a systematic review. *Clin Oral Investig.* 2010;14:233-40.
- 21- Murdoch-Kinch CA, McLean ME. Minimally invasive dentistry. *J Am Dent Assoc.* 2003;134:87-95.
- 22- Phantumvanit P, Songpaisan Y, Pilot T, Frencken JE. Atraumatic restorative treatment (ART): a three-year community field trial in Thailand - survival of one-surface restorations in the permanent dentition. *J Public Health Dent.* 1996;56:141-5; discussion 61-3.
- 23- Piva E, Ogliari FA, Moraes RR, Corá F, Henn S, Correr-Sobrinho L. Papain-based gel for biochemical caries removal: influence on microtensile bond strength to dentin. *Braz Oral Res.* 2008;22:364-70.
- 24- Scholtanus JD, Huysmans MC. Clinical failure of class-II restorations of a highly viscous glass-ionomer material over a 6-year period: a retrospective study. *J Dent.* 2007;35:156-62.
- 25- Van de Sande FH, Opdam NJ, Rodolpho PA, Correa MB, Demarco FF, Cenci MS. Patient risk factors' influence on survival of posterior composites. *J Dent Res.* 2013;92:78S-83S
- 26- Van Meerbeek B, De Munck J, Yoshida Y, Inoue S, Vargas M, Vijay P, et al. Buonocore memorial lecture. Adhesion to enamel and dentin: current status and future challenges. *Oper Dent.* 2003;28:215-35.