





# Ultrasonographic analysis of palatal donor site healing accelerated with platelet-rich fibrin following subepithelial connective tissue harvesting

## Abstract

Gizem TORUMTAY CİN<sup>1</sup>   
Aysan LEKTEMUR ALPAN<sup>1</sup>   
Gözde AÇIKGÖZ<sup>2</sup>   
Gülfem ÖZLÜ UÇAN<sup>3</sup> 

**Objective:** Platelet-rich fibrin (PRF) contains a variety of growth factors and bioactive molecules that play crucial roles in wound healing and angiogenesis. We aimed to evaluate the effects of PRF on tissue thickness and vascularization of the palatal donor site by ultrasound (USG) following subepithelial connective tissue harvesting. **Methodology:** A subepithelial connective tissue graft was harvested from the palatal region with a single incision for root coverage in 20 systemically healthy patients. In the test group (n = 10), the PRF membrane was placed at the donor site, whereas no material was applied in the control group (n=10). Palatal tissue thickness (PTT) and pulsatility index (PI) were evaluated by USG at baseline and on the 3<sup>rd</sup>, 7<sup>th</sup>, 14<sup>th</sup>, 30<sup>th</sup>, and 90<sup>th</sup> days after surgery. The early healing index (EHI) was used to evaluate donor site healing for 30 days. **Results:** PTT was significantly higher in the PRF group on the 3<sup>rd</sup> and 14<sup>th</sup> days after surgery when compared to the controls. In the PRF-treated group, PI levels were significantly higher than in the controls, especially on the 14<sup>th</sup> day. PTT increased significantly 90 days after surgery compared to the test group baseline, but controls showed a significant decrease. The PRF group showed statistically significant improvements in EHI scores compared to controls on days 3, 7, and 14. This study found a negative correlation between PI values and EHI scores on postoperative days three and seven in the test group. **Conclusion:** USG is a non-invasive, objective method to radiographically evaluate the regenerative effects of PRF on palatal wound healing after soft tissue harvesting. To overcome graft inadequacy in reharvesting procedures, PRF application may enhance clinical success and reduce possible complications by increasing tissue thickness and revascularization in the donor area.

**Keywords:** Platelet-rich fibrin. Ultrasonography. Wound healing. Blood flow. Palate. Regeneration.

Corresponding address:  
Gizem Torumtay Cin  
Pamukkale University - Faculty of Dentistry -  
Department of Periodontology - Kınıklı Campus -  
Denizli - Turkey.  
Phone: + 90 02582694489  
e-mail: gyaprak\_dt@hotmail.com

Received: December 15, 2023  
Revised: February 15, 2024  
Accepted: February 21, 2024

Editor: Ana Carolina Magalhães  
Associate Editor: Renato Silva

<sup>1</sup>Pamukkale University, Faculty of Dentistry, Department of Periodontology, Denizli, Turkey.

<sup>2</sup>Pamukkale University, Faculty of Dentistry, Department of Oral and Maxillofacial Radiology, Denizli, Turkey.

<sup>3</sup>Gelişim University, Faculty of Dentistry, Department of Oral and Maxillofacial Radiology, İstanbul, Turkey.



## Introduction

Palatal connective tissue harvesting has been widely used in periodontal plastic surgery procedures. Mucogingival surgery with connective tissue is used both around implants and on natural teeth. Coronally advanced flap with a subepithelial connective tissue graft (sCTG) is considered the gold standard for treating single gingival recession defects.<sup>1</sup> The increasing use of dental implants has brought a renewed interest in the use of sCTG in implant surgery to improve soft tissue thickness<sup>2</sup> or marginal bone level stability<sup>3</sup> to treat gingival/mucosal recessions.<sup>4</sup> Although harvesting of sCTG can be performed from the maxillary tuberosity or edentulous ridges, the palate remains the most common donor site. Several modifications of harvesting techniques for sCTG have been suggested in terms of the number of incisions and flap design.<sup>5</sup> Among these, the single incision technique achieves the primary goal at the donor site and very little postoperative morbidity to the patient.<sup>6</sup> However, even if closed with a suture, the formation of a second surgical wound area in the mouth increases the discomfort of patients.<sup>7</sup> Various complications can arise within the donor site, such as necrosis of the palate mucosa, increased pain, excess bleeding, long-term discomfort, donor site infection, and paresthesia.<sup>8-10</sup> Furthermore, the same donor area must often be used repeatedly for successive grafting procedures due to limitations from insufficient tissue for grafting or vascular anatomy. In a histologic study conducted in humans, the early retrieval of connective tissue from patients indicated that the quality of the autogenous graft was poor and showed that connective tissue remodeling was still in progress and not as mature as the samples recorded at weeks nine to 47.<sup>11</sup>

After the removal of the soft tissue, the palatal wound heals in four partially overlapping stages: hemostasis, inflammation, granulation, and maturation.<sup>12</sup> Cytokines and growth factors are involved in every stage of wound healing and play very important roles. To reduce morbidity in the palatal region, researchers have performed applications such as cyanoacrylate tissue adhesive,<sup>13</sup> low-level laser therapy,<sup>14</sup> and platelet-rich fibrin (PRF) derivatives.<sup>15</sup> Blood is the vehicle that brings inflammatory cells to the site of injury. Besides phagocytes that cleanse the wound, white blood cells and platelets release important cellular mediators such as transforming

growth factor-beta 1 (TGF- $\beta$ 1), platelet-derived growth factor (PDGF), vascular endothelial growth factor (VEGF), and insulin-like growth factor 1 (IGF1), which mediate cell migration, proliferation, and differentiation and initiate the healing process.<sup>16</sup> Many platelet concentrations have been developed based on these properties of platelets.<sup>17,18</sup> Over the years, several versions of PRF have been developed, including adhesive bone (autologous fibrin glue mixed with a bone graft) by Sohn<sup>19</sup> (2010); titanium platelet-rich fibrin (T-PRF), which was centrifuged in titanium tubes to prevent silica transport to the patient by Tunali, et al.<sup>20</sup> (2014); advanced PRF (A-PRF) with a low centrifugation approach, significantly increasing the number of inflammatory cells and growth-promoting substances, thus increasing regeneration capacity by Choukroun<sup>21</sup> (2014); and injectable PRF (i-PRF), by Mourão, et al.<sup>22</sup> (2015), as an improved form of PRF due to its injectable nature; enhanced by slower and shorter centrifugation. PRF, i.e., the second-version platelet concentration, contains many growth factors involved in tissue regeneration, including PDGF, IGF, TGF, epidermal growth factor (EGF), fibroblast growth factor (FGF)m and VEGF.<sup>23,24</sup> The complex 3D fibrin structure also acts as a biocompatible structural matrix and serves as a reservoir for growth factors and the leukocytes.<sup>24</sup>

Ultrasonography (USG) is a noninvasive screening tool widely applied in the medical field that is based on the reflection of ultrasound waves at the interface of tissues with different acoustic properties.<sup>25</sup> USG offers real-time monitoring and is non-ionizing, cost-effective, portable, and comfortable for patients.<sup>26</sup> Several types of ultrasound devices are available, among which color and power Doppler USG methods can assess the presence, direction, and velocity of blood flow in the examined tissue. Preclinical studies also have shown that measurements conducted in USG images have higher accuracy than micro-CT estimations.<sup>27,28</sup> USG has been assessed for measuring the dimensions of the periodontium to assess alveolar bone level,<sup>26,29</sup> gingiva thickness,<sup>30</sup> and color power (CP) and velocity (CV), functions for assessing the blood flow.<sup>31</sup> The absence of ionizing radiation to acquire the image is the most important advantage of the USG in assessing diseases in the human body.<sup>32</sup> We hypothesized that PRF application to the palatal area after sCTG harvesting could increase palatal tissue thickness and vascularity throughout a three-month

follow-up period when compared to the controls. Therefore, this study aimed to evaluate the effects of the PRF membrane on soft tissue donor site healing, vascularization pattern, and palatal tissue thickness after harvesting sCTG by a comparison with the control group using color Doppler USG.

## Methodology

### Study design and participants

This study was designed as a prospective, randomized, controlled clinical trial with an observation period of 90 days. The ethics protocol was approved with protocol number (16.08.2022/12) by the Ethics Committee of Pamukkale University and was administered according to the Declaration of Helsinki. It was also registered at ClinicalTrials.gov (NCT06118177). This study was carried out from September 2022 to October 2023 with 20 participants who underwent root coverage surgery at the Department of Periodontology and USG examinations at the Department of Oral and Maxillofacial Radiology. All participants signed an informed consent form before the interventions.

Overall, 20 systemically healthy and non-smoking patients (seven men and 13 women) who needed sCTG for root coverage surgery were included in this study.

Inclusion criteria:

Patients aged from 18 to 65 years

Patients with a full-mouth plaque index (FMPI) <15% and a full-mouth bleeding score (FMBS) <10%

No gag reflex

No previous periodontal surgery performed in the operation area

Exclusion criteria:

Any systemic disease concerning impaired wound healing (uncontrolled diabetes, immunologic disorders, receiving chemotherapy or radiotherapy)

Pregnant or breastfeeding women

Chronic use of analgesic and anti-inflammatory medications

Unwillingness to sign an informed consent form

Participants were randomly assigned to the test (PRF) or control groups with the toss-of-a-coin method by a person uninvolved in this study. The power analysis of this study was performed for sample size calculation. Sample size was calculated on a statistical software (G\*Power; Universitat, Dusseldorf, Germany). According to the power analyses of a previous study, at least 10 subjects per group achieved a power of 82% with 95% confidence.<sup>33</sup> A flow diagram according to the CONSORT is shown in Figure 1. The primary outcome of this study referred to the difference in palatal tissue thickness between groups in the evaluation times throughout the 90-day study period. The secondary outcome referred to changes in pulsatility index (PI) levels in the groups.

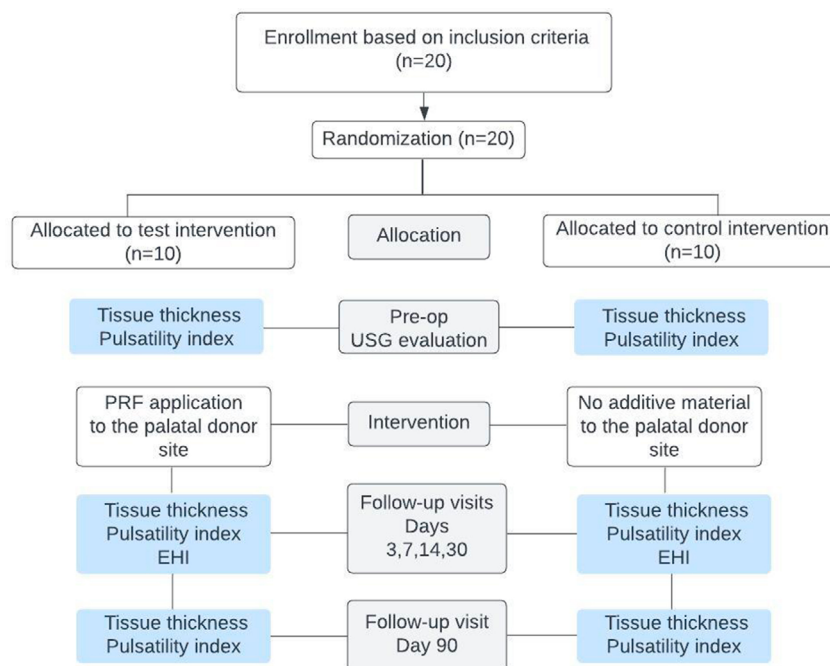


Figure 1- Flowchart of the study design

## Surgical intervention

All surgeries were performed by the same operator (GTC) under local anesthesia (2% lidocaine with 1:100,000 epinephrine) to minimize differences in surgical technique. Once local anesthesia was applied to the palate, the size of the donor area was measured with a Williams periodontal probe (12 mm in length) to standardize the graft dimensions in all patients. In all patients, a side of the palate was unilaterally determined as the donor site. A single incision was performed on the palatal tissue from the region between the mesial of the canine and the mesial of the first molar using a #15C blade. Following the first incision made at least 2 mm apical to the gingival margin, a split-thickness dissection was performed to separate the connective tissue from the epithelium. The connective tissue was bordered using four internal incisions under the epithelium, followed by a periosteal elevator to separate the connective tissue from the soft palate and remove it. The final connective tissue dimensions totaled about 10×5×2 mm. SCTG thickness in each patient was measured using an endodontic reamer and digital caliper at three points after graft harvesting and its mean value was calculated. In the area from which the connective tissue was removed, a single layer of PRF membrane was gently placed under the epithelium in the test group, whereas no material was applied in the control group. Lastly, the incision line was sutured with a 5/0 synthetic, non-absorbable, sterile monofilament suture (Trofilen, Doğsan, Turkey). The same suture technique was used in the palatal region in both groups.

## PRF preparation

Before surgery, a 10-mL venous blood sample was collected from the antecubital veins of participants into glass-coated plastic tubes. PRF membranes were produced using a Duo centrifuge with a protocol of 2800 rpm (RCF-max=897 g) for 12 minutes utilizing a 40° rotor angulation with a radius of 87 mm at clot and 110 mm at maximum (Process for PRF, Nice, France). The PRF located in the middle portion of the tube was separated from other blood components using a clamp and then placed in a PRF box (OSUNG MND Co., Ltd., Gimpo-si, Korea) to optimize PRF thickness.

## Postoperative process

Participants were prescribed an analgesic (500 mg paracetamol) and oral spray (0.2% chlorhexidine,

2x1, 1 week). Participants were monitored in the periodontology clinic on days three, seven, 14, and 30 for their early healing index (EHI), which evaluates the quality of healing of the donor site, as previously described<sup>7</sup> by one periodontist (ALA) who was blinded to allocation. The calibration of the periodontist who evaluated the healing was achieved with four patients. However, since the EHI may change from day to day, one patient was determined for each study day. The data required for intraobserver calibration was obtained by repeating patients' evaluations a few hours later. Intraobserver agreement was assessed using the intraclass correlation coefficient (ICC). ICC estimates and 95% confidence intervals were calculated using the SPSS statistical package, version 21 (SPSS Inc, Chicago, IL), based on absolute agreement and the two-way mixed effects model and totaled 0.99.

## Ultrasonography examination

All patients were evaluated using the USG device (MyLab™ Seven, Esaote, Genoa, Italy) at the Department of Oral and Maxillofacial Radiology. USG examinations were performed before graft harvesting and the 3<sup>rd</sup>, 7<sup>th</sup>, 14<sup>th</sup>, 30<sup>th</sup>, and 90<sup>th</sup> days after the operation by the same blinded oral and maxillofacial radiologist (GA). To test the calibration of the radiologist, measurements were repeated in six patients two hours apart. The ICC value was 0.95 with 95% confidence intervals.

An intraoral transducer probe at a frequency from 6 to 18 MHz was used in intraoral USG examinations. The intraoral probe was covered with a sterile ultrasound coupling gel and wrapped in a stretch film for examination. First, this probe was placed directly on the relevant mucosa in a transverse position and it was localized with real-time, gray-scale sonography. Palatal tissue thickness and vascularization (pulsatility index-PI) of the relevant areas were evaluated and recorded.

Palatal tissue thickness was measured using the B-mode from the three thickest points in the relevant palatal area, between the mesial of the canine and the mesial of the first molar, and its average was recorded. Also, the PI value was evaluated using the color Doppler and pulsed-wave Doppler modes. The probe was held in a position that enabled continuous color Doppler measurement, and blood flow was detected by color Doppler mapping of the mucosa. Color Doppler gain was decreased until only a few random specks

remained visible. Then, the pulsed wave Doppler mode was used by focusing on the center of the flow signals, and the PI value was measured.

### Statistical analyses

The data were analyzed on SPSS 21 (SPSS Inc., Chicago, IL). Continuous variables were described as mean  $\pm$  standard deviation and categorical variables, as numbers and percentages. The Shapiro-Wilk test was used to detect data normality. To compare the parameters of the study groups, an independent sample T-test was used for normally distributed data, whereas the Mann-Whitney U test was performed as a non-parametric test. Within-group comparisons between time periods were tested by repeated measures ANOVA. The Bonferroni correction was performed for multiple variations. Spearman's correlation analysis was conducted to investigate the associations between PI values and EHI scores in the groups. The statistical significance value was accepted as  $p < 0.05$ .

## Results

A total of 20 patients participated in this study. Table 1 shows their demographic characteristics. Baseline mean palatal tissue thickness and PI values were similar in both groups ( $p > 0.05$ ).

When this study analyzed EHI scores, the PRF group showed statistically significant improvements compared to the control group on days 3, 7, and 14, respectively ( $p = 0.020$ ,  $p = 0.013$ ,  $p = 0.048$ ) (Figure 2). At day 30, groups showed no significant differences ( $p = 1.000$ ). This research found a significant difference between control periods, except between 14 and 30 days after surgery in the PRF group. Intragroup EHI

value analysis in the control group showed significant differences between days 7 and 14 ( $p = 0.019$ ) and between 14 and 30 ( $p = 0.025$ ).

Table 2 shows postoperative palatal tissue thickness and PI values for the groups throughout the evaluation period. Palatal tissue thickness was significantly higher in the PRF group on the 3<sup>rd</sup> and 14<sup>th</sup> days after the operation when compared to the controls. PI values were significantly higher in the PRF group at 14<sup>th</sup> days, but the test and control groups showed no significant differences at three, seven, 30, and 90 days. Figure 3 shows palatal tissue thickness and vascularization pattern measured by USG in both groups.

Figure 4 shows the intra-group analyses for palatal tissue thickness and PI levels at follow-ups. Palatal tissue thickness increased significantly from baseline to seven days in the control group ( $p = 0.005$ ). While palatal tissue thickness was significantly higher at three days postoperative in the test group, it was significantly lower at seven days when compared to three days ( $p = 0.005$ ). A significant decrease in palatal tissue thickness occurred in both groups between seven and 14 days, and more dramatically so in the control group ( $p = 0.005$  for both groups). Palatal tissue thickness significantly increased at 90 days when compared to the baseline in the test group and controls showed a significant decrease ( $p = 0.005$  and  $p = 0.008$  respectively).

Both groups showed a significant increase in PI values at three days after baseline ( $p = 0.005$ ) and both groups showed a slight decrease between three and seven days. However, this study found a significant increase in PI levels in both groups between seven and fourteen days as being higher in the test group ( $p = 0.005$  and  $p = 0.009$  for the test and control group respectively). While PI values significantly decreased after postoperative 14<sup>th</sup> days up to 90 follow-up days, they remained significantly higher in both groups at 90

**Table 1-** Demographic data and baseline characteristics of the palatal donor site

Variables	Test group	Control group	P-value
Age (mean $\pm$ SD) (years)	38.30 $\pm$ 9.88	39.20 $\pm$ 11.22	0.851
Female	6	7	0.639
Male	4	3	
FMBS %	8.76 $\pm$ 1.42	8.68 $\pm$ 1.23	0.815
FMPS %	13.56 $\pm$ 2.17	12.86 $\pm$ 2.32	0.775
Palatal tissue thickness (mm)	4.12 $\pm$ 0.47	4.09 $\pm$ 1.03	0.948
Pulsatility index (cm/s)	0.66 $\pm$ 0.25	0.72 $\pm$ 0.41	0.850
Harvested sCTG thickness (mean $\pm$ SD)	1.89 $\pm$ 0.15	1.85 $\pm$ 0.21	0.597

\*FMBS, full mouth bleeding score; FMPS, full mouth plaque score

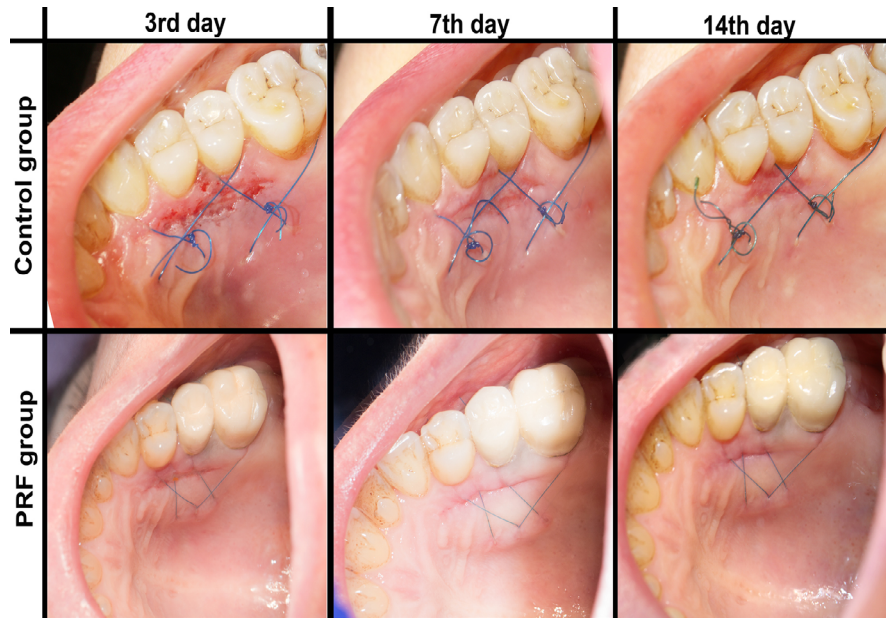

Figure 2- In situ images of donor site healing of groups on the third, seventh, and 14<sup>th</sup> days

Table 2- Comparison of postoperative palatal tissue thickness and pulsatility index between PRF and control groups

Follow-up visit	Palatal tissue thickness (mm)			Pulsatility index (cm/s)			EHI scores		
	Test group	Control group	P value	Test group	Control group	P value	Test group	Control group	P value
Day 3	6.51±0.30	4.64±0.97	<b>0.000</b>	3.04±0.64	2.92±0.62	0.675	2.30±0.48	2.90±0.56	<b>0.020</b>
Day 7	5.56±0.38	5.47±1.04	0.785	2.78±0.55	2.79±0.51	0.974	1.80±0.63	2.70±0.82	<b>0.013</b>
Day 14	4.81±0.39	3.65±1.09	<b>0.006</b>	4.10±0.88	3.18±0.66	<b>0.016</b>	1.10±0.31	1.50±0.52	<b>0.048</b>
Day 30	4.15±0.53	3.89±1.00	0.482	1.41±0.45	1.27±0.27	0.429	1.00±0.00	1.00±0.00	1.000
Day 90	4.48±0.47	3.99±0.99	0.176	1.03±0.22	0.97±0.29	0.585			
Within group p-value	<b>0.000</b>	<b>0.000</b>		<b>0.000</b>	<b>0.000</b>		<b>0.000</b>	<b>0.000</b>	

\*Statistically significant differences are indicated in bold (p<0.05 and p<0.001)

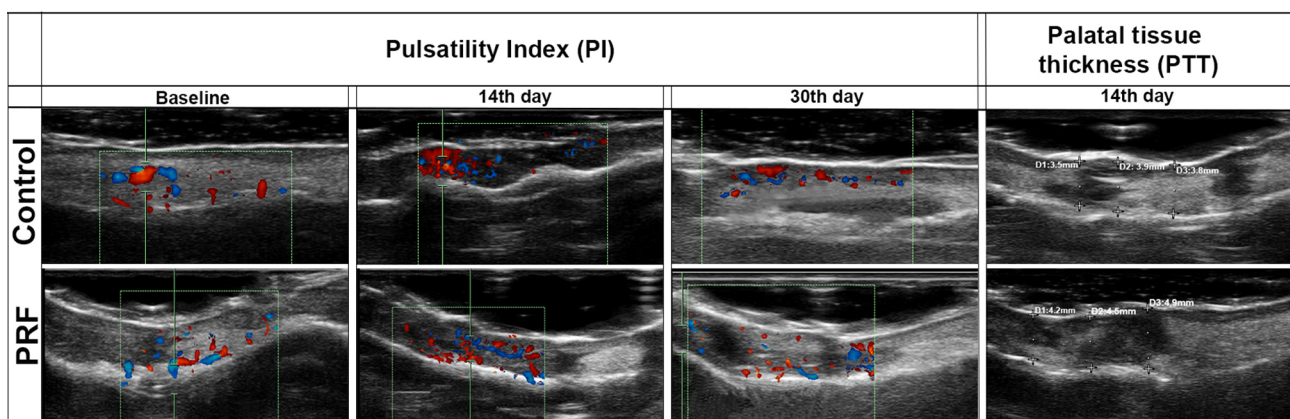


Figure 3- Blood flow was displayed in the wound area using pulsed-wave Doppler modes at baseline, 14<sup>th</sup>, and 30<sup>th</sup> days and palatal tissue thickness was measured using the B-mode from several points on the 14<sup>th</sup> day

days compared to the baseline (p=0.005 and p=0.008 for the test and control group respectively).

Table 3 shows the correlations between PI values and EHI scores in the 14-day postoperative period. While mean PI values on the 3<sup>rd</sup> day were inversely

correlated with EHI scores on the 3<sup>rd</sup> and 7<sup>th</sup> days in the test group, the control group showed a negative correlation on the 3<sup>rd</sup> and 14<sup>th</sup> days in the control group. Both groups showed no correlation between palatal tissue thickness and PI values at any time point.

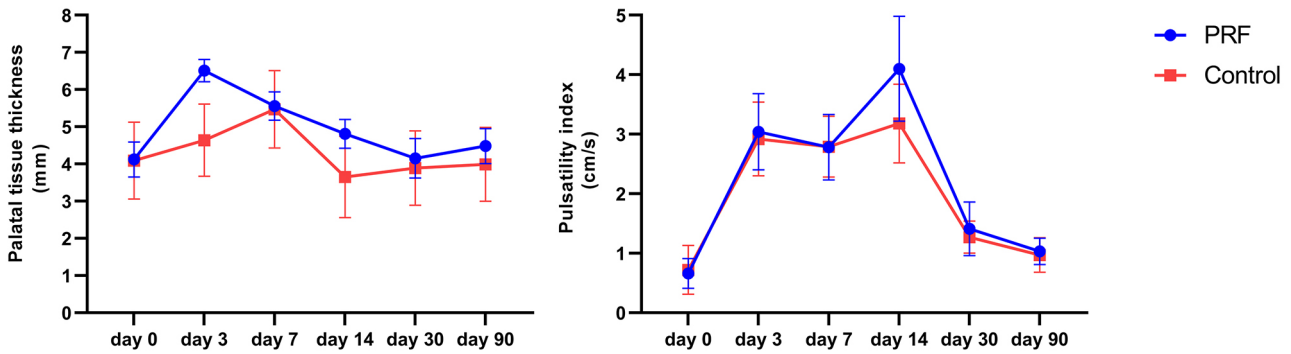


Figure 4- Comparisons of palatal tissue thickness and PI levels of groups at baseline and postoperative evaluation periods

Table 3- Correlations between pulsatility index and EHI in groups at different time points

	Test group			Control group		
	EHI3	EHI7	EHI14	EHI3	EHI7	EHI14
PI3	<b>r=-0.798</b>	<b>r=-0.776</b>	r=-0.290	<b>r=-0.676</b>	r=-0.610	r=-0.524
	<b>p=0.006</b>	<b>p=0.008</b>	p=0.416	<b>p=0.032</b>	p=0.061	p=0.120
PI7		<b>r=-0.749</b>	r=-0.522		r=-0.303	r=-0.313
		<b>p=0.013</b>	p=0.122		p=0.395	p=0.378
PI14			r=-0.174			<b>r=-0.731</b>
			p=0.631			<b>p=0.016</b>

\*PI, pulsatility index; EHI, early healing index. Statistically significant differences are indicated in bold (p<0.05)

## Discussion

This study evaluated the effects of PRF membrane application to the palatal donor site on tissue thickness and vascularization after sCTG harvesting using the USG method for three months. PRF application to the palatal region significantly increased PI levels (especially on day 14), increased palatal tissue thickness, and provided better EHI scores than in the control group. Also, higher PI values were associated with lower EHI scores at three and seven days in the PRF group.

Cases in which the amount of autogenous tissue graft in root coverage treatment is limited may require more than one surgical procedure and repeated graft harvesting from the same palatal region.<sup>34</sup> Donn<sup>35</sup> (1978) stated that the donor area can usually be re-accessed to obtain recurrent connective tissue graft one month after palatal healing. Contrary to this finding, Soileau and Brannon reported that connective tissue remodeling after graft harvesting with a parallel incision technique was completed after nine weeks, and harvesting from the donor site earlier than 63 days may result in poor autogenous graft quality.<sup>11</sup>

The wound healing cascade following soft tissue harvesting consists of a series of phases following several growth factors secreted in platelets and

numerous chemical messages. These growth factors and cytokines stimulate fibroblasts and other cells to promote angiogenesis and connective tissue biosynthesis.<sup>36</sup> The PRF membrane plays an important role in wound healing by mechanisms that accelerate epithelial proliferation, angiogenesis, and immunity by releasing significant amounts of growth factors.<sup>37</sup> Most studies have defined platelet concentrations and their regenerative role in soft tissue wound healing.<sup>38-40</sup> However, only a few researchers have examined the potential role of platelet derivatives in accelerating palatal healing after sCTG harvesting. Lektemur Alpan and Torumtay Cin<sup>15</sup> (2020) reported significantly improving healing scores by applying PRF membrane to the donor region after obtaining the connective tissue with a single incision. Yen, et al.<sup>41</sup> (2007) clinically and histologically investigated the effects of platelet concentrate (PC) gel on palatal healing after sCTG harvesting by using a horizontal parallel incision technique. They found that palatal tissue thickness was significantly higher in PC gel-treated sites than in controls treated with a collagen sponge at postoperative six weeks. Also, histological analyses indicated lower inflammatory cell concentrations, less type-III immature collagen, and more type-1 mature collagen in PC gel-treated sites than in controls during wound healing. In this study, palatal tissue thickness

was significantly higher in the PRF-applied group than in controls at three ( $p=0.000$ ) and fourteen days ( $p=0.006$ ) after the interventions. In the test group, tissue thickness increased significantly in the first days and started to decrease afterward. This may be due to the beginning of the PRF membrane resorption placed into the wound area. In the control group, tissue thickness increased gradually until seven days and decreased significantly between seven and 14 days. The placement of titanium-prepared platelet-rich fibrin (T-PRF) to the donor site after free gingival graft harvesting significantly increased tissue thickness (measured by the USG) at 14 days when compared to the controls. Similar to our findings, researchers observed that tissue thickness gradually decreased from day two to day 14 in T-PRF applied sites.<sup>33</sup> Additionally, another study evaluating the effects of T-PRF on human palatal mucosal wound healing emphasized that T-PRF might serve as a scaffold for epithelial and connective tissue cells during wound healing by showing histoconductive features, thus restoring soft tissue thickness at the donor site.<sup>42</sup> Thus, in our study, the significant increase in tissue thickness during the 90-day healing period may stem from the histoconductive properties of PRF.

Approximately 7-10 days following tissue collection, selected fibroblasts differentiate into myofibroblasts, contracting wounds during palatal wound healing.<sup>12</sup> In an *in-vivo* study investigating the effects of leukocyte- and platelet-rich fibrin (L-PRF) membrane on human gingival fibroblasts, Bi, et al.<sup>43</sup> (2020) determined that L-PRF treatment downregulated the fibrosis-related gene expressions while upregulating genes involved in the production of early wound matrix and supporting angiogenesis. Thus, the authors hypothesized that myofibroblast differentiation at the granulation tissue formation stage in the gingival wound healing process could be delayed by factors released from L-PRF, thus possibly promoting scarless gingival wound healing. These findings may explain why tissue thickness on the 14th day was significantly higher in PRF-treated sites than in controls in our study. Also, the comparison between baseline USG measurements with those 90 days after surgery showed an average increase in palatal tissue thickness of 0.4 mm in test sites, whereas control sites showed a loss of 0.2 mm.

Fibroblasts contribute to angiogenesis and capillary regression by secreting growth factors such as VEGF, FGF, and TGF- $\beta$ . These factors play key roles in

regulating the behavior of endothelial and other cells involved in blood vessel formation and regression. Overall, the coordination of these processes is critical for effective wound healing, tissue repair, and maintenance of proper tissue function.<sup>44,45</sup> It has been shown that L-PRF stimulates angiogenesis-related gene expression in human gingival fibroblasts. Furthermore, gingival fibroblasts treated with L-PRF, unlike untreated fibroblasts, have been reported to promote angiogenesis by endothelial cells.<sup>43</sup> Evidence supports the positive effects of platelet derivatives on tissue healing and angiogenesis in preclinical animal studies. Application of platelet-rich plasma (PRP) gel in abdominal wounds has been shown to promote neovascularization and increase blood perfusion assessed by laser-Doppler analysis compared to controls.<sup>46</sup> Roy, et al.<sup>47</sup> (2011) indicated that the PRF matrix stimulates endothelial cell proliferation and wound healing by enhancing angiogenesis in chronic wounds. A few clinical studies investigated the effects of PRF on tissue vascularization in the postoperative period using different methods. Earlier vessel formations established themselves in PRF-treated sites when compared to CTG in histological sections obtained from healing tissue after root coverage treatment.<sup>48</sup> Increased vascularity throughout 14 days of the second healing period after free gingival graft harvesting has been determined by USG measurements after T-PRF placement to the palatal donor area.<sup>33</sup>

In wounded areas, the expansion of recruited collateral bridges and increase in vessel diameters increased blood flow, contributing to healing the injured tissue.<sup>49</sup> Recently, ultrasonographic methods to evaluate blood flow in soft tissues of the oral cavity or revascularization during wound healing after mucogingival surgeries become popular among clinicians.<sup>31,33,50,51</sup> Tavelli, et al.<sup>31</sup> (2021) and co-workers stated that power Doppler USG is an accurate and objective method to evaluate blood flow in both the recipient and donor areas after soft tissue augmentation and to estimate possible wound healing outcomes. This study evaluated the tissue perfusion of palatal donor sites treated or untreated with PRF following sCTG harvesting at initial and late healing phases. Mean blood flow significantly increased for 14 days after surgery in both groups, reaching its highest level on day 14, especially in PRF-treated sites. However, 90 days after surgery, mean PI values were



still higher than the baseline in both groups. Molnar, et al.<sup>52</sup> (2019) investigated blood flow alterations of the palatal region in a postoperative 30-day healing period by Laser Speckle Contrast Imaging following sCTG harvesting with a single incision. The researchers observed low perfusion values in dehiscence areas during the first week of wound healing and found significant correlations between healing scores and the slope of the reperfusion curve in the first three postoperative days. This study found a significant inverse correlation between vascularization and early healing index values in PRF-treated areas on postoperative days three and seven and on days 3 and 14 in controls. Factors influencing soft tissue wound healing include blood supply, tissue perfusion, oxygenation, and nutrition. High capillary growth, which is important for optimum wound healing, supplies micronutrients, immune cells, and oxygen to healing tissues. Especially, it is believed that oral mucosal wounds heal with an angiogenic mechanism consisting of more mature vessels providing better oxygenation.<sup>44</sup> Tissue vascularization involves the coordinated actions of various signalling molecules, growth factors, and cells, including endothelial cells, pericytes, and fibroblasts. It has been highlighted that the release of angiogenic factors such as growth factors in platelet-derived fraction preparations could benefit tissue regeneration and wound healing.<sup>53</sup> In an experimental study, i-PRF application to oral mucosal wounds healed wound by increasing the release of VEGF, EGF, TGF- $\beta$ , PDGF, and FGF for 14 days.<sup>54</sup> Also, PRP application to oral wounds created on the hard palate in rats resulted in significantly higher angiogenesis and collagenization than in groups treated with hyperbaric oxygen or ozone and controls.<sup>55</sup> Lindeboom, et al.<sup>56</sup> (2007) evaluated the effects of PRP on microvascular capillary density in oral mucosal wound healing and reported that capillary density significantly increased in the first week in the PRP group than in controls and reached its maximum level on day seven. The authors also emphasized that the increase in capillary density significantly accelerated mucosal wound healing in the PRP group than in controls during the first 10 postoperative days. Similarly, the application of A-PRF to extraction sockets in beagle dogs favorably affected the regeneration of gingival tissues by accelerating angiogenesis, measured by laser Doppler flowmetry in the early stage of wound healing.<sup>57</sup> Considering these findings,

in this study, increased blood flow in PRF-applied sites may have improved wound healing by enhancing tissue oxygenation and growth factors release.

## Conclusion

This is the first study evaluating the effects of PRF application after sCTG harvesting on the tissue thickness and blood flow of palatal wounds in the early healing and late healing periods using the USG method. Results showed that PRF application to the donor area after sCTG harvesting provided better healing scores with increased vascularization in the early healing period and enhanced palatal tissue thickness for up to 90 days. However, histological studies are needed to fully elucidate the effects of increased tissue perfusion after PRF application on the new tissue quality formed in the donor region.

## Conflict of interest

The authors report no conflict of interest related to this study.

## Data availability statement

All data generated and analyzed during the current study are included in this article

## Authors' contributions

**Torumtay Cin, Gizem:** Investigation (Equal); Methodology (Equal); Project administration (Equal); Writing – original draft (Equal). **Lektemür Alpan, Aysan:** Investigation (Equal) Writing – review & editing (Equal). **Açıköz, Gözde:** Investigation (Equal); Visualization (Equal); Writing – original draft (Equal). **Özlü Uçan, Gülfem:** Visualization (Equal).

## References

- 1- Chambrone L, Botelho J, Machado V, Mascarenhas P, Mendes JJ, Avila-Ortiz G. Does the subepithelial connective tissue graft in conjunction with a coronally advanced flap remain as the gold standard therapy for the treatment of single gingival recession defects? A systematic review and network meta-analysis. *J Periodontol.* 2022;93(9):1336-52. doi: 10.1002/JPER.22-0167
- 2- Thoma DS, Buranawat B, Hammerle CH, Held U, Jung RE. Efficacy of soft tissue augmentation around dental implants and in partially edentulous areas: a systematic review. *J Clin Periodontol.* 2014;41 Suppl 15:S77-91. doi: 10.1111/jcpe.12220

- 3- Tavelli L, Barootchi S, Avila-Ortiz G, Urban IA, Giannobile WV, Wang HL. Peri-implant soft tissue phenotype modification and its impact on peri-implant health: a systematic review and network meta-analysis. *J Periodontol.* 2021;92(1):21-44. doi: 10.1002/JPER.19-0716
- 4- Zucchelli G, Felice P, Mazzotti C, Marzadori M, Mounssif I, Monaco C, et al. 5-year outcomes after coverage of soft tissue dehiscence around single implants: a prospective cohort study. *Eur J Oral Implantol.* 2018;11(2):215-24.
- 5- Kumar A, Sood V, Masamatti SS, Triveni MG, Mehta DS, Khatri M, et al. Modified single incision technique to harvest subepithelial connective tissue graft. *J Indian Soc Periodontol.* 2013;17(5):676-80. doi: 10.4103/0972-124X.119294
- 6- Hürzeler MB, Weng D. A single-incision technique to harvest subepithelial connective tissue grafts from the palate. *Int J Periodontics Restorative Dent.* 1999;19(3):279-87.
- 7- Fickl S, Fischer KR, Jockel-Schneider Y, Stappert CF, Schlagenhauf U, Kepschull M. Early wound healing and patient morbidity after single-incision vs. trap-door graft harvesting from the palate--a clinical study. *Clin Oral Investig.* 2014;18(9):2213-9. doi: 10.1007/s00784-014-1204-7
- 8- Karthikeyan BV, Khanna D, Chowdhary KY, Prabhuji ML. The versatile subepithelial connective tissue graft: a literature update. *Gen Dent.* 2016;64(6):e28-e33.
- 9- Del Pizzo M, Modica F, Bethaz N, Priotto P, Romagnoli R. The connective tissue graft: a comparative clinical evaluation of wound healing at the palatal donor site. a preliminary study. *J Clin Periodontol.* 2002;29(9):848-54. doi: 10.1034/j.1600-051x.2002.290910.x
- 10- Tavelli L, Barootchi S, Ravidia A, Oh TJ, Wang HL. What Is the safety zone for palatal soft tissue graft harvesting based on the locations of the greater palatine artery and foramen? A systematic review. *J Oral Maxillofac Surg.* 2019;77(2):271 e1- e9. doi: 10.1016/j.joms.2018.10.002
- 11- Soileau KM, Brannon RB. A histologic evaluation of various stages of palatal healing following subepithelial connective tissue grafting procedures: a comparison of eight cases. *J Periodontol.* 2006;77(7):1267-73. doi: 10.1902/jop.2006.050129
- 12- Tavelli L, Barootchi S, Stefanini M, Zucchelli G, Giannobile WV, Wang HL. Wound healing dynamics, morbidity, and complications of palatal soft-tissue harvesting. *Periodontol 2000.* 2023;92(1):90-119. doi: 10.1111/prd.12466
- 13- Stavropoulou C, Atout RN, Brownlee M, Schroth RJ, Kelekis-Cholakias A. A randomized clinical trial of cyanoacrylate tissue adhesives in donor site of connective tissue grafts. *J Periodontol.* 2019;90(6):608-15. doi: 10.1002/JPER.18-0475
- 14- Dias SB, Fonseca MV, Santos NC, Mathias IF, Martinho FC, Santamaria M Jr, et al. Effect of GaAIs low-level laser therapy on the healing of human palate mucosa after connective tissue graft harvesting: randomized clinical trial. *Lasers Med Sci.* 2015;30(6):1695-702. doi: 10.1007/s10103-014-1685-2
- 15- Lektemur Alpan A, Torumtay Cin G. PRF improves wound healing and postoperative discomfort after harvesting subepithelial connective tissue graft from palate: a randomized controlled trial. *Clin Oral Investig.* 2020;24(1):425-36. doi: 10.1007/s00784-019-02934-9
- 16- Fan Y, Perez K, Dym H. Clinical uses of platelet-rich fibrin in oral and maxillofacial surgery. *Dent Clin North Am.* 2020;64(2):291-303. doi: 10.1016/j.cden.2019.12.012
- 17- Marx RE. Platelet-rich plasma (PRP): what is PRP and what is not PRP? *Implant Dent.* 2001;10(4):225-8. doi: 10.1097/00008505-200110000-00002
- 18- Varela HA, Souza JC, Nascimento RM, Araujo RF Jr, Vasconcelos RC, Cavalcante RS, et al. Injectable platelet rich fibrin: cell content, morphological, and protein characterization. *Clin Oral Investig.* 2019;23(3):1309-18. doi: 10.1007/s00784-018-2555-2
- 19- Sohn DS. Lecture titled with sinus and ridge augmentation with CGF and AFG. In: Symposium on CGF and AFG. Tokyo: June 6; 2010.
- 20- Tunali M, Özdemir H, Küçükodacı Z, Akman S, Yaprak E, Toker H, et al. A novel platelet concentrate: titanium-prepared platelet-rich fibrin. *Biomed Res Int.* 2014;2014:209548. doi: 10.1155/2014/209548
- 21- Choukroun J. Advanced PRF, & i-PRF: platelet concentrates or blood concentrates. *J Periodontol Med Clin Pract.* 2014;1(1):3.
- 22- Mourão CF, Valiense H, Melo ER, Mourão NB, Maia MD. Obtention of injectable platelets rich-fibrin (i-PRF) and its polymerization with bone graft. *Rev Col Bras Cir.* 2015;42:421-3. doi: 10.1590/0100-69912015006013
- 23- Choukroun J, Diss A, Simonpieri A, Girard MO, Schoeffler C, Dohan SL, et al. Platelet-rich fibrin (PRF): a second-generation platelet concentrate. Part IV: clinical effects on tissue healing. *Oral Surg Oral Med Oral Pathol Oral Radiol Endod.* 2006;101(3):e56-60. doi: 10.1016/j.tripleo.2005.07.011
- 24- Miron RJ, Zucchelli G, Pikos MA, Salama M, Lee S, Guillemette V, et al. Use of platelet-rich fibrin in regenerative dentistry: a systematic review. *Clin Oral Investig.* 2017;21(6):1913-27. doi: 10.1007/s00784-017-2133-z
- 25- Tikku AP, Kumar S, Loomba K, Chandra A, Verma P, Aggarwal R. Use of ultrasound, color Doppler imaging and radiography to monitor periapical healing after endodontic surgery. *J Oral Sci.* 2010;52(3):411-6. doi: 10.2334/josnusd.52.411
- 26- Figueredo CA, Catunda RQ, Gibson MP, Major PW, Almeida FT. Use of ultrasound imaging for assessment of the periodontium: a systematic review. *J Periodontol Res.* 2023;10.1111/jre.13194
- 27- Nguyen KC, Le LH, Kaipatur NR, Major PW. Imaging the cemento-enamel junction using a 20-mhz ultrasonic transducer. *Ultrasound Med Biol.* 2016;42(1):333-8. doi: 10.1016/j.ultrasmedbio.2015.09.012
- 28- Nguyen KT, Le LH, Kaipatur NR, Zheng R, Lou EH, Major PW. High-Resolution ultrasonic imaging of dento-periodontal tissues using a multi-element phased array system. *Ann Biomed Eng.* 2016;44(10):2874-86. doi: 10.1007/s10439-016-1634-2
- 29- Moore CA, Law JK, Retout M, Pham CT, Chang KC, Chen C, et al. High-resolution ultrasonography of gingival biomarkers for periodontal diagnosis in healthy and diseased subjects. *Dentomaxillofac Radiol.* 2022;51(6):20220044. doi: 10.1259/dmfr.20220044
- 30- Majzoub J, Tavelli L, Barootchi S, Salami A, Inglehart MR, Kripfgans OD, et al. Agreement in measurements of ultrasonography-derived periodontal diagnostic parameters among multiple raters: a diagnostic accuracy study. *Oral Surg Oral Med Oral Pathol Oral Radiol.* 2022;134(3):375-85. doi: 10.1016/j.oooo.2022.03.010
- 31- Tavelli L, Barootchi S, Majzoub J, Chan HL, Giannobile WV, Wang HL, et al. Ultrasonographic tissue perfusion analysis at implant and palatal donor sites following soft tissue augmentation: A clinical pilot study. *J Clin Periodontol.* 2021;48(4):602-14. doi: 10.1111/jcpe.13424
- 32- Shahidi S, Shakibafard A, Zamiri B, Mokhtare MR, Houshyar M, Mahdian S. The Feasibility of ultrasonography in defining the size of jaw osseous lesions. *J Dent (Shiraz).* 2015;16(4):335-40.
- 33- Koca-Unsal RB, Unsal G, Kasnak G, Firatli Y, Ozcan I, Orhan K, et al. Ultrasonographic evaluation of the titanium-prepared platelet-rich fibrin effect in free gingival graft procedures. *J Periodontol.* 2022;93(2):187-94. doi: 10.1002/JPER.21-0076
- 34- Zucchelli G, De Sanctis M. Treatment of multiple recession-type defects in patients with esthetic demands. *J Periodontol.* 2000;71(9):1506-14. doi: 10.1902/jop.2000.71.9.1506
- 35- Donn BJ, Jr. The free connective tissue autograft: a clinical and histologic wound healing study in humans. *J Periodontol.* 1978;49(5):253-60. doi: 10.1902/jop.1978.49.5.253
- 36- Polimeni G, Xiropaidis AV, Wikesjo UM. Biology and principles of periodontal wound healing/regeneration. *Periodontol 2000.* 2006;41:30-47. doi: 10.1111/j.1600-0757.2006.00157.x

- 37- Dohan Ehrenfest DM, Bielecki T, Jimbo R, Barbe G, Del Corso M, Inchingolo F, et al. Do the fibrin architecture and leukocyte content influence the growth factor release of platelet concentrates? An evidence-based answer comparing a pure platelet-rich plasma (P-PRP) gel and a leukocyte- and platelet-rich fibrin (L-PRF). *Curr Pharm Biotechnol.* 2012;13(7):1145-52. doi: 10.2174/138920112800624382
- 38- Kiziltoprak M, Uslu MO. Comparison of the effects of injectable platelet-rich fibrin and autologous fibrin glue applications on palatal wound healing: a randomized controlled clinical trial. *Clin Oral Investig.* 2020;24(12):4549-61. doi: 10.1007/s00784-020-03320-6
- 39- Ozcan M, Ucak O, Alkaya B, Keceli S, Seydaoglu G, Haytac MC. Effects of platelet-rich fibrin on palatal wound healing after free gingival graft harvesting: a comparative randomized controlled clinical trial. *Int J Periodontics Restorative Dent.* 2017;37(5):e270-e8. doi: 10.11607/prd.3226
- 40- Sousa F, Machado V, Botelho J, Proenca L, Mendes JJ, Alves R. Effect of A-PRF application on palatal wound healing after free gingival graft harvesting: a prospective randomized study. *Eur J Dent.* 2020;14(1):63-9. doi: 10.1055/s-0040-1702259
- 41- Yen CA, Griffin TJ, Cheung WS, Chen J. Effects of platelet concentrate on palatal wound healing after connective tissue graft harvesting. *J Periodontol.* 2007;78(4):601-10. doi: 10.1902/jop.2007.060275
- 42- Ustaoglu G, Ercan E, Tunalı M. The role of titanium-prepared platelet-rich fibrin in palatal mucosal wound healing and histoconduction. *Acta Odontol Scand.* 2016;74(7):558-64. doi: 10.1080/00016357.2016.1219045
- 43- Bi J, Intriago MF, Koivisto L, Jiang G, Hakkinen L, Larjava H. Leucocyte- and platelet-rich fibrin regulates expression of genes related to early wound healing in human gingival fibroblasts. *J Clin Periodontol.* 2020;47(7):851-62. doi: 10.1111/jcpe.13293
- 44- DiPietro LA. Angiogenesis and wound repair: when enough is enough. *J Leukoc Biol.* 2016;100(5):979-84. doi: 10.1189/jlb.4MR0316-102R
- 45- Ngeow WC, Tan CC, Goh YC, Deliberador TM, Cheah CW. A narrative review on means to promote oxygenation and angiogenesis in oral wound healing. *bioengineering (Basel).* 2022;9(11):636. doi: 10.3390/bioengineering9110636
- 46- Zhou B, Ren J, Ding C, Wu Y, Hu D, Gu G, et al. Rapidly in situ forming platelet-rich plasma gel enhances angiogenic responses and augments early wound healing after open abdomen. *Gastroenterol Res Pract.* 2013;2013:926764. doi: 10.1155/2013/926764
- 47- Roy S, Driggs J, Elgharably H, Biswas S, Findley M, Khanna S, et al. Platelet-rich fibrin matrix improves wound angiogenesis via inducing endothelial cell proliferation. *Wound Repair Regen.* 2011;19(6):753-66. doi: 10.1111/j.1524-475X.2011.00740.x
- 48- Eren G, Kantarci A, Sculean A, Atilla G. Vascularization after treatment of gingival recession defects with platelet-rich fibrin or connective tissue graft. *Clin Oral Investig.* 2016;20(8):2045-53. doi: 10.1007/s00784-015-1697-8
- 49- Yousefi S, Qin J, Dziennis S, Wang RK. Assessment of microcirculation dynamics during cutaneous wound healing phases in vivo using optical microangiography. *J Biomed Opt.* 2014;19(7):76015. doi: 10.1117/1.JBO.19.7.076015
- 50- Barootchi S, Chan HL, Namazi SS, Wang HL, Kripfgans OD. Ultrasonographic characterization of lingual structures pertinent to oral, periodontal, and implant surgery. *Clin Oral Implants Res.* 2020;31(4):352-9. doi: 10.1111/clr.13573
- 51- Tavelli L, Kripfgans OD, Chan HL, Vera Rodriguez M, Sabri H, Mancini L, et al. Doppler ultrasonographic evaluation of tissue revascularization following connective tissue graft at implant sites. *J Clin Periodontol.* Forthcoming 2023. doi: 10.1111/jcpe.13889
- 52- Molnar B, Molnar E, Fazekas R, Ganti B, Mikecs B, Vag J. assessment of palatal mucosal wound healing following connective-tissue harvesting by laser speckle contrast imaging: an observational case series study. *Int J Periodontics Restorative Dent.* 2019;39(2):e64-e70. doi: 10.11607/prd.3878
- 53- Martinez CE, Smith PC, Palma Alvarado VA. The influence of platelet-derived products on angiogenesis and tissue repair: a concise update. *Front Physiol.* 2015;6:290. doi: 10.3389/fphys.2015.00290
- 54- Lektemur Alpan A, Torumtay Cin G, Kizildag A, Zavrak N, Ozmen O, Arslan S, et al. Evaluation of the effect of injectable platelet-rich fibrin (i-PRF) in wound healing and growth factor release in rats: a split-mouth study. *Growth Factors.* 2024;42(1):36-48. doi: 10.1080/08977194.2023.2289375
- 55- Uslu K, Tansuker HD, Tabaru A, Egeren SE, Kulahci KK, Bulut P, et al. Investigation of the effects of thrombocyte-rich plasma, systemic ozone and hyperbaric oxygen treatment on intraoral wound healing in rats: experimental study. *Eur Arch Otorhinolaryngol.* 2020;277(6):1771-7. doi: 10.1007/s00405-020-05872-5
- 56- Lindeboom JA, Mathura KR, Aartman IH, Kroon FH, Milstein DM, Ince C. Influence of the application of platelet-enriched plasma in oral mucosal wound healing. *Clin Oral Implants Res.* 2007;18(1):133-9. doi: 10.1111/j.1600-0501.2006.01288.x
- 57- Liu YH, To M, Okudera T, Wada-Takahashi S, Takahashi SS, Su CY, et al. Advanced platelet-rich fibrin (A-PRF) has an impact on the initial healing of gingival regeneration after tooth extraction. *J Oral Biosci.* 2022;64(1):141-7. doi: 10.1016/j.job.2021.11.001