

Urolithiasis and pregnancy

Authors

Fernando Korkes^{1,2,3}

Eduardo Costa Rauhen²

Ita Pfeferman Heilberg⁴

¹ School of Medicine of the ABC (FMABC).

² Albert Einstein Hospital.

³ São Luiz Hospital.

⁴ Federal University of São Paulo (UNIFESP).

ABSTRACT

The diagnosis of urolithiasis during pregnancy is common, even though no additional measures are required in asymptomatic cases. Renal colic or complications of urinary lithiasis occur more frequently during the last months of pregnancy, and there are several particularities for the diagnosis and treatment of this subset of women. The present manuscript aim to review the current knowledge concerning this subject and present authors personal experience.

Keywords: lithotripsy; nephrolithiasis; pregnancy complications; pregnancy trimesters; uretero-lithiasis; urolithiasis.

INTRODUCTION

The prevalence of urolithiasis is high, affecting up to 15% of the world population.^{1,2} Because of the high frequency of this disease and a higher likelihood of pregnant women developing kidney stones,^{3,4} the diagnosis of urolithiasis during pregnancy is very frequent.⁴ The simple diagnosis of asymptomatic nephrolithiasis in pregnant women does not require specific measures in most cases.^{4,5} According to some authors,^{6,7} renal colic and nephrolithiasis complications during pregnancy are less common, happening in 1 of 224 to 2,000 pregnancies, and the symptoms are more frequent in the later months of pregnancy.⁸ When there are symptoms related to urolithiasis, there are some particularities related to clinical manifestations, diagnosis and treatment of

this condition in pregnant women. This paper aims to review this issue in the light of current knowledge.

URINARY TRACT METABOLIC AND PHYSIOLOGICAL CHANGES DURING PREGNANCY

During pregnancy there are physiological and anatomical changes to the urinary tract. The kidneys are cranially displaced by the fetus, besides increasing by about one centimeter in size, due to the increase in kidney vascularization and interstitial space during pregnancy.⁹ Upper urinary tract dilatation is a remarkable change in pregnancy and happens at around the seventh week of pregnancy in about 90% of pregnant women, persisting for up to six weeks postpartum. This “physiological” hydronephrosis stems from hormonal and mechanical factors and is more pronounced on the right side. Hydronephrosis increases urinary stasis, acting as a major risk factor for nephrolithiasis as well as urinary infections.⁹

Cardiac output in pregnancy is also increased, causing elevation of glomerular filtration rate by 40% to 65%.⁹ This results in reduction of serum creatinine, which can reach 0.5 mg/dL, as well as changes in the renal excretion of electrolytes. Regarding lithogenic urinary parameters, the changes occur in differing directions. On the one hand, there is hypercalciuria due to increased glomerular filtration of calcium associated with the intestinal

Submitted on: 07/29/2013.

Approved on: 07/07/2014.

Correspondence to:

Fernando Korkes.
Medical School of the ABC -
Urology Course.
Rua Pirapora, nº 167, Ibirapuera. São
Paulo, SP, Brasil. CEP: 04008-060.
E-mail: fkorkes@terra.com.br
Tel: (11) 3884-2233.

DOI: 10.5935/0101-2800.20140055

hyper-absorption of calcium by the placental production of 1,25-(OH)₂ vitamin D.³ Any calcium supplementation during pregnancy may contribute to increase further urinary excretion of calcium. In contrast, there is significant increase in urinary pH, renal excretion of citrate, magnesium, uromodulins, nephrocalcin and glycoproteins during pregnancy - inhibitory factors of urinary crystallization and formation of stones.^{3,9,10}

Such changes in opposite directions lead to a different situation from that found in non-pregnant patients. Although many factors inhibitory to the urinary-crystallization are increased, hypercalciuria in pregnant women is associated with increased urinary pH, favoring urinary supersaturation by brushite and calcium phosphate stone formation, especially carbapatite.³ In a study which assessed 244 stones extracted from pregnant women, the authors reported a significantly higher proportion of calcium phosphate stones when compared with stones from non-pregnant women (65.6% *vs.* 31.4%, *p* < 0.0001).³

RENAL COLIC DURING PREGNANCY

Having symptomatic kidney stones during pregnancy raises additional concerns because, besides all the suffering and risks it can bring to pregnant women, it is also associated with a further significant increase in the risk of premature membrane rupture⁸ and increased risk of preterm labor in 1.4 to 2.4 times.^{8,10,11} Renal colic typically occurs when a stone migrates and causes obstruction somewhere in the urinary tract. The pain is not directly caused by the stones themselves, but it arises from distention of the urinary tract and kidney capsule.¹ The most commonly place associated with the clinical manifestation of the obstruction is the ureter. In a study involving individuals seeking emergency treatment for renal colic, they reported that the most frequent topography of urinary obstruction by stones is the ureterovesical junction (60.6%), followed by the proximal ureter above the junction with the iliac vessels (23.4%); the pieloureteral junction (10.6%); distal ureter (4.3%) and crossing with the iliac vessels (1.1%).¹² The symptoms herein may vary

from a framework of low back pain, radiating to the flank, lower abdomen or genital region. There may be hematuria, urinary and other symptoms such as pollakiuria and dysuria, particularly when the stone is found in the distal portion of the ureter. Nausea and vomiting may occur due to intense pain.^{1,13} In a cohort of pregnant women with symptomatic urinary stones, the authors observed that the most frequent symptoms were back pain (71%), and hematuria (57.1%).⁷ Given this context, one must start with supportive measures, including antiemetics, analgesics, and minimum hydration when necessary. We have to bear in mind that the drugs to be used should be selected taking into account their effects, side effects and safety of use during pregnancy, as per shown on Table 1.

DIAGNOSTIC TESTS AND DIFFERENTIAL DIAGNOSES

Upon clinical suspicion of renal colic or abdominal pain in pregnant women, one must perform additional tests to confirm the diagnosis. In addition to other differential diagnoses of acute abdomen and obstetric conditions, one should take into account the possibility of other urological disorders. Faced with renal colic during pregnancy, you should investigate the presence of ureterolithiasis, physiological hydronephrosis of pregnancy and/or pyelonephritis, which may occur in isolation or as a complication of the first two conditions.¹⁴

Initially, one should obtain urine sample for urinalysis and urine culture. Usually, in the context of renal colic, one can see microscopic hematuria, observed in 92.9% of the cases.¹⁵ In contrast, in normal pregnancies there usually is no hematuria,¹⁴ hypercalciuria was the only urinary change reported in this group of patients.¹⁴

Additional tests may bring relevant information, especially serum creatinine, to estimate kidney function and CBC to assess possible evidence of systemic infection.

Although non-contrast abdomen CT scan is considered the gold standard in evaluating an individual with renal colic, this image scan should be avoided during pregnancy, especially in the first quarter - because of teratogenesis risks associated

TABLE 1 MEDICATION AND THEIR SAFETY PROFILES ACCORDING TO THE U.S. FOOD AND DRUG ADMINISTRATION (FDA)³⁹

Medication	Category (FDA)
Analgesics	
paracetamol	B
dypirone	N - lower risk and frequently utilized
Anti-vomiting	
metoclopramide	B
diphenhydramine	B
ondansetron	B
Antispasmodics	
hyoscine	C
Non-steroidal anti-inflammatory	
	Not-recommended in pregnant women
diclofenac sodium	C (if used on the 3 rd quarter it goes to D)
ketoprofen	C
mefenamic acid	C
ketorolac	C
ibuprofen	C
tenoxicam	Not classified
Corticosteroids	
dexametasone	C
prednisone	C
prednisolone	C
Opioids	
oxycontin	B
tramadol, codeine, morphine	C
Expulsion medical therapy	
	Not recommended in pregnant women
tamsulosin	B
nifedipine	C

A: Controlled studies did not show risk; B: Improbable risk; C: Risk cannot be ruled out; D: Positive evidence of risk (maternal benefit may overcome the fetal risk when in a death risk condition); X: Contraindicated in pregnancy (evidence of fetal damage); N: Drug not classified by the FDA.

with radiation exposure. Thus, total abdominal ultrasound examination should be the initial image test for evaluating a pregnant woman with abdominal pain and/or suspicion of renal colic. However, although it has a high specificity of 90% for the diagnosis of ureteral lithiasis, the sensitivity of this method is quite low (11%-24%).¹³ Therefore, in most cases the ultrasound will not lead to a conclusive diagnosis, but it can be useful to demonstrate indirect signs of obstruction,

notably ureterohydronephrosis. Physiological hydronephrosis is a confounding factor in 90% of normal pregnancies,¹⁶ which in most cases invalidates the use of this data as a parameter to be considered. However, physiological hydronephrosis is more common and more pronounced on the right side because of uterine dextroversion.¹⁷ Additional information which can and should be seen upon the ultrasound includes the degree of hydronephrosis, absence of ureteral stream or increased renal artery resistivity index¹⁷ and finding other kidney stones which, even if not associated with an acute pain episode, show a greater likelihood that other stones have moved into the ureter.

MRI is mentioned in the literature as an alternative for the diagnosis of changes in the urinary tract during pregnancy.¹⁸ However, the test sensitivity to detect stones is also low,¹⁹ although it may show indirect signs of stones, such as ureteritis, periureteritis, perirenal edema or overflow^{16,18} (Figure 1).

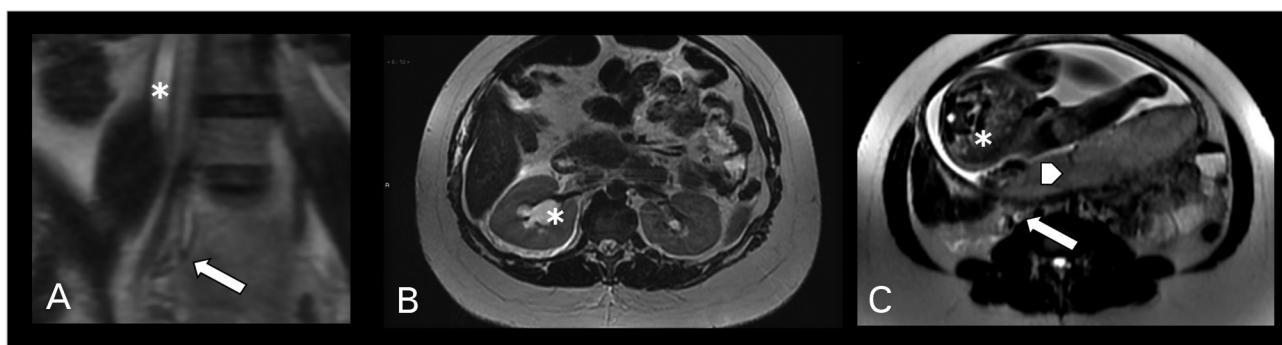
Another alternative for women in the second and third quarters is CT scan with lower radiation doses. Examinations performed with less radiation produce images with worse resolution, but in suspicious cases, these images may aid in the diagnosis of women in the last quarters of pregnancies.^{20,21}

CLINICAL TREATMENT

After analgesia and clinical compensation for the pregnant women with suspected renal colic, one should establish the therapeutic strategy. In most cases, additional tests are not enough for an accurate diagnosis, but it plays a fundamental role in ruling out other differential diagnoses. The most frequent clinical manifestation is that of a pregnant woman with colic and backache, whose ultrasound shows ureterohydronephrosis and urinalysis shows hematuria. In this situation, one should rule out situations that would determine immediate action, namely:

1. UTI associated with obstruction by stones.
2. Intractable pain despite clinical care, and intense analgesia.
3. Acute kidney failure, usually associated with bilateral obstruction or in women with a single kidney.

Figure 1. MRI in a third quarter pregnant woman with right-side ureterolithiasis: A: Axial image in T2 FSE showing ureteral dilatation (*) and one stone in the distal ureter (arrow); B: T2 axial image showing right-side hydronephrosis to the right side (*); C: T2 axial image showing a ureteral stone (arrow), part of a fetus in the third quarter (*) and posterior placenta (arrow head).



4. Loads of uterine contractions occurring prematurely.

If none of these conditions are present, these pregnant women should receive drug treatment as the first choice. This must be accomplished primarily through the use of analgesics (paracetamol, dipyrone), antispasmodics, opioids and/or corticosteroids. Among the medications commonly used to increase the rate of ureteral stones clearance, we stress alpha-blockers and calcium channel blockers. Alpha-blockers are considered standard of care in the general population; however, there are no studies today proving the safety of these drugs during pregnancy, making the use of this class of medications not recommended for pregnant women. In animal studies, nifedipine was associated with abortions and teratogenesis; also being inadvisable for pregnant women (category C medication according to the US-FDA).

In general, there is a higher rate of ureteral stone clearances in pregnant women; it is estimated that 80% of the time the stones are cleared with clinical treatment.⁴ However, in pregnant patients with symptomatic urolithiasis there is a significant risk of urinary tract infection with an incidence of 52.4%.⁷ Thus, antibiotic prophylaxis is recommended.⁷

SURGICAL TREATMENT

When ureteral stones are associated with complications such as evidence of concomitant urinary tract infection, acute kidney failure or intractable/recurrent pain, surgical treatment is mandated.²² Among the possibilities to treat urolithiasis, it should be noted that extracorporeal

lithotripsy through shock waves is contraindicated during pregnancy because of the risk of miscarriage and detached placenta.²³ Alternative treatments, include:

1. Kidney unit clearance through the implantation of a double J-type ureteral catheter.
2. Percutaneous nephrostomy.²⁴
3. Ureterscopy and definitive stone treatment.
4. Open/laparoscopic surgery - rarely used - situations of exception.
5. Percutaneous renal surgery - rarely used, situations of exception.²⁵

Traditionally, the procedures performed in this context aim to simply clear the kidney, either by percutaneous nephrostomy or double J-catheter.^{26,27} Although these are quite effective alternatives to resolve the urgency, they are still inconvenient because an external probe remains dwelling in the case of nephrostomy, or not performing the definitive treatment, in addition to keeping the catheter in the urinary tract. Moreover, women undergoing nephrostomy for urinary obstruction are usually submitted to frequent changes caused by the obstruction.^{24,28} The double-J catheter must be changed every eight weeks due to the high risk of catheter encrustment in pregnant women.

With the development of more sensitive and precise equipment in the last decade, it became possible to perform safe ureterscopy and definitive treatment for the stones even during pregnancy. According to a meta-analysis published in 2008, although the experience reported in the medical literature is relatively small - 108

cases - ureteroscopic treatment of stones during pregnancy is safe and efficient.²² Additionally, with technical refinement in most cases, it has become possible to perform these endoscopic urological procedures without exposure to radiation using a lead apron,²⁹ or totally avoiding radiation with the use of the “follow the wire technique”, using two guide wires during ureteroscopy, and introducing the ureteroscope following the guidewire.³⁰ In a recent meta-analysis involving 116 procedures the authors suggested an 88% success rate and only two complications.³¹

In the author’s experience (FK, unpublished data), in 29 pregnant patients treated endoscopically in the last three years (6-39 weeks gestational age, mean \pm SD: 25.0 \pm 8.1 weeks), 27 cases were successfully treated without the need for fluoroscopy, using the “follow the wire” technique. In one of the cases, fluoroscopy was used minimally to confirm the position of the guide wire and the double-J catheter due to a tortuous ureter, and in one case it was necessary to perform percutaneous renal access due to impossibility of access, as well as passing the guide wire in a 1.3 proximal ureteral stone associated with pyelonephritis. With the goal of avoiding the use of fluoroscopy, it is also possible to employ intraoperative ultrasound as a means of guiding the ureteroscopy.³²

Both the laser and the ballistic lithotripters have been proven safe as a source of energy for breaking ureteral stones.^{22,31} The use of postoperative urethral catheter is often recommended for variable periods.³³ It should be further noted that, even in cases of colic by physiological hydronephrosis without the occurrence of concomitant urolithiasis, in which the patient stays with the recurrent pain despite analgesia in left lateral decubitus, placement of ureteral catheter should also be considered.

TECHNICAL ANESTHETIC

During anesthesia for obstetric surgery in pregnant women in ureterolithotripsy, one should consider important aspects for both maternal and fetal safety, taking into account the physiological changes of pregnancy. Teratogenic drugs should be avoided, avoid fetal hypoxia and prevent premature labor,

regardless of the technique used. Despite the lack of randomized, prospective studies, there seems to be similar safety between regional anesthesia (spinal or epidural) *versus* general anesthesia. In both techniques, one should avoid hypotension, prevent tracheal aspiration and move the uterus to the left, ensuring adequate oxygenation, normocarbia and euglycemia. One must also keep adequate post-operative care, including satisfactory analgesia, early ambulation, monitoring fetal heart rate and uterine contractions.³⁴

In the first trimester of pregnancy, the main fetal concerns are abortion and teratogenesis. In the third quarter the main concern is with preterm delivery. Whenever possible, we try to postpone surgery to the second quarter in women with gestational age less than 20 weeks. When surgery is unavoidable, regional anesthesia is the first choice, thus avoiding the use of nitrous oxide. Fetal heart rate monitoring should be performed before and after surgery. In women with ongoing pregnancy over 20 weeks, it is recommended the use of prophylactic tocolytics. Fetal heart rate and uterine activity should also be monitored during surgery.³⁴

OBSTETRIC RISKS

Nephrolithiasis in pregnant women did not prove to be a risk factor for the occurrence malformations in a second study that evaluated 22,843 newborns or fetuses with congenital malformations.³⁵ On the other hand, renal colic and its complications increase the risk of premature delivery,³⁶ which can occur in up to 67% of cases according to a series.³⁷ They also increase the need for performing a C-Section.³⁸ In contrast, surgical procedures during pregnancy also increase pregnancy risks.³⁶ In a series of 46 pregnant women undergoing ureteroscopy, there were two complications with preterm delivery (4.3%). The approach to these patients is challenging from diagnosis to therapy decisions, as well as in obstetric care. It is essential to have a multidisciplinary approach involving obstetric care and eventually tocolytic agents.

In conclusion, urolithiasis and complications occur with relatively high frequency during pregnancy. The recognition of this disease, its

complications and peculiarities during pregnancy is of fundamental importance to the obstetrician, urologist, nephrologist and all professionals involved in the care for pregnant women.

REFERENCES

- Korkes F, Gomes SA, Heilberg IP. Diagnóstico e tratamento de litíase ureteral. *J Bras Nefrol* 2009;31:55-61.
- Heilberg IP, Schor N. Renal stone disease: Causes, evaluation and medical treatment. *Arq Bras Endocrinol Metabol* 2006;50:823-31. DOI: <http://dx.doi.org/10.1590/S0004-27302006000400027>
- Meria P, Hadjadj H, Jungers P, Daudon M. Stone formation and pregnancy: pathophysiological insights gained from morphoconstitutional stone analysis. *J Urology* 2010;183:1412-6. DOI: <http://dx.doi.org/10.1016/j.juro.2009.12.016>
- Charalambous S, Fotas A, Rizk DE. Urolithiasis in pregnancy. *Int Urogynecol J Pelvic Floor Dysfunct* 2009;20:1133-6. DOI: <http://dx.doi.org/10.1007/s00192-009-0920-z>
- McAleer SJ, Loughlin KR. Nephrolithiasis and pregnancy. *Curr Opin Urol* 2004;14:123-7. DOI: <http://dx.doi.org/10.1097/00042307-200403000-00013>
- Srirangam SJ, Hickerton B, Van Cleynenbreugel B. Management of urinary calculi in pregnancy: a review. *J Endourol* 2008;22:867-75. DOI: <http://dx.doi.org/10.1089/end.2008.0086>
- Romero Nava LE, Velázquez Sánchez Mdel P, Kunhardt Rasch JR. Urolithiasis and pregnancy. Presentation of results and management norm at the National Institute of Perinatology. *Ginecol Obstet Mex* 2004;72:515-24. PMID: 15790192
- Lewis DF, Robichaux AG 3rd, Jaekle RK, Marcum NG, Stedman CM. Urolithiasis in pregnancy. Diagnosis, management and pregnancy outcome. *J Reprod Med* 2003;48:28-32.
- Hill CC, Pickinpaugh J. Physiologic changes in pregnancy. *Surg Clin North Am* 2008;88:391-401. DOI: <http://dx.doi.org/10.1016/j.suc.2007.12.005>
- Ross AE, Handa S, Lingeman JE, Matlaga BR. Kidney stones during pregnancy: an investigation into stone composition. *Urol Res* 2008;36:99-102. DOI: <http://dx.doi.org/10.1007/s00240-008-0138-4>
- Swartz MA, Lydon-Rochelle MT, Simon D, Wright JL, Porter MP. Admission for nephrolithiasis in pregnancy and risk of adverse birth outcomes. *Obstet Gynecol* 2007;109:1099-104. PMID: 17470589 DOI: <http://dx.doi.org/10.1097/01.AOG.0000259941.90919.c0>
- Eisner BH, Reese A, Sheth S, Stoller ML. Ureteral stone location at emergency room presentation with colic. *J Urol* 2009;182:165-8. DOI: <http://dx.doi.org/10.1016/j.juro.2009.02.131>
- Teichman JM. Clinical practice. Acute renal colic from ureteral calculus. *N Engl J Med* 2004;350:684-93. PMID: 14960744 DOI: <http://dx.doi.org/10.1056/NEJMc030813>
- Resim S, Ekerbicer HC, Kiran G, Kilinc M. Are changes in urinary parameters during pregnancy clinically significant? *Urol Res* 2006;34:244-8.
- Argyropoulos A, Farmakis A, Doumas K, Lykourinas M. The presence of microscopic hematuria detected by urine dipstick test in the evaluation of patients with renal colic. *Urol Res* 2004;32:294-7. DOI: <http://dx.doi.org/10.1007/s00240-004-0413-y>
- Pais VM Jr, Payton AL, LaGrange CA. Urolithiasis in pregnancy. *Urol Clin North Am* 2007;34:43-52. DOI: <http://dx.doi.org/10.1016/j.ucl.2006.10.011>
- Andreoiu M, MacMahon R. Renal colic in pregnancy: lithiasis or physiological hydronephrosis? *Urology* 2009;74:757-61. PMID: 19660792
- Spencer JA, Chahal R, Kelly A, Taylor K, Eardley I, Lloyd SN. Evaluation of painful hydronephrosis in pregnancy: magnetic resonance urographic patterns in physiological dilatation versus calculous obstruction. *J Urol* 2004;171:256-60. PMID: 14665888
- Connolly SS, Browne LP, Collins CD, Lennon GM. Artificial hydronephrosis to facilitate MR urography during pregnancy. *Ir J Med Sci* 2009;178:83-4. PMID: 19214646 DOI: <http://dx.doi.org/10.1007/s11845-009-0289-5>
- Lazarus E, Mayo-Smith WW, Mainiero MB, Spencer PK. CT in the evaluation of nontraumatic abdominal pain in pregnant women. *Radiology* 2007;244:784-90. PMID: 17709829 DOI: <http://dx.doi.org/10.1148/radiol.2443061634>
- White WM, Zite NB, Gash J, Waters WB, Thompson W, Klein FA. Low-dose computed tomography for the evaluation of flank pain in the pregnant population. *J Endourol* 2007;21:1255-60. DOI: <http://dx.doi.org/10.1089/end.2007.0017>
- Semins MJ, Trock BJ, Matlaga BR. The safety of ureteroscopy during pregnancy: a systematic review and meta-analysis. *J Urol* 2009;181:139-43. PMID: 19012926 DOI: <http://dx.doi.org/10.1016/j.juro.2008.09.029>
- Skolarikos A, Alivizatos G, de la Rosette J. Extracorporeal shock wave lithotripsy 25 years later: complications and their prevention. *Eur Urol* 2006;50:981-90. DOI: <http://dx.doi.org/10.1016/j.eururo.2006.01.045>
- Khoo L, Anson K, Patel U. Success and short-term complication rates of percutaneous nephrostomy during pregnancy. *J Vasc Interv Radiol* 2004;15:1469-73. DOI: <http://dx.doi.org/10.1097/01.RVI.0000140639.57131.6D>
- Tóth C, Tóth G, Varga A, Flaskó T, Salah MA. Percutaneous nephrolithotomy in early pregnancy. *Int Urol Nephrol* 2005;37:1-3. PMID: 16132747 DOI: <http://dx.doi.org/10.1007/s11255-004-6087-0>
- Guichard G, Fromajoux C, Cellarier D, Loock PY, Chabannes E, Bernardini S, et al. Management of renal colic in pregnant women, based on a series of 48 cases. *Prog Urol* 2008;18:29-34. DOI: <http://dx.doi.org/10.1016/j.purol.2007.11.001>
- Evans HJ, Wollin TA. The management of urinary calculi in pregnancy. *Curr Opin Urol* 2001;11:379-84. DOI: <http://dx.doi.org/10.1097/00042307-200107000-00007>
- Kavoussi LR, Albala DM, Basler JW, Apte S, Clayman RV. Percutaneous management of urolithiasis during pregnancy. *J Urol* 1992;148:1069-71. PMID: 1507334
- Cocuzza M, Colombo JR Jr, Lopes RI, Piovesan AC, Borges Mesquita JL, Srougi M. Use of inverted fluoroscope's C-arm during endoscopic treatment of urinary tract obstruction in pregnancy: a practicable solution to cut radiation. *Urology* 2010;75:1505-8. DOI: <http://dx.doi.org/10.1016/j.urology.2009.12.014>
- Tawfik ER. Ureteroscopy during pregnancy using the follow-the-wire technique. *Afr J Urol* 2009;15:245-9. DOI: <http://dx.doi.org/10.1007/s12301-009-0044-1>
- Laing KA, Lam TB, McClinton S, Cohen NP, Traxer O, Somani BK. Outcomes of ureteroscopy for stone disease in pregnancy: results from a systematic review of the literature. *Urol Int* 2012;89:380-6. PMID: 23147596 DOI: <http://dx.doi.org/10.1159/000343732>
- Deters LA, Belanger G, Shah O, Pais VM. Ultrasound guided ureteroscopy in pregnancy. *Clin Nephrol* 2013;79:118-23. DOI: <http://dx.doi.org/10.5414/CN107654>
- Akpinar H, Tufek I, Alici B, Kural AR. Ureteroscopy and holmium laser lithotripsy in pregnancy: stents must be used postoperatively. *J Endourol* 2006;20:107-10. DOI: <http://dx.doi.org/10.1089/end.2006.20.107>
- Kunitz O, Rossaint R. Anesthesia during pregnancy. *Chirurg* 2005;76:737-43. PMID: 16047202
- Bánhidý F, Acs N, Puhó EH, Czeizel AE. Maternal kidney stones during pregnancy and adverse birth outcomes, particularly congenital abnormalities in the offspring. *Arch Gynecol Obstet* 2007;275:481-7. PMID: 17096158 DOI: <http://dx.doi.org/10.1007/s00404-006-0277-1>

36. Johnson EB, Krambeck AE, White WM, Hyams E, Beddies J, Marien T, et al. Obstetric complications of ureteroscopy during pregnancy. *J Urol* 2012;188:151-4. DOI: <http://dx.doi.org/10.1016/j.juro.2012.02.2566>
37. Cormier CM, Canzoneri BJ, Lewis DF, Briery C, Knoepp L, Mailhes JB. Urolithiasis in pregnancy: Current diagnosis, treatment, and pregnancy complications. *Obstet Gynecol Surv* 2006;61:733-41. PMID: 17044950 DOI: <http://dx.doi.org/10.1097/01.ogx.0000243773.05916.7a>
38. Rosenberg E, Sergienko R, Abu-Ghanem S, Wiznitzer A, Romanowsky I, Neulander EZ, et al. Nephrolithiasis during pregnancy: characteristics, complications, and pregnancy outcome. *World J Urol* 2011;29:743-7. DOI: <http://dx.doi.org/10.1007/s00345-011-0719-7>
39. U.S. Food and Drug Administration Pregnancy Registries. 2013 [Acesso 30 Julho 2014]. Disponível em: <http://www.fda.gov/ScienceResearch/SpecialTopics/WomensHealthResearch/ucm251314.htm>