

## Histologic variants of primary focal segmental glomerulosclerosis: presentation and outcome

### Authors

Luis F. Arias<sup>1</sup>

Carlos A. Jiménez<sup>2</sup>

Mariam J Arroyave<sup>1</sup>

<sup>1</sup> Department of Pathology, University of Antioquia.

<sup>2</sup> Department of Pathology, Universidad de Antioquia (Department of Pathology, Valle del Lili Foundation).

Submitted on: 01/16/2013.

Approved on: 04/20/2013.

### Correspondence to:

Luis F. Arias.  
PRYT Group, Department of Pathology, Faculty of Medicine, University of Antioquia, Medellín, Colombia.  
Department of Pathology, Faculty of Medicine, University of Antioquia, Carrera 51D, n° 62-29, Medellín, Colombia.  
E-mail: lfarias@kidneypathology.com  
Tel: (+57) 4219-2412.  
Fax: (+57) 4263-0253.  
University of Antioquia.

DOI: 10.5935/0101-2800.20130019

### ABSTRACT

**Introduction:** The clinical significance of histologic variants of primary focal segmental glomerulosclerosis (FSGS) remains unclear. With the aim to determine presentation and outcome of the variants of FSGS in a hispanic population, we studied our cases of this glomerulopathy. **Methods:** In this retrospective study, all renal biopsies with FSGS (1998-2009), were classified according to the Columbia's classification. We analyzed histological, clinical and follow-up data and compared among variants. **Results:** Among 291 cases, 224 (77.0%) corresponded to NOS variant, 40 cases (13.7%) to tip variant (TIP), 14 cases (4.8%) to perihilar (PH), 10 cases (3.4%) to collapsing (COLL) and three cases (1.0%) to cellular variant (CELL). Median age: 26 years (range 1 to 79); 74 patients (25.4%) were < 15 years of age. Hypertension and renal dysfunction were more frequent in PH and COLL cases. PH presented frequently as non-nephrotic proteinuria. There were fewer histologic chronic lesions in TIP cases. There was remission in 23.5% of patients with NOS, 57.7% of patients with TIP, 22.2% of patients with COLL and 0 patients with PH ( $p < 0.01$ ). Chronic kidney disease (CKD) was less frequent in TIP than in the other variants ( $p = 0.03$ ). There were not statistical differences for end-stage renal disease among variants. **Conclusion:** Glomerular histological appearance is not a good indicator of outcome. COLL is a disease with many differences to the other variants and bad prognosis; PH is a variant mainly of adults, with frequent evolution to CKD. TIP appears as a less aggressive, although not benign, variant.

**Keywords:** glomerulosclerosis, focal segmental; kidney glomerulus; nephrotic syndrome; podocytes.

### INTRODUCTION

Although we refer to “focal and segmental glomerulosclerosis” (FSGS) as a glomerular disease, at present, this glomerular “morphological change” is considered a “pattern of injury”<sup>1</sup> associated to diverse factors (secondary) or without any “known” associated factor or cause (primary); in fact, it is a morphologic presentation common to diverse mechanisms of disease. Its diagnosis is based on morphological changes: focal and segmental sclerosis and/or hyalinosis, and absence of diffuse immune deposits on immunopathology. In the future, when we will know more about the etiology and pathogenesis, the term “FSGS” will be obsolete, and each case will be renamed according to its cause or physiopathology.<sup>2</sup> The term “FSGS” is a misnomer, as it is not always focal or segmental, or even sclerotic (in some cases the lesions are hyaline or collapsing);<sup>3</sup> nevertheless the denomination “FSGS” is extensively used. FSGS is considered the main cause of nephrotic syndrome in some ethnic/geographical groups, and it is one of the three main causes of the syndrome worldwide.<sup>4,8</sup> In our country and in Latin America FSGS is the more frequent primary glomerulopathy diagnosed by biopsy.<sup>4,5</sup>

Define, diagnose, and treat a disease that is heterogeneous in morphology and clinical presentation is a difficult task, as it is to compare its prognosis and treatment among different centers. Our ignorance has led us to try dividing the disease according to their morphological features. Several histological variants has been described, and now the more used morphologic classification is known as “the Columbia classification” of FSGS,<sup>9</sup> with

five pathologic variants: collapsing (COLL), cellular (CELL), tip (TIP), perihilar (PH) and not otherwise specified (NOS). However the prognostic and therapeutic utility of this classification remains unclear, largely because studies that have assessed the clinical relevance of the histologic variants of primary FSGS are few and conflicting, and several with short follow-up time.

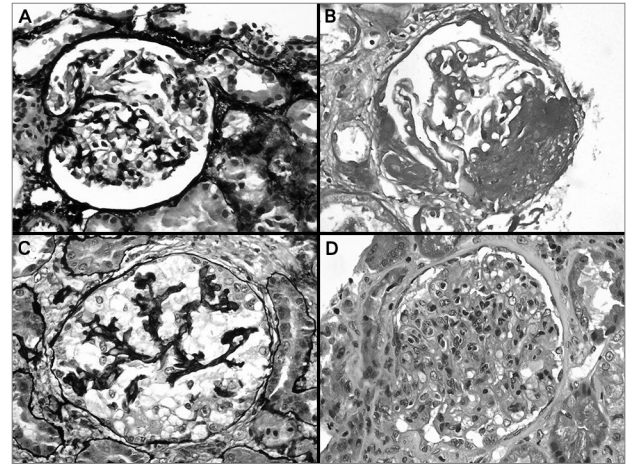
The aim of this retrospective work was determine the clinical and histological features, and outcome of the morphologic variants of FSGS in a different geographical population.

## METHODS

This is a descriptive, retrospective, clinicopathologic study. All native renal biopsies diagnosed as FSGS in our department between August 1998 and December 2009 were revised and classified according to the Columbia classification of FSGS.<sup>9</sup> Light microscopic examination of slides (21 to 42 sections) stained with haematoxylin and eosin, Masson's trichrome, PAS, and methenamine-silver provided the diagnosis of FSGS and categorization into one of the five variants. Immunofluorescence (for IgA, IgG, IgM, C3, C1q,  $\kappa$ , and  $\lambda$ ) and clinical information were used to exclude nonprimary causes of FSGS or other glomerulopathies. Cases with low serum complement levels, no proteinuria, systemic disease, chronic viral infection, any suspect of immune-mediated disease, congenital nephrotic syndrome, or familial history of renal disease suggesting a hereditary glomerulopathy were excluded. All the cases diagnosed as minimal change disease were also revised, and those with tip lesions (n = 3) were included in the study as TIP cases. All the specimens were cylinders obtained by core biopsy. Criteria to assign each case in a category of the Columbia classification was based exclusively in the paper by D'Agati *et al.*<sup>9</sup> (the original publication of the classification) (Figure 1); to diagnose TIP or PH it was required to identify the proximal tubular pole or the glomerular vascular pole, respectively, in the defining glomerulus. Glomeruli with global sclerosis (GS) and glomeruli with segmental lesions were quantified as percentage of total glomeruli or percentage of viable glomeruli, respectively. The percentage of interstitial fibrosis was semiquantitatively calculated as no fibrosis or mild, moderate or severe, according to Banff schema for renal allograft classification.<sup>10</sup>

Arteriolar hyalinosis was registered as present or absent. The histological evaluation was blinded to clinical and follow-up data.

**Figure 1.** A: Glomerulus with a synechia of the tuft just at the tubular origin, a lesion defining the tip variant; B: Glomerular sclerosis and hyalinosis in the vascular pole; in some cases serial sections are required to identify the vascular pole; C: Collapsing lesion with notorious hypertrophy and hyperplasia of podocytes; D: Segmental and focal endocapillary proliferation. In an adequate immunopathologic and clinical context, this alteration could correspond to the cellular variant of FSGS; A-C: Methenamine-silver stain; B: PAS stain, and D: Hematoxylin-eosin stain, all x400.



All biopsies came from patients considered as hispanic, according to geographical origin, physical appearance/skin colour, and self-identification, although we know that these features do not exactly indicate racial/ethnic origin because genetic heterogeneity exists and patients could have either Caucasian or African genetic background;<sup>11,12</sup> Hispanic race/ethnicity is a particular mix of ancestors from different races.

Demographic, clinical, and laboratory information at the time of renal biopsy and at follow-up (when possible) was obtained, from medical records, on each patient. Patient's data included gender, age, blood pressure, level of protein excretion, serum creatinine (SCr), and measured creatinine clearance (CrCl) at presentation. Presentation was defined as the time when proteinuria was first detected. Hypertension was defined as systolic blood pressure equal to or greater than 140 mmHg and/or diastolic blood pressure equal to or greater than 90 mmHg, according to the Seventh Report of the Joint National Committee on Prevention, Detection, Evaluation, and Treatment of High Blood Pressure.<sup>13</sup> At the end of follow-up SCr, CrCl, and presence or not of chronic kidney disease (CKD) and end-stage renal disease (ESRD) were registered. CKD was defined as CrCl persistently < 60 mL/

min. Complete remission was defined as proteins in urine  $< 0.3$  g/24h in adults, and  $< 4$  mg/m<sup>2</sup>/h in  $< 15$  years old, and partial remission was defined as proteinuria between 0.31 and 2.5 g/24h in adults and between 4 and 40 mg/m<sup>2</sup>/h in  $< 15$  years old. We compare clinical and morphological features among the histological variants of FSGS. ESRD was registered in all the cases with this event, although for the analyses of outcome, CKD was taken as the endpoint. For follow-up analyses we included only patients with at least 2 years of follow-up, or patients developing the end-point before two years.

### STATISTICAL ANALYSES

Data are expressed as mean  $\pm$  SD or, where indicated, as median and ranges, according to the variables and Kolmogorov-Smirnov test for normality.  $\chi^2$  test, or Fisher's exact test were used to compare percentages. Unpaired *t* test or Mann-Whitney test were used to compare means, according to normality test. *P* values  $< 0.05$  were considered statistically significant in two tailed tests. All analysis was done using SPSS® software, version 16.0 (SPSS Inc, Chicago, IL).

### RESULTS

Among 1.412 native renal biopsies in the time period of the study, 291 had the confirmed diagnosis of primary FSGS (20.6%; 27.7% of glomerulopathies). According to the Columbia classification, 224 cases (77.0%) correspond to NOS variant, 40 cases (13.7%) to TIP, 14 cases (4.8%) to PH, 10 cases (3.4%) to COLL and 3 cases (1.0%) to CELL. Median age of patients was 26 years (range 1 to 79); 74 patients (25.4%) were  $< 15$  years of age; 26 patients (8.9%) were  $> 60$  years of age; 56.7% were males. There were not cases of PH in  $< 15$  years old. As so few patients were identified with CELL, data for this group are presented but not included in the statistical comparisons among variants. Clinical characteristics at presentation are shown in Table 1. Patients with PH were significantly older, and patients with TIP and COLL significantly younger. Hypertension was more frequent in patients with PH and COLL. Also, serum creatinine level and creatinine clearance were more altered in PH and COLL cases. Although the level of proteinuria was higher in COLL, it was statistically significantly only in  $< 15$  years old. PH variant presented more frequently than the other variants as non-nephrotic proteinuria (Table 1).

The number of glomeruli for evaluation by light microscopy was  $16.7 \pm 12.9$  (range 6-104; median: 14) and there was no significant difference among groups (Table 2). There were significantly less global glomerulosclerosis, glomerular segmental lesions, interstitial fibrosis and arteriolar hyalinosis in TIP cases than in the other variants (Table 2). In COLL cases there were significantly more glomerular segmental lesions, and in PH significantly more arteriolar hyalinosis than in the other variants (Table 2). In TIP, glomerular lesions included glomerular tip lesion alone in 25 cases (62.5%) and tip lesion with peripheral and/or indeterminate lesions in 15 (37.5%).

### CLINICAL OUTCOME

Follow-up data were available on 151 patients (51.9%), 8 of them developed ESRD before 2 years of follow-up (at 6-18 months). The number of cases with follow-up data for variant was: NOS: 105 (46.9% within this variant); tip: 26 (65.0%); perihilar: 8 (57.1%); COLL: 9 (90%). In the 3 cases of cellular variant there was follow-up (25, 28 and 36 months). The median of follow-up in patients who did not develop ESRD before 2 years was 40.0 months (24.3-160.0); 65.2% of the cases with  $> 36$  months.

Treatment was very variable among patients; many received several immunosuppressants, including prednisone, cyclosporine, mycophenolate, azathioprine and/or cyclophosphamide, for a variable time. Although an adequate comparison for treatment among variants was not possible, there were not statistical differences for percentage of cases receiving immunosuppressants.

Remission (complete or partial) was attained in 23.5% of patients with NOS, 57.7% of patients with TIP, 22.2% of patients with COLL and in 0 patients with PH ( $p < 0.01$ ) (Table 3). CKD was significantly less frequent in TIP than in the other variants ( $p = 0.03$ ). With our follow-up time, there was not statistical difference for ESRD among variants. The statistical differences for remission and CKD were lost in the group of patients  $< 15$  years old (Table 3).

The median of follow-up in patients who developed CKD was 50.0 months (24.3-160.0) and in patients no developing CKD was 49.2 months (24.4-159) ( $p = 0.47$ ). There were not statistical differences for follow-up time between patients with and without CKD in the groups with NOS, TIP, PH, and COLL. In patients with CELL, two developed CKD, one with ESRD; the other one had complete remission.

**TABLE 1** CLINICAL CHARACTERISTICS AT PRESENTATION

Characteristics	NOS	TIP	Perihilar	Collapsing	<i>p</i>
n	224	40	14	10	-
Male	54%	60%	78.6%	60%	0.23
Age <sup>a</sup>	28 (1-79)	17 (1-65)	44 (18-65)	11 (3-66)	< 0.01
Hypertension <sup>b</sup>	67.1%	50%	83.3%	100%	0.03
Creatinine <sup>c</sup>	1.2 ± 1.0	1.1 ± 1.0	1.4 ± 0.6	2.8 ± 3.8	0.03
Creatinine clearance <sup>d</sup>	80.5 ± 33.4	92.1 ± 33.0	74.3 ± 32.2	50.1 ± 41.2	0.07
Proteinuria adults (g/24h) (n = 217)	6.9 ± 5.9	6.3 ± 5.0	3.9 ± 2.4	9.7 ± 6.4	0.45
Proteinuria < 15y (mg/m <sup>2</sup> /h) (n = 74)	153 ± 110	127 ± 98	No cases	198 ± 104	0.02
Nephrotic proteinuria <sup>b</sup>	81.7%	95%	57.1%	100%	< 0.01

<sup>a</sup> Age: median (minimal - maximal values); <sup>b</sup> Percentages of cases with hypertension and nephrotic proteinuria, respectively; <sup>c</sup> mg/dL; <sup>d</sup> mL/minute.

**TABLE 2** HISTOLOGIC COMPARISON AMONG GROUPS

Characteristics	NOS	TIP	Perihilar	Collapsing	<i>p</i>
n	224	40	14	10	-
Total glomeruli	15.8 ± 12.9	19.4 ± 9.4	16.7 ± 13.5	25.4 ± 19.7	0.06
Global GS (%)	8.0 (0-86)	0.0 (0-30)	9.4 (0-65)	5.0 (0-50)	< 0.01
Segmental lesions (%)	24.2 (2-100)	16.3 (3-57)	27.9 (14-67)	50.0 (22-100)	< 0.01
Total glomeruli with lesions (%)	35.8 (3-100)	16.3 (4-70)	42.2 (14-87)	57.8 (22-100)	< 0.01
Interstitial fibrosis <sup>a</sup>	18.8	2.5	21.4	20.0	0.03
Arteriolar hyalinosis <sup>b</sup>	42.4	12.5	78.6	20	< 0.01

<sup>a</sup> Percentage of cases with interstitial fibrosis > 25% (moderate or severe); <sup>b</sup> % o cases with any degree of arteriolar hyalinosis

**TABLE 3** OUTCOME COMPARISON AMONG HISTOLOGIC VARIANTS

	NOS	TIP	Perihilar	Collapsing	<i>p</i>
n	105 (45.5%)	26 (65.0%)	8 (57.1%)	9 (90%)	-
Follow-up (months)	38 (24-159)	52 (24-87)	44 (27-160)	40 (26-61)	0.34
Remission	24 (23.5%)	15 (57.7%)	0 (0.0%)	2 (22.2%)	< 0.01
Complete	12 (11.8%)	8 (30.8%)	0 (0.0%)	1 (11.1%)	0.07
Partial	12 (11.8%)	7 (26.9%)	0 (0.0%)	1 (11.1%)	0.16
CKD	55 (53.9%)	8 (30.8%)	7 (87.5%)	5 (55.6%)	0.03
ESRD	20 (19.6%)	5 (19.2)	1 (12.5%)	3 (33.3%)	0.74
Adults (≥ 15 years)	n = 69	n = 17	n = 8	n = 4	-
Complete remission	6 (8.7%)	7 (41.2%)	0 (0.0%)	0 (0.0%)	< 0.01
CKD	44 (63.8%)	3 (17.6%)	7 (87.5%)	3 (75%)	< 0.01
ESRD	13 (18.8%)	3 (17.6%)	1 (12.5%)	2 (50%)	0.46
Children (< 15 years)	n = 33	n = 9	n = 0	n = 5	-
Complete remission	6 (18.2%)	1 (11.1%)	-	1 (20%)	0.95
CKD	11 (33.3%)	5 (55.6%)	-	2 (40%)	0.51
ESRD	7 (21.2%)	2 (22.2%)	-	1 (20%)	1.00

NOS: Not otherwise specified variant; TIP: Tip variant; CKD: Chronic kidney disease; ESRD: End-stage renal disease.

## DISCUSSION

In this work we reviewed the clinical presentation, histopathologic findings and outcome of FSGS, according to the Columbia's histologic variant of

the glomerulopathy, in a series of patients from an ethnic/geographical population without previous reports on these variants of FSGS; for the best of our knowledge this is the first case series on presentation and outcome of the different histologic variants of

FSGS in Latin America. In a previous report from Brazil<sup>14</sup> analyzing immunohistochemical podocyte markers, the authors reported percentage frequencies almost similar to our study for TIP, PH and CELL variants (14.5%, 6.9% and 3.8% respectively), however, the percentage frequency for COLL (36.6%) was notoriously higher in the Brazilian series. We do not know the reason for this difference; it is possible that population characteristics or environmental factors influence the results of these works. Our series increases the worldwide information about the clinical or prognosis relevance of the FSGS variants. FSGS is the more frequent glomerular disease in our population, but we do not know the cause of this increased frequency in our region. Proportions of the Columbia's variants appear not very different that in other series,<sup>1,15-17</sup> and several results on presentation, chronic histologic lesions and outcome are not different than in other previous published works, however, some of our results show interesting aspects of these variants, as we will discuss in the next paragraphs.

According to definition of CELL, the diagnosis requires the presence of endocapillary hypercellularity with occlusion of capillary lumina, with foam cells and/or macrophages and/or endothelial cells and/or neutrophils and/or lymphocytes; there may be pyknotic or karyorrhectic debris and endocapillary fibrin.<sup>9</sup> As we can deduce from this microscopic features, in our 3 cases, lesions were similar to endocapillary proliferative glomerulonephritis (in immune mediated glomerular diseases). As "neither hyalinosis nor segmental sclerosis are required features",<sup>9</sup> it was essential in these cases a rigorous examination and analysis of immunofluorescence (IF), other histological features, clinical manifestations, and, in two cases, electron microscopy. The ultrastructural alterations can be essential to distinguish CELL variant from other glomerulopathies. We do not know if the low frequency of this diagnosis is actually due to rarity of this variant or if the difficulty on its diagnosis contributes to this low frequency. In our series cellular variant correspond to 1.0%; in all three, the diagnosis required search for a second opinion from an experienced nephropathologist. In the series by Chun *et al.*,<sup>1</sup> with 87 patients with FSGS diagnosis, there were not cases of cellular variant, as described by the Columbia classification. Endocapillary hypercellularity, a diagnostic criterion of the cellular variant, can be also found in collapsing

variant cases.<sup>16</sup> Overlapping histological findings in the collapsing and cellular variants sometimes cause difficulty in identifying the variant; further studies are needed to identify clear differences between these variants to apply to cases with histologically overlapping findings.<sup>17,18</sup> On the other hand, endocapillary hypercellularity involving the tip domain rules out the cellular variant, as endocapillary hypercellularity may characterize lesions in tip variant. Cellular variant may include cases of unsampled tip or collapsing lesions.<sup>16</sup> Implications for cellular variant diagnosis are unknown as so few patients are registered in most series reported. To the best of our knowledge, the work with the largest number of cases was that by Stokes *et al.* (n = 22),<sup>16</sup> and the authors reported rates of remission and ESRD no statistically different to NOS. In our 3 cases, one developed ESRD, other one CKD, not yet terminal (28 months of follow-up) and the remaining patient presented remission.

It has been postulated that tip lesion simply represents a response to heavy proteinuria,<sup>19</sup> and cases of nephrotic syndrome with tip lesions, but no other histological abnormalities, may represent a form of minimal change nephropathy.<sup>20-22</sup> However, others have reported that such lesions have a clinical course similar to that of primary FSGS.<sup>1,23</sup> The definition of the genuine glomerular tip lesion in the papers by the original authors has been the presence of changes at the tubular origin and nowhere else, in glomeruli that are otherwise normal on light microscopy.<sup>20,24</sup> In the Columbia classification are included cases with peripheral and/or indeterminate lesions, which mean that some at least are not the glomerular tip lesion as originally defined. We found that there was a lower percentage of CKD in patients with tip lesions alone (neither peripheral nor indeterminate lesions) than in patients with tip lesions and other glomerular segmental lesions (included in the TIP variant as defined in the Columbia classification), but this difference was not statistically significant.<sup>25</sup> It appears that GTL, whether defined by the original definition<sup>20,24</sup> or the less restrictive in the Columbia Classification,<sup>9</sup> represents a heterogeneous group of lesions that can behave like minimal change disease or like FSGS.<sup>26</sup> Routine light and electron microscopy cannot distinguish them, although in the future, it is possible that immunohistologic studies of podocyte proteins whose expression would be altered in FSGS but not minimal

change disease, or vice versa, may prove helpful in this regard, for now, only the response to treatment can predict the outcome of the GTL.<sup>27</sup>

Several reports in nephrotic patients with TIP suggest an excellent response to steroids and/or more favourable course,<sup>20-22,24,28-30</sup> but other authors have reported that the response and course are similar to that of patients with NOS and question the clinical significance of this feature.<sup>24,31-34</sup> We found that although TIP presents with less chronic histologic alterations, the prognostic implications for this diagnosis were not “favourable”: CKD developed in 30.8% and ESRD in 19.2% of our patients. Although the outcome was worse in the other variants, our data suggest that the tip variant should not be considered a prognostically favourable disease. In fact, it could be a more early stage of a severe glomerular disease. Also in the work by Howie *et al.*,<sup>26</sup> they conclude that “many patients have a good outcome but that some will progress pathologically and clinically” and that “progression of GTL to FSGS (NOS) is not uncommon”, then, it is not a “benign” disease.

It was interesting in our work that in TIP cases, remission was lower and CKD was higher in < 15 years old compared to ≥ 15 years old, but the case number in each of these two groups was low (9 and 17 patients, respectively) and these differences can be spurious.

The term “collapsing glomerulopathy” was used for the first time in 1986,<sup>35</sup> and it was assumed to be a variant of FSGS.<sup>30,36,37</sup> However, COLL is frequently an aggressive disease, with massive proteinuria and rapidly progressive renal disease. In our series, 55.5% of cases progressed to CKD in the 5 years after initial presentation. The notoriously more aggressive outcome in COLL that in the other variants of FSGS, and the phenotypic features of podocytes suggesting a different pathogenesis,<sup>38,39</sup> have led some authors to propose that collapsing glomerulopathy is not a variant of FSGS; we think that it is a different disease, and it should not be considered a variant of FSGS.

It is believed that PH variant is commonly associated with secondary forms to hyperfiltration or nephron loss or glomerular hypertension.<sup>9</sup> In our series PH presented more frequently than the other variants with non-nephrotic proteinuria: 42.9%. This lower level of proteinuria has been also reported by other authors.<sup>17</sup> All our patients were > 15

years old (18-65) and 85.0% of cases with follow-up developed CKD. Histological chronic lesions were more severe in PH than in NOS and TIP, and near to COLL. These facts suggest that morphological lesions develop gradually and not in an abrupt manner as in the other variants, resulting clinically in disorders of insidious onset and slow but steady progression.

NOS variant is a heterogeneous glomerulopathy; in fact, it is a common morphological lesion in many glomerular and non-glomerular diseases. It is the most common histological form of FSGS: 77% of our cases. It is very interesting that all the other 4 variants may evolve into this pattern in the course of disease progression and increasing chronicity: i.e. it is an unspecific glomerulopathy with many known and unknown etiologies. It is a “collage” of glomerular alterations that converge on a common morphological pattern. The NOS variant is a “junk drawer” of multiple glomerular alterations with this common pattern of lesion, with a mixture of pathophysiological mechanisms that do not allow for now, based only on morphological findings, determine etiology or effective treatment.

This work was based on a retrospective clinical information collection, leading to limitations because this methodology: to determine with precision the moment of the clinical presentation it is very difficult; time between presentation and biopsy can be variable among patients; treatment is different according to treating nephrologists; adherence to treatment is very difficult to determine in clinical charts, and possibly other limitations inherent to a retrospective methodology.

## CONCLUSION

In conclusion, glomerular histological appearance does not permit us to know the cause of FSGS and it is not a perfect indicator of outcome. It is possible that in the near future we will know a lot of aspects of FSGS that will give us a better perspective of this glomerulopathy. As a personal view, we believe that CELL is an infrequent and difficult to diagnose variant; COLL is a glomerular disease with clear differences and would be better to separate it from FSGS; PH is a variant mainly of adults, with apparent insidious onset and frequent evolution to CKD; and finally, TIP variant should not be considered as a benign disease.

## ACKNOWLEDGMENTS

Thanks to Dr. Luiz A. Moura for his help in preparing the manuscript.

## REFERENCES

- Chun MJ, Korbet SM, Schwartz MM, Lewis EJ. Focal segmental glomerulosclerosis in nephrotic adults: presentation, prognosis, and response to therapy of the histologic variants. *J Am Soc Nephrol* 2004;15:2169-77. <http://dx.doi.org/10.1097/01.ASN.0000135051.62500.97> PMID:15284302
- Cameron JS. Focal segmental glomerulosclerosis in adults. *Nephrol Dial Transplant* 2003;18:vi45-51. <http://dx.doi.org/10.1093/ndt/gfg1058> PMID:12953042
- Meyrier A. Focal and segmental glomerulosclerosis: multiple pathways are involved. *Semin Nephrol* 2011;31:326-32. <http://dx.doi.org/10.1016/j.semnephrol.2011.06.003> PMID:21839365
- Arias LF, Henao J, Giraldo RD, Carvajal N, Rodelo J, Arbeláez M. Glomerular diseases in a Hispanic population: review of a regional renal biopsy database. *Sao Paulo Med J* 2009;127:140-4. <http://dx.doi.org/10.1590/S1516-31802009000300006> PMID:19820874
- Polito MG, de Moura LA, Kirsztajn GM. An overview on frequency of renal biopsy diagnosis in Brazil: clinical and pathological patterns based on 9,617 native kidney biopsies. *Nephrol Dial Transplant* 2010;25:490-6. <http://dx.doi.org/10.1093/ndt/gfp355> PMID:19633091
- Korbet SM, Genchi RM, Borok RZ, Schwartz MM. The racial prevalence of glomerular lesions in nephrotic adults. *Am J Kidney Dis* 1996;27:647-51. [http://dx.doi.org/10.1016/S0272-6386\(96\)90098-0](http://dx.doi.org/10.1016/S0272-6386(96)90098-0)
- Rivera F, López-Gómez JM, Pérez-García R; Spanish Registry of Glomerulonephritis. Frequency of renal pathology in Spain 1994-1999. *Nephrol Dial Transplant* 2002;17:1594-2. <http://dx.doi.org/10.1093/ndt/17.9.1594> PMID:12198210
- Gesualdo L, Di Palma AM, Morrone LF, Strippoli GF, Sclena FP; Italian Immunopathology Group, Italian Society of Nephrology. The Italian experience of the national registry of renal biopsies. *Kidney Int* 2004;66:890-4. <http://dx.doi.org/10.1111/j.1523-1755.2004.00831.x> PMID:15327376
- D'Agati VD, Fogo AB, Bruijn JA, Jennette JC. Pathologic classification of focal segmental glomerulosclerosis: a working proposal. *Am J Kidney Dis* 2004;43:368-82. <http://dx.doi.org/10.1053/j.ajkd.2003.10.024> PMID:14750104
- Racusen LC, Solez K, Colvin RB, Bonsib SM, Castro MC, Cavallo T, et al. The Banff 97 working classification of renal allograft pathology. *Kidney Int* 1999;55:713-23. <http://dx.doi.org/10.1046/j.1523-1755.1999.00299.x> PMID:9987096
- Chernin G, Heeringa SE, Vega-Warner V, Schoeb DS, Nürnberg P, Hildebrandt F. Adequate use of allele frequencies in Hispanics--a problem elucidated in nephrotic syndrome. *Pediatr Nephrol* 2010;25:261-6. <http://dx.doi.org/10.1007/s00467-009-1315-6> PMID:19876656 PMCid:2899680
- Parra FC, Amado RC, Lambertucci JR, Rocha J, Antunes CM, Pena SD. Color and genomic ancestry in Brazilians. *Proc Natl Acad Sci U S A* 2003;100:177-82. <http://dx.doi.org/10.1073/pnas.0126614100> PMID:12509516 PMCid:140919
- Chobanian AV, Bakris GL, Black HR, Cushman WC, Green LA, Izzo JL Jr, et al.; Joint National Committee on Prevention, Detection, Evaluation, and Treatment of High Blood Pressure. National Heart, Lung, and Blood Institute; National High Blood Pressure Education Program Coordinating Committee. Seventh report of the Joint National Committee on Prevention, Detection, Evaluation, and Treatment of High Blood Pressure. *Hypertension* 2003;42:1206-52. <http://dx.doi.org/10.1161/01.HYP.0000107251.49515.c2> PMID:14656957
- Testagrossa L, Azevedo Neto R, Resende A, Woronik V, Malheiros D. Immunohistochemical expression of podocyte markers in the variants of focal segmental glomerulosclerosis. *Nephrol Dial Transplant* 2013;28:91-8. <http://dx.doi.org/10.1093/ndt/gfs325> PMID:22859792
- Thomas DB, Franceschini N, Hogan SL, Ten Holder S, Jennette CE, Falk RJ, et al. Clinical and pathologic characteristics of focal segmental glomerulosclerosis pathologic variants. *Kidney Int* 2006;69:920-6. <http://dx.doi.org/10.1038/sj.ki.5000160> PMID:16518352
- Stokes MB, Valeri AM, Markowitz GS, D'Agati VD. Cellular focal segmental glomerulosclerosis: Clinical and pathologic features. *Kidney Int*. 2006;70:1783-92. <http://dx.doi.org/10.1038/sj.ki.5001903> PMID:17021605
- Taneda S, Honda K, Uchida K, Nitta K, Yumura W, Oda H, et al. Histological heterogeneity of glomerular segmental lesions in focal segmental glomerulosclerosis. *Int Urol Nephrol* 2012;44:183-96. <http://dx.doi.org/10.1007/s11255-011-9932-y> PMID:21424374 PMCid:3253997
- Schwartz MM, Evans J, Bain R, Korbet SM. Focal segmental glomerulosclerosis: prognostic implications of the cellular lesion. *J Am Soc Nephrol* 1999;10:1900-7. PMID:10477141
- Haas M, Yousefzadeh N. Glomerular tip lesion in minimal change nephropathy: a study of autopsies before 1950. *Am J Kidney Dis* 2002;39:1168-75. <http://dx.doi.org/10.1053/ajkd.2002.33386> PMID:12046027
- Howie AJ, Brewer DB. The glomerular tip lesion: a previously undescribed type of segmental glomerular abnormality. *J Pathol* 1984;142:205-20. <http://dx.doi.org/10.1002/path.1711420308> PMID:6707787
- Howie AJ, Lee SJ, Green NJ, Newbold KM, Kizaki T, Koram A, et al. Different clinicopathological types of segmental sclerosing glomerular lesions in adults. *Nephrol Dial Transplant* 1993;8:590-9. PMID:8396741
- Ito H, Yoshikawa N, Aozai F, Hazikano H, Sakaguchi H, Akamatsu R, et al. Twenty-seven children with focal segmental glomerulosclerosis: correlation between the segmental location of the glomerular lesions and prognosis. *Clin Nephrol* 1984;22:9-14. PMID:6478668
- Schwartz MM, Korbet SM, Rydell J, Borok R, Genchi R. Primary focal segmental glomerular sclerosis in adults: prognostic value of histologic variants. *Am J Kidney Dis* 1995;25:845-52. [http://dx.doi.org/10.1016/0272-6386\(95\)90566-9](http://dx.doi.org/10.1016/0272-6386(95)90566-9)
- Howie AJ, Brewer DB. Further studies on the glomerular tip lesion: early and late stages and life table analysis. *J Pathol* 1985;147:245-55. <http://dx.doi.org/10.1002/path.1711470403> PMID:4087076
- Arias LF, Franco-Alzate C, Rojas SL. Tip variant of focal segmental glomerulosclerosis: outcome and comparison to 'not otherwise specified' variant. *Nephrol Dial Transplant* 2011;26:2215-21. <http://dx.doi.org/10.1093/ndt/gfq668> PMID:21068139
- Howie AJ, Pankhurst T, Sarioglu S, Turhan N, Adu D. Evolution of nephrotic-associated focal segmental glomerulosclerosis and relation to the glomerular tip lesion. *Kidney Int* 2005;67:987-1001. <http://dx.doi.org/10.1111/j.1523-1755.2005.00162.x> PMID:15698437
- Haas M. The glomerular tip lesion: what does it really mean? *Kidney Int* 2005;67:1188-9. <http://dx.doi.org/10.1111/j.1523-1755.2005.00188.x> PMID:15698461
- Howie AJ, Agarwal A, Sebire NJ, Trompeter RS. Glomerular tip changes in childhood minimal change nephropathy. *Pediatr Nephrol* 2008;23:1281-6. <http://dx.doi.org/10.1007/s00467-008-0823-0> PMID:18446377
- Stokes MB, Markowitz GS, Lin J, Valeri AM, D'Agati VD. Glomerular tip lesion: a distinct entity within the minimal change disease/focal segmental glomerulosclerosis spectrum. *Kidney Int* 2004;65:1690-2. <http://dx.doi.org/10.1111/j.1523-1755.2004.00563.x> PMID:15086908

30. D'Agati VD, Alster JM, Jennette JC, Thomas DB, Pullman J, Savino DA, et al. Association of histologic variants in FSGS clinical trial with presenting features and outcomes. *Clin J Am Soc Nephrol* 2013;8:399-6. <http://dx.doi.org/10.2215/CJN.06100612> PMID:23220425
31. Arias LF, Franco-Alzate C, Rojas SL. Tip variant of focal segmental glomerulosclerosis: outcome and comparison to 'not otherwise specified' variant. *Nephrol Dial Transplant* 2011;26:2215-21. <http://dx.doi.org/10.1093/ndt/gfq668> PMID:21068139
32. Paik KH, Lee BH, Cho HY, Kang HG, Ha IS, Cheong HI, et al. Primary focal segmental glomerular sclerosis in children: clinical course and prognosis. *Pediatr Nephrol* 2007;22:389-95. <http://dx.doi.org/10.1007/s00467-006-0301-5> PMID:17058050
33. Morita M, White RH, Coad NA, Raafat F. The clinical significance of the glomerular location of segmental lesions in focal segmental glomerulosclerosis. *Clin Nephrol* 1990;33:211-9. PMID:2354557
34. Hupples W, Hené RJ, Kooiker CJ. The glomerular tip lesion: a distinct entity or not? *J Pathol* 1988;154:187-90. <http://dx.doi.org/10.1002/path.1711540212> PMID:3280767
35. Weiss MA, Daquiaoag E, Margolin EG, Pollak VE. Nephrotic syndrome, progressive irreversible renal failure, and glomerular "collapse": a new clinicopathologic entity? *Am J Kidney Dis* 1986;7:20-8. PMID:3510532
36. Derwiler RK, Falk RJ, Hogan SL, Jennette JC. Collapsing glomerulopathy: a clinically and pathologically distinct variant of focal segmental glomerulosclerosis. *Kidney Int* 1994;45:1416-24. <http://dx.doi.org/10.1038/ki.1994.185> PMID:8072254
37. Valeri A, Barisoni L, Appel GB, Seigle R, D'Agati V. Idiopathic collapsing focal segmental glomerulosclerosis: a clinicopathologic study. *Kidney Int* 1996;50:1734-46. <http://dx.doi.org/10.1038/ki.1996.493> PMID:8914044
38. Hodgins JB, Borczuk AC, Nasr SH, Markowitz GS, Nair V, Martini S, et al. A molecular profile of focal segmental glomerulosclerosis from formalin-fixed, paraffin-embedded tissue. *Am J Pathol* 2010;177:1674-86. <http://dx.doi.org/10.2353/ajpath.2010.090746> PMID:20847290 PMCid:2947265
39. Shkreli M, Sarin KY, Pech MF, Papeta N, Chang W, Brockman SA, et al. Reversible cell-cycle entry in adult kidney podocytes through regulated control of telomerase and Wnt signaling. *Nat Med* 2011;18:111-9. <http://dx.doi.org/10.1038/nm.2550> PMID:22138751 PMCid:3272332