

Erythropoietin resistance in end-stage renal disease patient with gastric antral vascular ectasia

Resistência à eritropoetina em paciente com IRC e ectasia vascular gástrica

Autores

Desiree Ji Re Lee¹
 Juliana Fragata²
 José Osmar Medina Pestana¹
 Sergio Draibe¹
 Maria Eugênia Canziani¹
 Miguel Cendoroglo¹
 Miguel Ângelo de Góes Jr.¹

¹ Escola Paulista de Medicina, EPM/UNIFESP.

² Hospital do Rim.

ABSTRACT

We observed a case of recombinant human erythropoietin resistance caused by Gastric Antral Vascular Ectasia in a 40-year-old female with ESRD on hemodialysis. Some associated factors such as autoimmune disease, hemolysis, heart and liver disease were discarded on physical examination and complementary tests. The diagnosis is based on the clinical history and endoscopic appearance of watermelon stomach. The histologic findings are fibromuscular proliferation and capillary ectasia with microvascular thrombosis of the lamina propria. However, these histologic findings are not necessary to confirm the diagnosis. Gastric Antral Vascular Ectasia is a serious condition and should be considered in ESRD patients on hemodialysis with anemia and resistance to recombinant human erythropoietin because GAVE is potentially curable with specific endoscopic treatment method or through surgical procedure.

Keywords: anemia, chronic, erythropoietin, gastric antral vascular ectasia, kidney failure.

RESUMO

Observou-se um caso de resistência à eritropoetina recombinante humana causada por Ectasia Vascular Antral Gástrica em uma mulher de 40 anos de idade, com doença renal terminal em hemodiálise. Alguns fatores associados, tais como a doença autoimune, hemólise, doenças cardíacas e hepáticas foram descartados no exame físico e exames complementares. O diagnóstico é baseado na história clínica e aspecto endoscópico de estômago em melancia. Os achados histológicos são proliferação fibromuscular e ectasia capilar com trombose microvascular da lâmina própria. No entanto, esses achados histológicos não são necessários para confirmar o diagnóstico. Ectasia Vascular Antral Gástrica é uma condição séria e deve ser considerada em pacientes com insuficiência renal terminal em hemodiálise com anemia refratária e resistência à eritropoetina humana recombinante porque é potencialmente curável com o método de tratamento endoscópico específico ou através de procedimento cirúrgico.

Palavras-chave: anemia refratária, ectasia vascular gástrica antral, eritropoetina, insuficiência renal crônica.

CASE REPORT

A 40-year-old female with end-stage renal disease (ESRD) by hypertension on hemodialysis at Hospital do Rim e Hipertensão-UNIFESP since 2006 had been experiencing anemia, resistance to recombinant human erythropoietin (rHuEPO) and need for blood transfusions twice a week in the last four months.

She had not provided any history of hematuria, gastrointestinal, cardiac, liver or collagen disease. Medications included intravenous saccharate of iron III

(100 mg weekly), subcutaneous rHuEPO (484 IU/kg/wk), oral folate, B complex, amlodipine, atenolol, sevelamer and omeprazole. Kt/V values 1.3 to 1.5 in the last three months.

Over the preceding 2 months, the patient complained of progressive asthenia and weakness. She experienced an episode of hematemesis and hypotension (Mean Arterial Pressure: 49 mmHg) during dialysis session.

On physical examination we observed mucosal pallor and tachydyspnea. There

Data de submissão: 22/10/2014.

Data de aprovação: 23/10/2014

Correspondência para:

Miguel Ângelo de Góes Jr.
 Division of Nephrology, Federal University of São Paulo, UNIFESP.
 Rua Pedro de Toledo, nº 781 - 14º andar - frente, Vila Clementino.
 São Paulo, SP, Brazil.
 CEP: 04039-000.
 E-mail: miguel.angelo@unifesp.br
 Tel: 55 (11) 5084-6836.
 Fax: 55 (11) 5904-1684.

DOI: 10.5935/0101-2800.20150042

were no stigma of chronic liver disease and rectal examination was positive for melena. There was no Raynaud's phenomenon. Hematologic tests showed a severe decrease in hemoglobin (Hb) from 9.6 g/dL to 4.8 g/dL, hematocrit from 31% to 15.6% and reticulocytosis (2.8%). We also observed decreased Mean Corpuscular Volume (72 m^3), normal Mean Corpuscular Hb (25 pg) and Mean Corpuscular Hb Concentration (29%). Whereas that RDW 16.2%, normal platelet count (221.000 mm^3), activated partial thromboplastin time (28 seconds) and international normalized ratio (INR1.1).

The patient was transferred to the intensive care unit for hemodynamic instability and required 4 units of packed red blood cells (RBC) transfusions to treat anemia and crystalloid solution (2.5 L saline).

Other laboratory findings showed normal total bilirubin (0.9 mg/dL). Blood albumin observed was 3.4 mg/dL. C-reactive protein was 1.1mg/dL. During hospitalization and investigation we observed low levels of iron (28 mg/dL) and transferrin saturation (16%), with high levels of ferritin (860 mg/L) and normal haptoglobin (118.2 mg/dL). Direct and indirect Coombs test were negative. We did not observe any squizocytes. We observed that serum concentrations of cyanocobalamin (284 pg/mL) and folic acid (7.80 nmoL/L) were normal.

Antinuclear antibodies were negative. Transthoracic echocardiogram showed mild left ventricular hypertrophy (144 g/m^2 -index of left ventricular mass), there was no changes in the relaxation of the left ventricle and ejection fraction of 64%. Chest radiograph was normal. Occult blood test in stool was positive. The myelogram revealed an overgrowth of erythroid cell.

The contrast computed tomography scan of abdomen and pelvis revealed no significant gastrointestinal pathology. The mesenteric arteriography had no evidence of bleeding and showed kinking at the splenic artery.

Later she presented recurrent melena, hematemesis and hypotension (Mean Arterial Pressure: 54 mmHg). Colonoscopy was normal and upper-gastrointestinal endoscopy showed a distal erosive esophagitis and intense antral erosive gastritis. There were no esophageal varices. She kept decreasing her Hb levels and was transfused with 40 units of packed RBCs that were carried out in 98 days.

The findings of the second upper-gastrointestinal endoscopy were normal appearance of the pylorus and longitudinal antral folds containing visible stripes of tortuous red ecstastic vessels with bleeding (watermelon stomach - Figure 1). Treatment with Argon plasma coagulation therapy was carried out (Figure 2). A month after endoscopic therapy there was no need for transfusion of RBC and Hb concentration stabilized at 10.2 g/dL and there were no hypotension during hemodialysis.

Figure 1. Watermelon stomach - antral region of the stomach with dilated vessels with signs of active bleeding.

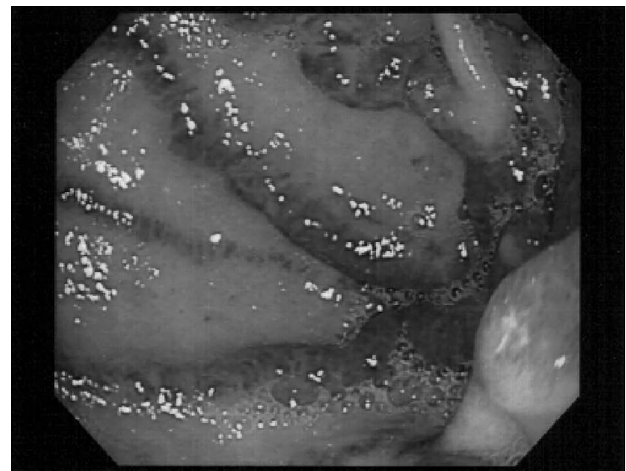
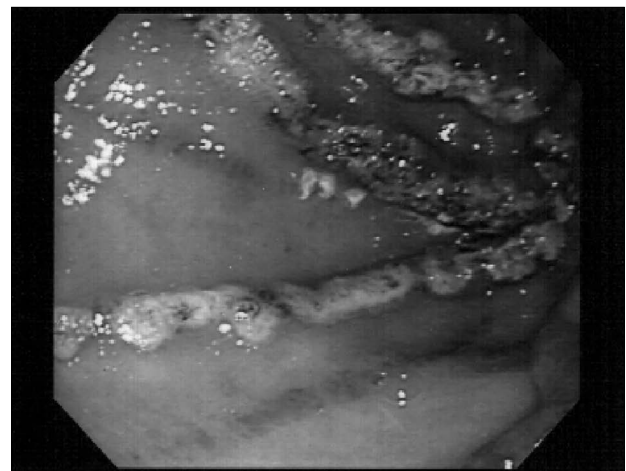


Figure 2. There was no bleeding after treatment with Argon plasma coagulation.



DISCUSSION

We observed an interesting case of rHuEPO resistance caused by GAVE diagnosed by endoscopy in ESRD patient on hemodialysis with appropriate dose.

Inadequate response to erythropoiesis-stimulating agents (ESAs) may be associated with increased

mortality.¹ Iron deficiency is the most common cause of an inadequate response to ESAs therapy which may be due to external blood losses.^{1,2}

We observed gastrointestinal blood loss by rectal examination that was positive for melena and the presence of occult blood in the stool in this patient. This patient required blood transfusion for acute blood loss.³ It is necessary to treat the cause of bleeding and control iron stores to achieve Hb concentration between 10.0 and 12.0 g/dL⁴ with the use of ESAs.⁵ Consequently there was resistance to rHuEPO due to iron deficiency demonstrated by decreased mean corpuscular volume, serum iron concentration and transferrin saturation.

GAVE is a rare cause of upper gastrointestinal bleeding, accounting for 4% of nonvariceal upper gastrointestinal bleeding and associated with acute or chronic occult bleeding that manifests as iron deficiency anemia.⁶ GAVE was first described by Rider *et al.* in 1953 and defined as watermelon stomach by Jabbari *et al.* in 1984 to describe the classic endoscopic appearance.⁶⁻⁸

There are two main forms of GAVE.^{6,9} The diffuse variety presents vascular ectasia extending from the proximal region of the stomach to the antrum with erythematous patches secondary of dilated vessels that are diffusely located and it is usually associated with cirrhosis and portal hypertension. The classic watermelon stomach presents with prominent erythematous streaks traversing the antrum. Non-cirrhotic patients are more likely to have classic watermelon stomach.⁶⁻⁹

The etiology of GAVE syndrome remains unknown and has been associated with several disease states, including autoimmune disease (e.g., systemic sclerosis, systemic lupus erythematosus, atrophic gastritis with pernicious anemia), renal failure, heart disease, liver cirrhosis and bone marrow transplantation.^{6,9-11}

In this patient some factors were discarded such as autoimmune disease, coagulopathy, evident inflammation, vitamin deficiency, hemolysis, liver or heart disease by physical examination and laboratory tests.

The diagnosis of GAVE is based on the clinical history and endoscopic appearance. Fibromuscular proliferation and capillary ectasia with microvascular thrombosis of the lamina propria form the histological hallmark of GAVE.^{9,10}

The histologic findings are not necessary to confirm the diagnosis but can be helpful. Westerhoff *et al.*¹² described immunohistochemical staining for

vascular markers CD31 and CD34 as well as the platelet maker CD61 to help highlight the increased mucosal microvessel density and microthrombi. This technique can be help to distinguish GAVE from portal hypertensive gastropathy when the endoscopy did not show typical appearance of GAVE.

The current patient has the classic form of GAVE (watermelon stomach) observed in the second endoscopy (Figures 1 and 2) and presents ESRD as predisposing factor to watermelon stomach, but she is younger than the patients previously reported which makes it an atypical case.

Watermelon stomach can be misinterpreted as erosive and hemorrhagic gastritis of the antrum as noted in the first endoscopy in this patient.¹⁰

Treatment for GAVE ranges from supportive therapy, medical therapy and endoscopic therapy to surgery.

Argon plasma coagulation (APC) has been successfully used in the treatment of both the striped and diffuse patterns of GAVE. APC is less expensive and with fewer side effects. As a result, it has largely as the first-line treatment for GAVE. Treatments are usually required on at least two occasions separated by six to eight weeks.¹³

Novitsky *et al.* observed in another study that is necessary surgical gastric resection as the only method to achieve cure and eliminate the bleeding, anemia and RBC transfusion dependence in failure of endoscopic therapy and recurrent episodes of gastrointestinal bleeding.⁹

However, based on experience reported in the literature for patients with GAVE undergoing therapy with APC appropriate monitoring is required. Every procedure in this situation should be carefully considered since surgical treatment typically involves gastric antrectomy, which, although effective are associated with significant morbidity and mortality, however, has an extremely limited role. Thus, in rebleeding, repeat endoscopy is useful and persistent failure of endoscopic treatment, the surgery is necessary.^{9,13}

We are doing follow-up with endoscopies and treatments with APC to control of bleeding in lesions that tend to recur that is a limitation to the treatment of anemia and resistance to rHuEPO in this patient. In persistent failure of endoscopic therapy will be performed surgical procedure.

In conclusion, GAVE (watermelon stomach) is an uncommon cause of bleeding and resistance to ESAs

in ESRD patient but curable. GAVE can be interpreted wrongly as refractory hemorrhagic antral gastritis. However, endoscopy is a method of diagnosis, monitoring and treatment in these patients, but surgical treatment should be considered for patients who do not respond to endoscopic therapy.

REFERENCES

1. Lau JH, Gangji AS, Rabbat CG, Brimble KS. Impact of haemoglobin and erythropoietin dose changes on mortality: a secondary analysis of results from a randomized anaemia management trial. *Nephrol Dial Transplant* 2010;25:4002-9. DOI: <http://dx.doi.org/10.1093/ndt/gfq330>
2. Gaweda AE, Goldsmith LJ, Brier ME, Aronoff GR. Iron, inflammation, dialysis adequacy, nutritional status, and hyperparathyroidism modify erythropoietic response. *Clin J Am Soc Nephrol* 2010;5:576-81. DOI: <http://dx.doi.org/10.2215/CJN.04710709>
3. Barretti P, Delgado AG. Atualização da Diretriz para o Tratamento da Anemia no Paciente com Doença Renal Crônica. *J Bras Nefrol* 2014;36:29-31.
4. Bregman R, Pecoits-Filho R. Atualização da Diretriz para o Tratamento da Anemia no Paciente com Doença Renal Crônica. *J Bras Nefrol* 2014;36:24-6.
5. Abreu PF, Romão Junior JE, Bastos MG. Atualização da Diretriz para o Tratamento da Anemia no Paciente com Doença Renal Crônica. *J Bras Nefrol* 2014; 36:18-22.
6. Dulai GS, Jensen DM, Kovacs TO, Gralnek IM, Jutabha R. Endoscopic treatment outcomes in watermelon stomach patients with and without portal hypertension. *Endoscopy* 2004;36:68-72. PMID: 14722858 DOI: <http://dx.doi.org/10.1055/s-2004-814112>
7. Jabbari M, Cherry R, Lough JO, Daly DS, Kinnear DG, Goresky CA. Gastric antral vascular ectasia: the watermelon stomach. *Gastroenterology* 1984;87:1165-70.
8. Pisharam JK, Ramaswami A, Chong VH, Tan J. Watermelon stomach: a rare cause of anemia in patients with end-stage renal disease. *Clin Nephrol* 2014;81:58-62. DOI: <http://dx.doi.org/10.5414/CN107527>
9. Novitsky YW, Kercher KW, Czerniach DR, Litwin DE. Watermelon stomach: pathophysiology, diagnosis, and management. *J Gastrointest Surg* 2003;7:652-61. DOI: [http://dx.doi.org/10.1016/S1091-255X\(02\)00435-3](http://dx.doi.org/10.1016/S1091-255X(02)00435-3)
10. Kar P, Mitra S, Resnick JM, Torbey CF. Gastric antral vascular ectasia: case report and review of the literature. *Clin Med Res* 2013;11:80-5. DOI: <http://dx.doi.org/10.3121/cmr.2012.1036>
11. Stefanidis I, Liakopoulos V, Kapsoritakis AN, Ioannidis I, Eleftheriadis T, Mertens PR, et al. Gastric antral vascular ectasia (watermelon stomach) in patients with ESRD. *Am J Kidney Dis* 2006;47:e77-82. PMID: 16731286 DOI: <http://dx.doi.org/10.1053/j.ajkd.2006.02.185>
12. Westerhoff M, Tretiakova M, Hovan L, Miller J, Noffsinger A, Hart J. CD61, CD31, and CD34 improve diagnostic accuracy in gastric antral vascular ectasia and portal hypertensive gastropathy: An immunohistochemical and digital morphometric study. *Am J Surg Pathol* 2010;34:494-501. PMID: 20351488 DOI: <http://dx.doi.org/10.1097/PAS.0b013e3181d38f0a>
13. Rosenfeld G, Enns R. Argon photocoagulation in the treatment of gastric antral vascular ectasia and radiation proctitis. *Can J Gastroenterol* 2009;23:801-4.