

# Cystadenoma in a pediatric patient: a rare salivary gland neoplasm

## *Cistadenoma em paciente pediátrico: uma rara neoplasia de glândula salivar*

Glória Maria França; Wesley R. Silva; Cristianne K. Medeiros; Joaquim Felipe Junior; Adriano R. Germano; Hébel C. Galvão

Universidade Federal do Rio Grande do Norte (UFRN), Natal, Rio Grande do Norte, Brazil.

### ABSTRACT

Salivary gland cystadenoma is a rare benign neoplasm, representing 1.4% of all benign salivary gland tumors. It presents a predilection for the major salivary gland and middle-aged or elderly adults. The present study reports a rare case of cystadenoma in the floor of the mouth a 5-year-old male patient, who was referred to an oral diagnosis center for evaluation of the lesion. After performing an incisional biopsy, microscopic analysis revealed a cystadenoma. The patient's treatment was excision of the lesion and he has been under follow-up for one year with no signs of recurrence.

**Key words:** oral pathology; salivary glands; neoplasms; cystadenoma.

### RESUMO

*O cistadenoma de glândula salivar é uma neoplasia benigna rara; representa 1,4% de todos os tumores benignos de glândula salivar. Apresenta predileção pela glândula salivar maior e por adultos de meia idade ou idosos. O presente estudo relata um caso raro de cistadenoma em assoalho bucal de um paciente do sexo masculino, 5 anos de idade, que foi encaminhado a um centro de diagnóstico oral para avaliação da lesão. Após realização de biópsia incisional, a análise microscópica revelou um cistadenoma. O tratamento do paciente foi a excisão da lesão, e ele se encontra em acompanhamento há um ano sem sinais de recidiva.*

*Unitermos:* patologia bucal; glândulas salivares; neoplasias; cistadenoma.

### RESUMEN

*El cistoadenoma de las glándulas salivales es una neoplasia benigna rara, responsable del 1,4% de todos los tumores benignos de las glándulas salivales. Tiene predilección por la glándula salival mayor y los adultos de mediana edad o ancianos. El presente estudio reporta un caso raro de cistoadenoma en piso de la cavidad oral de un paciente masculino de 5 años, quien fue derivado a un centro de diagnóstico oral para evaluación de la lesión. Después de realizar una biopsia incisional, el análisis microscópico reveló un cistoadenoma. El paciente fue tratado con la escisión de la lesión y ha sido seguido durante un año sin signos de recidiva.*

*Palabras clave:* patología bucal; glándulas salivales; neoplasias; cistoadenoma.

## INTRODUCTION

Cystadenoma of the salivary gland is a rare benign neoplasm<sup>(1-3)</sup>; it represents 1.4% of all benign salivary gland tumors and 2%-4,7% of all minor salivary gland tumors<sup>(3-5)</sup>. Clinically, it tends to manifest as a painless swelling<sup>(2,6)</sup>. The parotid is the most affected site (45%-50%), followed by the lip, the cheek mucosa, and the palate<sup>(1, 2, 7, 8)</sup>. It has a predilection for middle-aged or elderly adults and is rare in pediatric patients<sup>(1,9)</sup>.

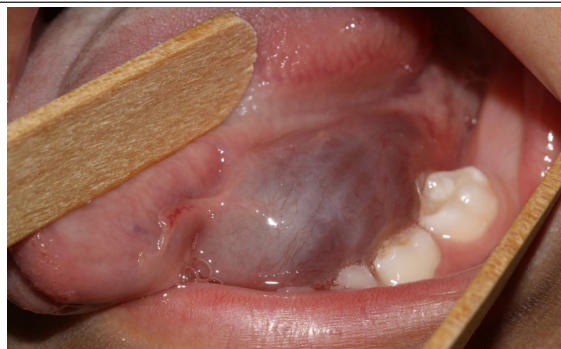
Histologically, cystadenoma is characterized by its multicystic nature; it is typically lined by a proliferative epithelium, often papillary and oncocytic. The tumor is usually formed by a double layer epithelium, in which the luminal cells are columnar and the basal cells are cuboidal. It is a Warthin tumor-like lesion; however, the characteristic lymphoid component is lacking<sup>(2, 8)</sup>. Surgical excision is required for treatment, and recurrence is rare<sup>(2,6,10)</sup>.

The present study aimed to report a rare case of cystadenoma on the floor of the mouth in a pediatric patient and to describe the main histologic features of this lesion.

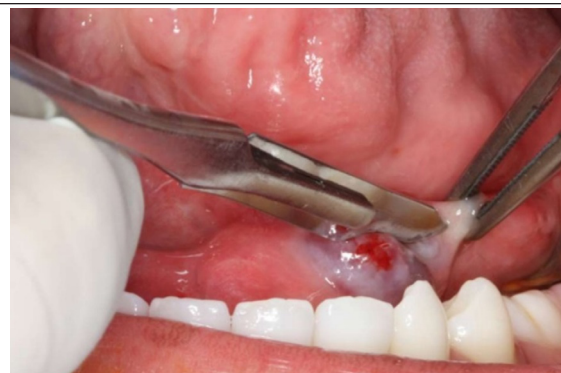## CASE REPORT

A 5-year-old male patient was referred to the Stomatology service at the Universidade Federal do Rio Grande do Norte, Brazil, due to the presence of a swelling on the floor of the mouth. During the anamnesis, the person responsible for the patient reported the increased volume as the main complaint, lasting two months. On the extraoral examination, the patient presented facial symmetry and normal mouth opening. During the intraoral examination, we observed the presence of a 1 cm diameter bubble, with a soft consistency, asymptomatic with a purplish color (**Figure 1**). From these analyzes, the clinical diagnosis of ranula was issued, and marsupialization and incisional biopsy of the lesion were performed (**Figure 2**).

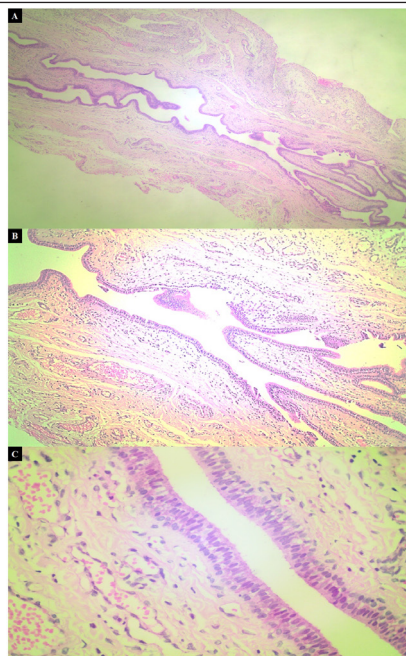
Microscopic analysis of specimens stained with hematoxylin and eosin (HE) showed a well-circumscribed lesion – with luminal columnar and non-luminal cuboidal cells – with multiple cystic compartments of varying size, lined with a double layer of oncocytic epithelium pattern. A pattern of papillary growth was also observed in some areas of the neoplasm. No cell atypia or mitosis figures were observed, indicating the benign character of the tumor. The capsule and stroma of the lesion consisted of dense fibrous connective tissue with numerous blood vessels (**Figure 3**), thus enabling the cystadenoma diagnosis.



**FIGURE 1** – Clinical presentation of cystadenoma; purple-colored lesion on the floor of the mouth



**FIGURE 2** – Performing a surgical procedure, with the purpose of marsupialization of the lesion and removal of tissue (biopsy) for histopathological analysis



**FIGURE 3** – Morphological characterization of the lesion

*A) lower amplification, showing multiple cystic spaces; B) intraluminal papillary projections, with dense fibrous support tissue; C) lined by a double layer of epithelium, showing an oncocytic pattern, with luminal columnar cells and non-luminal cuboidal cells.*

After the diagnosis of benign salivary gland neoplasia, the patient underwent a new surgical procedure under local anesthesia, incision in the sublingual region, blunt dissection of the muscular planes, and complete enucleation of the lesion were performed. The collected material was sent for histological analysis, and the result confirmed the previous diagnosis. The postoperative period occurred with no complications, and the patient has been in follow-up for one year, with no signs of recurrence.

## DISCUSSION

---

Cystadenoma is a benign, slow-growing, painless neoplasm that can develop in the major and minor salivary glands; but the main gland affected is the parotid<sup>(11-13)</sup>. In the oral cavity, the site most affected by this neoplasm is the lip<sup>(7,8)</sup>. There are other regions in which the lesion can be identified less frequently, as observed in the present report, in which the cystadenoma was located on the floor of the mouth.

Other reports found in the literature report data regarding the sex and age of patients diagnosed with cystadenoma, since this lesion is more frequent in female individuals over 40 years of age – at diagnosis –, ranging from 12 to 91 years of age<sup>(1, 4, 14, 15)</sup>. The patient in our case differs from the data previously mentioned, as the cystadenoma was diagnosed in a 5-year-old male child. This fact indicates that this neoplasm may have been due to some disturbance that occurred during the development of glandular tissue.

Concerning the clinical findings, it is very common to diagnose this type of benign neoplasm as mucocele<sup>(8)</sup>, when present in the region of the minor salivary gland, due to the clinical similarities between this lesion and cystadenoma. Therefore, it is necessary to perform a biopsy for microscopic analysis to diagnose and treat these lesions properly. Due to the location on the floor of the mouth and the clinical presentation of the lesion that the patient in this report presented, such as a purple-colored and softened consistency, an initial clinical diagnosis of ranula was issued.

Histologically, cystadenoma presents as a circumscribed lesion, sometimes surrounded by a fibrous capsule, in which the presence of multiple cystic spaces lined by epithelium, ranging from columnar to cuboidal, separated by fibrous connective tissue is observed<sup>(4, 7, 15)</sup>. In addition to these characteristics, we can find in the cystadenoma a papillary growth pattern and several cell types in the epithelial lining, such as oncocytic, mucous, and squamous cells, without the presence of atypia<sup>(4, 8)</sup>. The histopathology observed in this report confirms the features highlighted in the literature since it was observed the presence of multiple cystic areas lined by a double layer of oncocytic cells without the presence of lymphoid tissue.

Despite the benign characteristics of cystadenoma, surgical excision is still the most common primary treatment for this type of neoplasia. Furthermore, cystadenoma have a good prognosis, and cases of recurrence are rare<sup>(2, 6-8, 10)</sup>. However, we emphasize that recurrent cystadenoma are more frequent in the major salivary glands than in the minor ones. This fact may be a consequence of the incomplete removal of the lesion and the permanence of neoplastic cells in the remaining tissue since most of this type of neoplasia does not have a fibrous capsule delimiting the lesion<sup>(8, 10)</sup>. Thus, patients diagnosed with cystadenoma should be monitored periodically, even after the complete removal of the lesion, as in the case our patient, who has been in follow-up for a year showing no signs of recurrence.

Therefore, we emphasize that the knowledge of the clinical characteristics and the prevalence of salivary gland lesions, as well as the performance of imaging tests and biopsies, are essential for the final diagnosis and the appropriate treatment plan for these lesions, whether benign or malignant.

## CONCLUSION

---

According to the literature review, we conclude that cystadenoma is an uncommon salivary gland neoplasm. The onset of the lesion on the floor of the mouth in a 5-year-old patient makes the clinical case even rarer.

## REFERENCES

---

1. Tjioe KC, de Lima HG, Thompson LD, Lara VS, Damante JH, de Oliveira-Santos C. Papillary cyst adenoma of minor salivary glands: report of 11 cases and review of the English literature. *Head Neck Pathol.* 2015; 9(3): 354-9.
2. Goto M, Ohnishi Y, Shoji Y, Wato M, Kakudo K. Papillary oncocytic cystadenoma of a palatal minor salivary gland: a case report. *Oncol Lett.* 2016; 11(2): 1220-2.
3. Wu WJ, Huang MW, Gao Y, Zhang Med JG. Cyst adenoma of minor salivary gland with cervical metastasis: benign or malignant? *J Oral Maxillofac Surg.* 2018; 76(3): 670-5.

4. Lim CS, Ngu I, Collins AP, McKellar GM. Papillary cyst adenoma of a minor salivary gland: report of a case involving cytological analysis and review of the literature. *Oral Surg Oral Med Oral Pathol Oral Radiol Endod.* 2008; 105(1): e28-33.
5. Israrel Y, Rachmiel A, Ziv G, Nagler R. Benign and malignant salivary gland tumors - clinical and demographic characteristics. *Anticancer Res.* 2016; 36(8): 4151-4.
6. Bezić J, Glavina-Durdov M. salivary oncocytic cyst adenoma with intraluminal crystalloids: a case report with review of the literature. *Head Neck Pathol.* 2011; 5(4): 419-22.
7. Mahmood H, Murphy C, Oktseoglou V. Cyst adenoma of the mandible: a rare presentation. *Br J Oral Maxillofac Surg.* 2018; 56(6): 540-2.
8. Hellquist H, Paiva-Correia A, Poorten W, et al. Analysis of the clinical relevance of histological classification of benign epithelial salivary tumours. *Adv Ther.* 2019; 36(8): 1950-74.
9. Silva LP, Serpa MS, Viveiros SK, et al. Salivary gland tumors in a Brazilian population: a 20-years retrospective and multicenter study of 2292 cases. *J Craniomaxillofac Surg.* 2018; 46(12): 2227-33.
10. Wang L, Zhang S, Ma Y, Ha PK, Wang Z. Papillary cyst adenoma of the parotid gland: a case report. *World J Clin Cases.* 2019; 7(3): 366-72.
11. Tian Z, Li L, Wang L, Hu Y, Li J. Salivary gland neoplasms in oral and maxillofacial regions: a 23-year retrospective study of 6982 cases in an eastern Chinese population. *Int J Maxillofac Surg.* 2010; 39(3): 235-42.
12. Lukšić I, Virag M, Manojlović S, Macan D. Salivary gland tumours: 25 years of experience from a single institution in Croatia. *J Craniomaxillofac Surg.* 2012; 40(3): e75-e81.
13. Shen SY, Wang WH, Lian R, Pan GQ, Qian YM. Clinicopathologic analysis of 2736 salivary gland cases over a 11-year period in Southwest China. *Acta Otolaryngol.* 2018; 138(8): 746-9.
14. Buchner A, Merrell PW, Carpenter WM. Frequência relativa de tumores intraorais de glândula salivar menor: um estudo de 380 casos do norte da Califórnia e comparação com relatos de outras partes do mundo. *J Oral Pathol Med.* 2007; 36: 207-14.
15. Val-Bernal JF, Mayorga MM, Martín-Soler P, Obeso S, Alonso-Fernández EM, López-Rasines G. Synchronous Warthin tumor and papillary oncocytic cystadenoma in the ipsilateral parotid gland: an unreported association. *Rom J Morphol Embryol.* 2019; 60(3): 993-1002.

---

**CORRESPONDING AUTHOR**

Wesley Rodrigues Silva  0000-0002-0430-4656  
e-mail: wesleyrodriguesilva@gmail.com



This is an open-access article distributed under the terms of the Creative Commons Attribution License.