

# Evans syndrome in male lupus patient: case report

## *Síndrome de Evans em paciente lúpico do sexo masculino: relato de caso*

Barbara F. Dalmaso; Afonso José P. Cortez; Maitê Alexandra E. Velasquez; Warlindo C. Silva Neto; Flávio Aparecido R. Silva; Lívia Mara S. Sousa

Universidade Santo Amaro São Paulo, São Paulo, Brazil.

### ABSTRACT

Evans syndrome (ES) is a rare autoimmune disease of unknown etiology. ES occurs when there is a combination of autoimmune hemolytic anemia (AIHA) with thrombocytopenia, whether or not accompanied by immune neutropenia. This syndrome fits into a special variable type of warm AHAI and may be related to rheumatic diseases, such as systemic lupus erythematosus (SLE). Its pathogenesis is still far away to be fully understood. Direct Coombs test results are positive in 98% of cases. ES treatment is required when the anemia due to hemolysis is intense, and corticotherapy is recommended initially. In refractory cases, splenectomy or rituximab therapy, as well as other immunosuppressants, such as azathioprine, may be used. In this study, we present the case of a 45-year-old patient, male, who was diagnosed with ES associated with active SLE. The patient was admitted to the emergency room presenting severe hemolytic anemia and onset of thrombocytopenia. He was treated with intravenous corticosteroid therapy, followed by azathioprine.

**Key words:** systemic lupus erythematosus; hemolytic autoimmune anemia; thrombocytopenia.

### RESUMO

*A síndrome de Evans (SE) é uma doença autoimune rara de etiologia desconhecida; ocorre quando há combinação de anemia hemolítica autoimune (AHAI) com trombocitopenia, acompanhada ou não de neutropenia imune. Essa síndrome se enquadra em um tipo variável especial da AHAI a quente, podendo se relacionar com doenças reumatológicas, como lúpus eritematoso sistêmico (LES). Sua patogênese ainda é complexa. O Coombs direto é positivo em 98% dos casos. O tratamento da SE é necessário quando a anemia secundária à hemólise é intensa, sendo indicado inicialmente o uso de corticosteroides. Em casos refratários, pode-se optar pela esplenectomia ou terapia com rituximab, além de outros imunossupressores, como a azatioprina. Neste trabalho, relatamos o caso de um paciente de 45 anos, sexo masculino, com diagnóstico de SE associada a LES ativo. Foi admitido no pronto-socorro com quadro de anemia hemolítica severa e surgimento de plaquetopenia. O paciente foi tratado com corticoterapia intravenosa, seguida de azatioprina.*

**Unitermos:** lúpus eritematoso sistêmico; anemia hemolítica autoimune; trombocitopenia.

### RESUMEN

*El síndrome de Evans (SE) es una enfermedad autoinmune rara de etiología desconocida; ocurre cuando hay combinación de anemia hemolítica autoinmune (AHAI) con trombocitopenia, acompañada o no de neutropenia inmune. Ese síndrome es un tipo variable especial de AHAI por anticuerpos calientes que puede se relacionar a enfermedades reumatológicas, como el lupus eritematoso sistêmico (LES). Su patogénesis es aún compleja. La prueba de Coombs directa es positiva en 98% de los casos. El tratamiento del SE es necesario cuando la anemia secundaria a hemólisis es intensa, siendo indicado inicialmente el uso de corticosteroides. En casos refractarios se recomienda una esplenectomía o terapia con rituximab, además de otros inmunosupresores,*

como la azatioprina. En este trabajo, reportamos el caso de un paciente de 45 años, varón, que tuvo el diagnóstico de SE asociado a LES activo. Él fue admitido en la sala de urgencias con cuadro de anemia hemolítica severa y plaquetopenia. Fue tratado con corticoides por vía intravenosa, seguidos de azatioprina.

**Palabras clave:** lupus eritematoso sistémico; anemia hemolítica autoinmune; trombocitopenia.

## INTRODUCTION

Evans syndrome (ES), first described in 1951, is a hemolytic anemia defined by the combination of, simultaneous or sequential, autoimmune hemolytic anemia (AIHA) and thrombocytopenia, with or without immune neutropenia in the absence of underlying etiology<sup>(1)</sup>.

Although the syndrome was first considered to be an “idiopathic” disease and, therefore, regarded as a diagnosis of exclusion, about half of the cases are associated with other pathologies or conditions, including infections [eg, hepatitis C virus (HCV) and human immunodeficiency virus (HIV)], systemic lupus erythematosus (SLE), common variable immunodeficiency, autoimmune lymphoproliferative syndrome, and other lymphoproliferative diseases<sup>(2)</sup>.

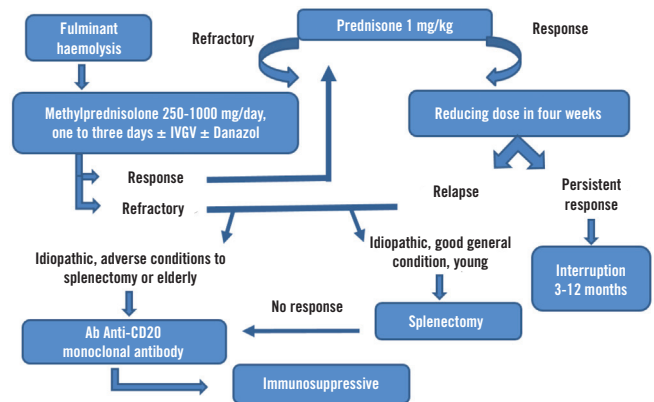
Its pathophysiology is of unknown origin, but is known to occur after a deep immune system disorder, as opposed to a coincidental combination of immunological cytopenia with onset of antibodies to red blood cells, platelets, and neutrophils<sup>(3)</sup>.

ES fits into a specific variable of AIHA, type warm. Its pathogenesis is still unclear and may include the role of the erythrocyte antigens and complement system itself, loss of antigen presentation effectiveness, and functional abnormalities of B and T cells. In 98% of cases, the warm antibodies are from the subclass of immunoglobulin G1 (IgG1) and react against antigens of the Rh system. Erythrocyte destruction is usually mediated by cells of the macrophage-monocyte system<sup>(3)</sup>.

Anemia is usually severe and characterized by the presence of spherocytes in the blood smear. There is evidence of increased production of red blood cells with erythroid hyperplasia in the bone marrow and nucleated red blood cells in the peripheral blood. The number of reticulocytes is markedly elevated and, almost always, there is leukocytosis. In general, the number of platelets in AIHA is normal or elevated, but in ES, immune thrombocytopenia is present<sup>(4)</sup>. Direct Coombs test is positive in 98% of cases of AIHA by warm antibody (**Figure 1**)<sup>(3)</sup>. Serum bilirubin is elevated, usually in the range of 2 to 4 mg/dl due

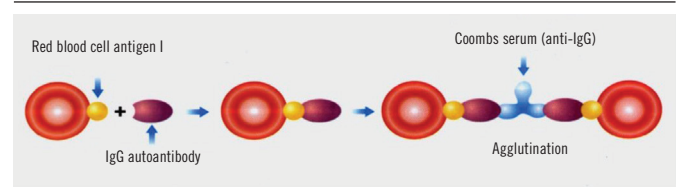
to the indirect bilirubin increase. Lactate dehydrogenase (LDH) increases and haptoglobin is normal, since haemolysis is extravascular<sup>(4)</sup>.

The ES develop with chronicity and relapses even with strict control, having a poor prognosis. Its management is still a challenge<sup>(5,6)</sup>. Corticosteroids are the first therapeutic line, and may occasionally induce remission of the disease, but exacerbations and recurrences may occur. Other treatment routes include intravenous immunoglobulins (IVIG), rituximab, splenectomy, cyclosporine or azathioprine (**Figure 2**)<sup>(6,7)</sup>.



**FIGURE 1** – Flowchart of warm AIHA treatment

AIHA: autoimmune haemolytic anemia; IVIG: intravenous immunoglobulins; Ab: antibody.



**FIGURE 2** – Direct Coombs test

Source: Zago MA, Pasquini R, Falcão RP (2013)<sup>(3)</sup>.

The direct Coombs test, performed to detect the presence of IgG antibodies on the surface of red cells, uses Coombs serum obtained by rabbits sensitized by human immunoglobulin (human IgG antibody). Complement fixation in red blood cells is detected by Coombs serum with anti-complement specificity.

IgG: immunoglobulin G class.

## CASE REPORT

A 45-year-old brown male patient, a living in São Paulo, Brazil, was admitted to the emergency room with severe symptomatic anemia, he remained hospitalized for 36 days. He denied previous comorbidities and had a family history of SLE (sister). He complained of paresthesia in upper and lower limbs, for one day, and dyspnea. He reported 5 kg weight loss in two months and adynamia; unmeasured fever associated with sweating at night. Presence of dry cough for about three years.

At screening, macrocytic anemia was evidenced (Table 1), with no signs of active bleeding. During physical examination, he presented normotensive, tachycardia (134 bpm), afebrile, with oxygen saturation of 95% in oxygen mask, tachypnea and body mass index (BMI) of 19 kg/m<sup>2</sup>. He was lucid, fully oriented, in a regular general health condition, pale (3+/4+), dehydrated (2+/4+), acyanotic, anicteric, with no meningeal signs or focal neurological deficits, with sensitivity and motor strength preserved; bilateral axillary and bilateral inguinal lymphadenopathy. Regular heartbeat, presence of aortic and mitral murmur. Absence of hepatomegaly or splenomegaly.

TABLE 1 – Laboratory tests (Sep 5, 2018)

Laboratory tests	Values	Reference value
Hemácias	0.95 10 <sup>6</sup> /µl	4.4-5.9 10 <sup>6</sup> /µl
Hb	3.7 mil/mm <sup>3</sup>	13-18 mil/mm <sup>3</sup>
Ht	10.8 g/dl	40-52 g/dl
MCV	113.7 fl	80-100 fl
MCH	38.9 pg	27-32 pg
MCHC	34.3 g/dl	32-37 g/dl
RDW	11.4%	Até 15%
Leukocytes	17.4/µl	3.500-11.000/µl
Rods	1%	1%-4%
Segmented	76%	48%-66%
Eosinophils	1%	1%-6%
Lymphocytes	16%	20%-30%
Platelets	157.000/µl	150.000-450.000/µl
CRP	1.62 mg/dl	≤ 0.3 mg/dl
GOT	105 U/l	15-37 U/l
GPT	30 U/l	6-45 U/l
Sodium	137 mEq/l	136-145 mEq/l
Potassium	3.9 mEq/l	3.5-5.1 mEq/l
Urea	34 mEq/l	15-40 mEq/l
Creatinine	0.96 mg/dl	0.5-1.3 mg/dl

Hb: hemoglobin; Ht: hematocrit; MCV: mean corpuscular volume; MCH: mean corpuscular hemoglobin; MCHC: mean corpuscular hemoglobin concentration; RDW: red cell distribution width; CRP: C-reactive protein; GOT: glutamic-oxalacetic transaminase enzyme; GPT: glutamate-pyruvate transaminase enzyme.

In the first days, six red blood cell concentrates were transfused. A computed tomography (CT) scan of the chest was performed, which revealed pulmonary fibrosis; the upper gastrointestinal endoscopy (UGIE) showed hydroseal distension of the distal esophagus. Markers for hemolysis (Table 2) were requested and resulted increased, positive direct Coombs test indicating AIHA. Viral serologies (Table 3), three sputum samples and cultures collected were negative, ruling out current infection. Subsequently, a myelogram was performed and presented as normal, and the transthoracic echocardiogram revealed a slight diffuse pericardial effusion. In addition to AIHA, thrombocytopenia appeared, which diagnosed ES.

During the hospital stay, the patient presented Raynaud's phenomenon in hands and there was an occurrence of oral ulceration. Rheumatological markers were requested, which

TABLE 2 – Hemolysis markers

	Sep 6, 2018	Sep 7, 2018	Reference value
TB/IB	1.73/0.95	1.65/0.99	1.2/< 0.9 mg/dl
Reticulocytes	-	3.2%	0.5%-20%
Haptoglobin	-	30	44-125 mg/dl
Hb Electrophoresis	-	Normal	0.1-2
LDH	1069	-	125-220 U/l
Direct Coombs	-	Positive	

TB: total bilirubin; IB: indirect bilirubin; Hb: hemoglobin; LDH: lactic dehydrogenase.

TABLE 3 – Viral serologies

	Sep 6, 2018	Sep 7, 2018	Sep 12, 2018	Sep 18, 2018
HIV 1 and 2 rapid antibody test	Negative			
VDRL	Negative			
Hepatitis A IgG/IgM	Reactive/NR			
HbsAg	Negative			
Anti-HBs	Positive			
Anti-HBV IgG/IgM	NR			
Anti-HCV	Negative			
Serologic test for Leptospirosis		Negative		
Serologic test for Paracoccidioidomycosis			Negative	
Serologic test for histoplasmosis			Negative	
Varicella IgG/IgM				NR/NR
Adenovirus IgG/IgM				NR/NR
ASLO				Negative
Epstein-Barr virus IgG/IgM				Reactive/NR
HTLV 1/2				NR

VDRL: Venereal Disease Research Laboratory; IgG: immunoglobulin G; IgM: immunoglobulin M; HbsAg: hepatitis B surface antigen; anti-HBs: hepatitis B surface antibody; HCV: hepatitis C virus; ASLO: antistreptolysin O; HTLV: human T-lymphotropic virus; NR: nonreactive.

showed positive antinuclear factor (ANF) (**Table 4**). It was also possible to diagnose active SLE due to the presence of clinical criteria (hemolytic anemia, thrombocytopenia, pericarditis and oral ulcers).

It was decided to administer prednisone 40 mg/day as a therapeutic test. After five days of medication, there was no satisfactory response, and methyl prednisolone 1 mg/kg/day was started for three days. After pulse therapy, there was clinical improvement, but thrombocytopenia persisted (**Table 5**).

**TABLE 4 – Markers for rheumatologic tests**

	Sep 20, 2018	Sep 22, 2018	Reference value
RF	51.6		< 30 UI/ml
Anti-RNP	240		Reactive: > 10
ESR	153		Up to 10 mm/h
ANF		Nuclear dots pattern 1/640	
C3	68		82-185 mg/dl
C4	11		15-56 mg/dl
IgM	570		22-240 mg/dl

RF: rheumatoid factor; anti-RNP: anti-ribonucleoprotein antibody; ESR: erythrocyte sedimentation rate; ANF: antinuclear factor; IgM: immunoglobulin M.

**TABLE 5 – Laboratory tests (Sep 6, 2018 to Oct 10, 2018)**

	Sep 6	Sep 7	Sep 22	Sep 26	Oct 20	Oct 10	Reference value
Hb	3.8	6.2	7	9.1	11.4	12.9	12-15 g/dl
Ht	16.6	15.2	18.1	25.1	36.1	38.2	37%-47%
Leukocytes	24.000	19.200	5.400	6.000	7.300	8.100	5-10 thousand/mm <sup>3</sup>
Rods	3	10	4	4	4	3	2%-4%
Platelets	132.000	95.000	18.000	11.000	31.000	90.000	130-450 thousand/mm <sup>3</sup>
CRP	58.3	41.5			1.1	8	< 5 mg/l
CPK	1481	886					30-200
GOT	95	46					5-34 U/l
GPT	35	28					Até 55 U/l
Sodium	138	140	136		139		136-146 mEq/l
Potassium	4.4	4.1	4.2		3.5		3.5-5.3 mEq/l
Cálcio iônico	1.16	1.14					1.12-1.32 mEq/l
Magnésio	2	1.9					1.6-2.6 mg/dl
Fósforo	2	2.6					2.3-4.7 mg/dl
Ureia	21	17			25		19-44 mg/dl
Creatinine	0.8	0.8			0.6		0.7-1.3 mg/dl
ALP	47	46					40-150 U/l
GGT	20	20					12-6.4 U/l
TP	8.58						6.4-8.3 g/dl
Albumina	2.8						3.5-5.2 g/dl

Hb: hemoglobin; Ht: hematocrit; CRP: C-reactive protein; CPK: creatinofosfoquinase; GOT: glutamic-oxalacetic transaminase enzyme; GPT: glutamate-pyruvate transaminase enzyme; ALP: alkaline phosphatase; GGT: gamma-glutamyl transferase; TP: total protein.

The patient was discharged and initiated rheumatologic disease outpatient follow-up. In February 2019 he started using azathioprine, obtaining stabilization of platelet levels and remaining without anemia.

## DISCUSSION

ES is diagnosed in only 0.8%-3.7% of all patients with idiopathic thrombocytopenic purpura and AIHA. Few data are available in the literature; the majority is from pediatric cases. Therefore, the characteristics and the treatment of ES in the adult are little-known<sup>(2)</sup>.

It is known that ES is a rare manifestation in SLE, identified in 2.7% dos of cases; usually occurs in patients with severe multisystem manifestations<sup>(1)</sup>. Treatment strategies frequently used for SLE contribute to greater likelihood of remission of the disease and fewer exacerbation than observed in the general population with ES<sup>(8)</sup>.

There is still no consensus on which laboratory tests and radiological procedures should be performed to search for an underlying disease. A minimum investigation is suggested with the following complementary exams, including CT of the chest, abdomen and pelvis: complete blood count, peripheral blood film, serum protein electrophoresis, serum immunoelectrophoresis (immunofixation), average serum levels of immunoglobulin, immunophenotyping of circulating B lymphocytes, titer of antinuclear antibody, deoxyribonucleic acid (anti-dsDNA), anticardiolipin, lupus anticoagulant, HIV, HCV and hepatitis B virus (HBV) tests and bone marrow aspirate/biopsy<sup>(9)</sup>.

There are no systemic or randomized studies on ES treatment, which remains a challenge. The therapeutic methods (besides glucocorticoids, IVIG and splenectomy) reported as successful in some patients were: rituximab, cyclophosphamide, mycophenolate mofetil, cyclosporine, vincristine, danazol, haematopoietic stem cell transplantation and azathioprine<sup>(6,8)</sup>.

## REFERENCES

---

1. Bshabshe A, Al-Shehri Hamdan, Assiri Ali, Jamil A. An unusual presentation of systemic lupus erythematosus as Evan syndrome: a case report and review literature. *Eur J Mol Clin Med* [Internet]. 2018; 5(1): 37-40. Available at: <https://www.ejmcm.com/articles/10.5334/ejmcm.256/>.
2. Kim JK, Facó MMM, Lotito APN, et al. Púrpura trombocitopênica e anemia hemolítica autoimune em pacientes internados com lúpus eritematoso sistêmico juvenil. *Rev Bras Reumatol*. 2007; 47(1): 10-5.
3. Zago MA, Pasquini R, Falcão RP. *Tratado de hematologia*. Atheneu; 2013. p. 239-47.
4. Azevedo MRA. *Hematologia básica*. 4 ed. Luana; 2008. p. 167-83.
5. Brito AA, Leite LAC, Martin RM, et al. Ocorrência simultânea de síndrome de Evans e anemia falciforme em uma criança de 2 anos. *J Bras Patol Med Lab*. 2012; 48(2): 101-4.
6. Schrier SL. Warm autoimmune hemolytic anemia: treatment. *UpToDate* [Internet]. 2018. Available at: [https://www.uptodate.com/contents/warm-autoimmune-hemolytic-anemia-clinical-features-and-diagnosis?search=sindrome%20de%20evans&source=search\\_result&selectedTitle=2~44&usage\\_type=default&display\\_rank=2](https://www.uptodate.com/contents/warm-autoimmune-hemolytic-anemia-clinical-features-and-diagnosis?search=sindrome%20de%20evans&source=search_result&selectedTitle=2~44&usage_type=default&display_rank=2).
7. Schrier SL, Brugnara C. Pathogenesis of autoimmune hemolytic anemia: warm agglutinins and drugs. *UpToDate* [Internet]. 2018. Available at: [https://www.uptodate.com/contents/pathogenesis-of-autoimmune-hemolytic-anemia-warm-agglutinins-and-drugs?search=anemia%20hemolitica%20autoimune&source=search\\_result&selectedTitle=4~150&usage\\_type=default&display\\_rank=4](https://www.uptodate.com/contents/pathogenesis-of-autoimmune-hemolytic-anemia-warm-agglutinins-and-drugs?search=anemia%20hemolitica%20autoimune&source=search_result&selectedTitle=4~150&usage_type=default&display_rank=4).
8. Michel M, Chanet V, Dechartres A, et al. The spectrum of Evans syndrome in adults: new insight into the disease based on the analysis of 68 cases. *Blood* [Internet]. 2009; 114: 3167-3172. Available at: <http://www.bloodjournal.org/content/114/15/3167?sso-checked=true>.
9. Hanafy E, Alanazi K, Alanazi M, Alanazi E, Faisal N, Mahmoud G. A case of Evans syndrome associated with autoimmune thyroiditis. *Hematol Transfus Int J*. 2018; 6(4): 151-3.

---

## CORRESPONDING AUTHOR

Barbara Ferraço Dalmaso  0000-0003-1311-3496  
e-mail: [babi\\_dalmaso@hotmail.com](mailto:babi_dalmaso@hotmail.com)



This is an open-access article distributed under the terms of the Creative Commons Attribution License.