

Inflammatory myofibroblastic tumour arising incidentally as a polypoid lesion in the gallbladder

Tumor miofibroblástico inflamatório surgindo incidentalmente como lesão polipoide na vesícula biliar

Carlos Filipe C. Abrantes¹; Mário Rui Silva¹; Rui Caetano Oliveira¹; Catarina Eloy²; Maria Augusta Cipriano¹; Lúgia P. Castro¹

1. Centro Hospitalar e Universitário de Coimbra. 2. Instituto de Patologia e Imunologia Molecular da Universidade do Porto (IPATIMUP).

ABSTRACT

Inflammatory myofibroblastic tumour (IMT) is a rare mesenchymal neoplasm that usually originates from abdominal soft tissues. A female patient aged 50 years presented with a 1.2 cm gallbladder polyp. The microscopic study showed spindle cell proliferation in an edematous background rich in lymphocytes and plasma cells. Immunohistochemistry showed positivity for vimentin, smooth muscle actin, and anaplastic lymphoma kinase (ALK), and negativity for other markers. Fluorescent *in situ* hybridization (FISH) revealed *ALK* gene rearrangement. The diagnosis was IMT of the gallbladder, a unique case considering that it was identified at the early stage of development of these neoplasms.

Key words: gallbladder; soft tissue neoplasms; polyps.

INTRODUCTION

Inflammatory myofibroblastic tumour (IMT) is a rare mesenchymal neoplasm composed of myofibroblastic and fibroblastic spindle cells accompanied by an inflammatory infiltrate of plasma cells, lymphocytes, and/or eosinophils⁽¹⁾. It has been described, among other names, as inflammatory pseudotumor or plasma cell granuloma, but the designation of IMT was adopted by the 2013 World Health Organization (WHO) Classification of Tumours of the Soft Tissue and Bone⁽¹⁾. It has been sometimes mistaken for immunoglobulin G4 subclass (IgG4) related sclerosing disease; however, IMT is clinically and pathologically distinct⁽¹⁻³⁾. Expression of anaplastic lymphoma kinase (ALK) by immunohistochemistry is identified in 50%-60% of cases, and correlates well with the presence of *ALK* gene rearrangement⁽¹⁾. The clonal presence of this alteration has been very useful in classifying IMT as a distinct entity, as well as a true neoplasm^(1,4-6).

IMT primarily affects children and young adults, with mean age of 10 years, although the age range stretches throughout adulthood⁽¹⁾. It can arise in any organ, but occurs most frequently in the mesentery, omentum, retroperitoneum, pelvis, and abdominal soft tissues⁽¹⁾.

Gastrointestinal locations are unusual^(1,7), and regarding primary IMT of the gallbladder, only a few well documented and convincing cases can be found in the literature⁽⁸⁻¹¹⁾, all of them describing large lesions. In this report, we describe a unique case of primary IMT of the gallbladder, considering that it was diagnosed at the early stage of development of these neoplasms.

CASE REPORT

Clinical data

A 50-year-old female patient, with no previously known diseases, presented with a gallbladder polypoid lesion on a routine abdominal ultrasound, identified as hypervascular by Doppler study. A laparoscopic cholecystectomy was carried out.

Macroscopic examination

Gross examination showed a sessile polyp on the gallbladder, measuring 1.2 cm, with regular surface and yellow cut section (**Figure 1A**).

Microscopic examination

Microscopic study showed spindle cell proliferation with eosinophilic cytoplasm and oval nuclei with small nucleoli, in a slightly oedematous background rich in lymphocytes and plasma cells (**Figures 1B, 1C, and 1D**).

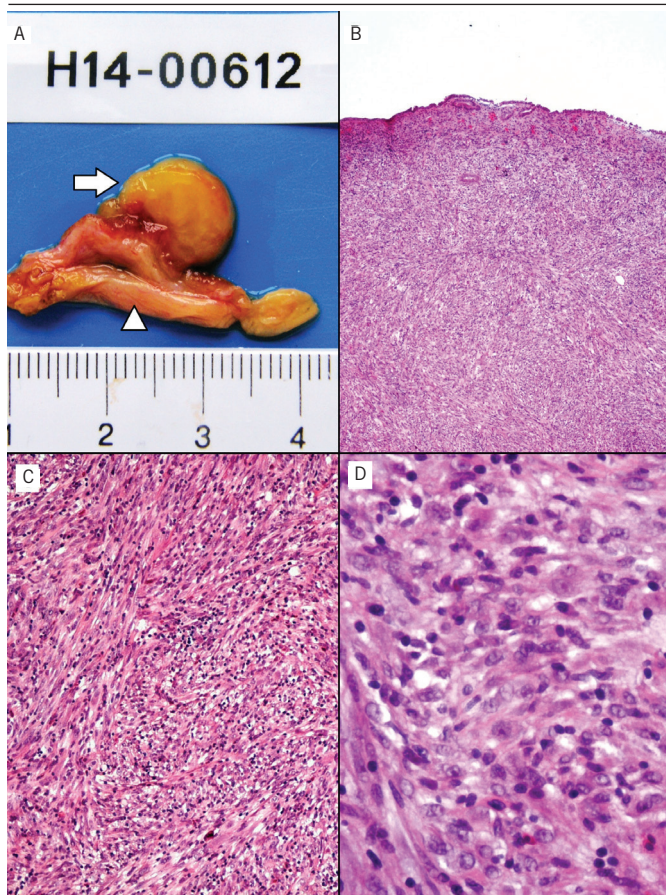


FIGURE 1 – Gross and microscopic examination: pathological findings of inflammatory myofibroblastic tumour

A) polypoid lesion (arrow) arising from the gallbladder wall (arrowhead), with 1.2 cm and yellowish cut section (macroscopic photograph); B) the lesion is located below gallbladder epithelium (HE stain, 40×); C) neoplastic spindle cell proliferation in a slightly oedematous background, rich in lymphocytes and plasma cells (HE stain, 100×); D) the neoplastic cells had eosinophilic cytoplasm and oval nuclei with small nucleoli (HE stain, 400×).

HE: hematoxylin and eosin.

Immunohistochemistry and fluorescent *in situ* hybridization (FISH)

The characteristics of the antibodies used for the immunohistochemistry study are summarized in **Table**. Studies were performed on one representative block of the lesion, resorting to the avidin-biotin-peroxidase complex detection system and performed on a Ventana Marker Platform Bench Mark ULTRA IHC/ISH.

TABLE – Characteristics of antibodies used on the immunohistochemistry study

Antigen	Clone	Dilution	Antigen retrieval	Source	Detection system	Results
Vimentin	V9	1:200	Ultra CC1	DAKO	Ultraview DAB Ventana	Positive (antigen expression)
ALK	ALK 01	Ready to use	Ultra CC1	Ventana Medical System	Ultraview DAB Ventana	Positive (antigen expression)
Pan-cytokeratin	AE1/AE3 and PCK26	Ready to use	Ultra CC1	Ventana Medical System	Ultraview DAB Ventana	Negative (no antigen expression)
CD117 (C-kit)	9.7	Ready to use	Ultra CC1	Ventana Medical System	Ultraview DAB Ventana	Negative (no antigen expression)
SMA	1A4	1:200	Ultra CC1	Cell Marque	Ultraview DAB Ventana	Positive (antigen expression)
Desmin	D33	1:50	Ultra CC1	DAKO	Ultraview DAB Ventana	Negative (no antigen expression)
Caldesmon	h-CD	1:50	Ultra CC1	DAKO	Ultraview DAB Ventana	Negative (no antigen expression)
CD30	Ber-H2	Ready to use	Ultra CC1	Ventana Medical System	Ultraview DAB Ventana	Negative (no antigen expression)
CD68	KP-1	Ready to use	Ultra CC1	Ventana Medical System	Ultraview DAB Ventana	Negative (no antigen expression)
Melanosome	HMB45	Ready to use	Ultra CC1	Ventana Medical System	Ultraview DAB Ventana	Negative (no antigen expression)
S100	4C4.9	Ready to use	Ultra CC1	Ventana Medical System	Ultraview DAB Ventana	Negative (no antigen expression)
CD34	Qbend/10	1:50	Ultra CC1	DAKO	Ultraview DAB Ventana	Negative (no antigen expression)
NF	2F 11	1:100	Ultra CC	DAKO	Ultraview DAB Ventana	Negative (no antigen expression)

ALK: anaplastic lymphoma kinase; CC1: cell conditioning 1; DAB: diaminobenzidine; h-CD: anti-human-caldesmon; HMB45: human melanoma black; NF: neurofilament; SMA: smooth muscle actin.

Immunohistochemically, the neoplastic cells displayed diffuse positivity for vimentin, smooth muscle actin (SMA) and ALK (**Figures 2A, 2B and 3A**). Stains were negative for pan-keratin AE1/AE3, cluster of differentiation (CD) 117 (C-kit), S100-protein, caldesmon, desmin, human melanoma black (HMB45), neurofilament (NF), CD68, CD34, and CD30 (**Figures 2C and 2D**).

The genetic study of the *ALK* gene rearrangements was performed with FISH using the Vysis LSI ALK Dual Colour Break

Apart Rearrangement Probe (Abbott Molecular, Abbott Park, IL); this probe hybridizes to the chromosomal region of the *ALK* gene (2p23) in the telomeric extremity (3') with Spectrum Orange (red) and centromeric extremity (5') with Spectrum Green (green).

FISH study revealed *ALK* gene rearrangement in 26 (52%) of 50 neoplastic cells studied (**Figure 3B**).

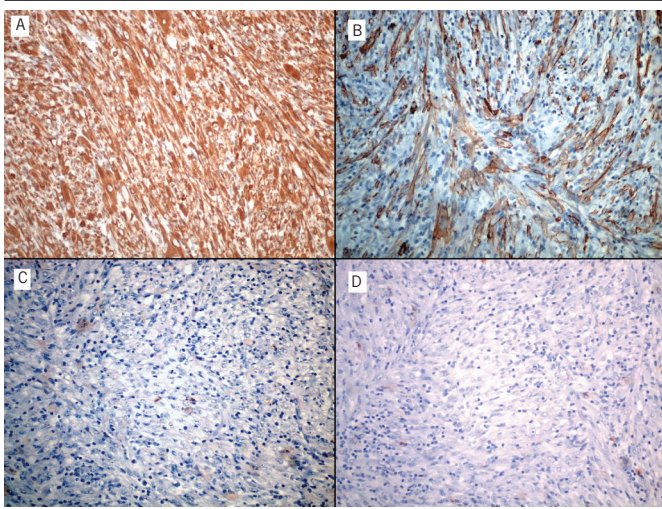


FIGURE 2 – Immunohistochemistry results

The neoplastic cells showed positive staining for vimentin (A) and smooth muscle actin (B), and negative staining for pan-cytokeratin AE1/AE3 (C) and CD117 (D). All images were captured at 200× magnification.

Diagnosis

The tumour was diagnosed as primary IMT of the gallbladder, associated with *ALK* gene rearrangement.

DISCUSSION

IMT is a rare mesenchymal neoplasm, with a very limited number of cases of primary of the gallbladder reported in the literature⁽⁸⁻¹¹⁾.

The site of origin determines the symptoms and the abdominal tumours are known for causing gastrointestinal obstruction⁽¹⁾. Up to one third of the patients present clinical syndrome of fever, malaise, weight loss, and laboratory abnormalities that disappear after mass excision^(1, 6, 12). In our case, the patient was asymptomatic and the tumour was detected during a routine abdominal ultrasound.

Grossly, IMT is usually a nodular, circumscribed or multinodular mass, with a tan, whorled, fleshy or myxoid cut

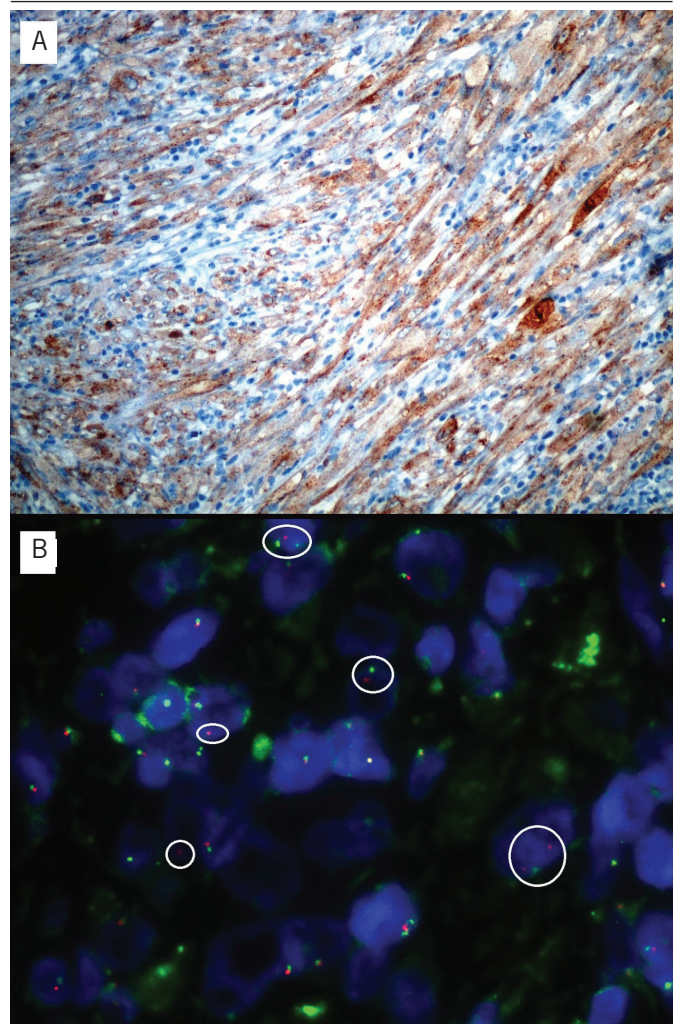


FIGURE 3 – Immunohistochemistry and FISH for *ALK*

A) the neoplastic cells showed a cytoplasmic granular staining for *ALK*, 200×; B) FISH revealed rearrangement of *ALK* gene in 52% of the neoplastic cells studied, characterized by separation of the telomeric (red) and centromeric (green) signals of the *ALK* break-apart probe used.

FISH: fluorescent in situ hybridization; *ALK*: anaplastic lymphoma kinase.

surface appearance, with variable hemorrhage, calcification or necrosis; it can measure between 1 cm and 20 cm^(1, 6).

Histologically, the neoplastic cells form three basic patterns^(1, 6, 12). The first closely mimics a reactive process similar to granulation tissue, characterized by loosely arranged plump or spindle myofibroblasts in an oedematous background with abundant blood vessels and an infiltrate of plasma cells, lymphocytes and eosinophils^(1, 6, 12). The second pattern, in which our case is included, consists of a more compact spindle cell proliferation with variable myxoid and collagenized stroma accompanied by the same inflammatory infiltrate^(1, 6, 12). However,

we did not observe ganglion-like myofibroblastic cells, described as frequent in this pattern. The third pattern consists of a scar-like proliferation with dense collagen fibers, low myofibroblastic cellularity and sparse inflammatory infiltrate^(1,6,12).

This tumour shows positivity for vimentin and variable staining for SMA, muscle specific actin (HHF35) and desmin^(1,6). Focal keratin expression can be identified, as well as CD68 in histiocytic-appearing cells⁽¹⁾. Cytoplasmic expression of ALK is present in 50%-60% of cases and correlates well with the presence of *ALK* gene rearrangement⁽¹⁾, as seen in our case.

IMTs are genetically heterogeneous, probably because of the different entities grouped in this category⁽¹⁾. *ALK* gene rearrangements are more uncommon in patients above 40 years⁽¹⁾, making this case even more unusual due to the presence of this rearrangement. The presence of clonal cytogenetic rearrangements has been a strong factor in classifying this entity as neoplastic rather than a reactive process^(1,5,6,13). The recurrence rate of extrapulmonary IMT can reach 25%, and is related to factors such

as anatomic site, resectability and multinodularity⁽¹⁾. Metastases are rare, generally occurring in less than 2% of cases⁽¹⁾. A more aggressive clinical behavior has been reported to be associated with the presence of round cell morphology with membrane or perinuclear pattern of ALK immunohistochemical staining and RANBP2-*ALK* rearrangement^(14,15) or with ALK-negative IMT^(6,16). However, especially in patients with intra-abdominal tumours, a benign behavior of ALK-negative IMT is observed, including spontaneous regression⁽¹⁷⁾.

Crizotinib (Xalkori[®], made by Pfizer, Inc.), a tyrosine kinase inhibitor approved by the Food and Drug Administration (FDA) for the treatment of advanced lung cancer with *ALK* rearrangements^(18,19), has been reported to be potentially useful in cases of aggressive IMT⁽²⁰⁾.

In our case, the excision was complete, due to the unique characteristics of this tumour regarding the small size and location within the gallbladder. The patient has been in clinical follow-up for 12 months, with no signs of recurrent disease.

RESUMO

Tumor miofibroblástico inflamatório (IMT) é uma neoplasia mesenquimatosa rara, geralmente com origem nos tecidos moles abdominais. Uma paciente do sexo feminino com 50 anos apresentou-se com pólipo da vesícula biliar com 1,2 cm. No estudo microscópico, observou-se proliferação de células fusiformes em fundo edematoso, rico em plasmócitos e linfócitos. Imuno-histoquimicamente, notou-se positividade para vimentina, actina músculo liso e cinase do linfoma anaplásico (ALK), com negatividade de outros marcadores. Observou-se rearranjo do gene ALK por hibridização fluorescente in situ (FISH). O diagnóstico foi IMT da vesícula biliar, um caso único, considerando que foi identificado no estadio inicial de desenvolvimento dessas neoplasias.

Unitermos: vesícula biliar; neoplasias de tecidos moles; pólipos.

REFERENCES

1. Coffin CM, Fletcher JA. Inflammatory myofibroblastic tumour. In: World Health Organization Classification of Tumours of Soft Tissue and Bone. 4th edition. Fletcher CDM, Bridge JA, Hogendoorn PCW, Mertens F, editors. Lyon: International Agency for Research on Cancer; 2013. p. 83-4.
2. Hidetaka Y, Hiroshi Y, Shinichi A, et al. Inflammatory myofibroblastic tumor versus IgG4-related sclerosing disease and inflammatory pseudotumor. *Am J Surg Pathol.* 2009 Sep; 33(9): 1330-40. PubMed PMID: 19718789.
3. Saab ST, Hornick JL, Fletcher CD, et al. IgG4 plasma cells in inflammatory myofibroblastic tumor: inflammatory marker or pathogenic link? *Mod Pathol.* 2011 Apr; 24(4): 606-12. PubMed PMID: 21297584.
4. Cook JR, Dehner LP, Collins MH, et al. Anaplastic lymphoma kinase (ALK) expression in the inflammatory myofibroblastic tumor: a comparative immunohistochemical study. *Am J Surg Pathol.* 2001 Nov; 25(11): 1364-71. PubMed PMID: 11684952.
5. Su LD, Atayde-Perez A, Sheldon S, et al. Inflammatory myofibroblastic tumor: cytogenetic evidence supporting clonal origin. *Mod Pathol.* 1998 Apr; 11(4): 364-8. PubMed PMID: 9578087.
6. Coffin CM, Hornick JL, Fletcher CD. Inflammatory myofibroblastic tumor – comparison of clinicopathologic, histologic, and immunohistochemical features including ALK expression in atypical and aggressive cases. *Am J Surg Pathol.* 2007 Apr; 31(4): 509-20. PubMed PMID: 17414097.
7. Kovach SJ, Fischer AC, Katzman PJ, et al. Inflammatory myofibroblastic tumors. *J Surg Oncol.* 2006 Oct 1; 94(5): 385-91. PubMed PMID: 16967468.
8. Kasim AB, Peter S, Andrew W, et al. Inflammatory myofibroblastic tumour of the gallbladder. *World J Surg Oncol.* 2005 Apr 29; 3(1): 24. PubMed PMID: 15862123.

9. Muduly D, Deo SVS, Shukla NK, et al. Inflammatory myofibroblastic tumor of gall bladder. *Trop Gastroenterol*. 2012 Oct-Dec; 33(4): 297-9. PubMed PMID: 23923363.
10. İsmail Ö, Mustafa Ö, Erkan Ş, et al. Inflammatory myofibroblastic tumor of the gallbladder. *Balkan Med J*. 2013 Sep; 30(3): 323-6. PubMed PMID: 25207130.
11. Badea R, Veres AA, Andreica V, et al. Inflammatory myofibroblastic tumor of the gallbladder: imaging aspects. *J Med Ultrasonics*. 2015 Jan; 42(1): 89-95. doi 10.1007/s10396-014-0566-4.
12. Coffin CM, Watterson J, Priest JR, et al. Extrapulmonary inflammatory myofibroblastic tumor (inflammatory pseudotumor) – a clinicopathologic and immunohistochemical study of 84 cases. *Am J Surg Pathol*. 1995 Aug; 19(8): 859-72. PubMed PMID: 7611533.
13. Chan JK, Cheuk W, Shimizu M. Anaplastic lymphoma kinase expression in inflammatory pseudotumors. *Am J Surg Pathol*. 2001 Jun; 25(6): 761-8. PubMed PMID: 11395553.
14. Chen ST, Lee JC. An inflammatory myofibroblastic tumor in liver with ALK and RANBP2 gene rearrangement: combination of distinct morphologic, immunohistochemical, and genetic features. *Hum Pathol*. 2008 Dec; 39(12): 1854-8. PubMed PMID: 18701132.
15. Mariño-Enríquez A, Wang WL, Roy A, et al. Epithelioid inflammatory myofibroblastic sarcoma: an aggressive intra-abdominal variant of inflammatory myofibroblastic tumor with nuclear membrane or perinuclear ALK. *Am J Surg Pathol*. 2011 Jan; 35(1): 135-44. PubMed PMID: 21164297.
16. Debelenko IV, Arthur DC, Pack SD, et al. Identification of CARS-ALK fusion in primary and metastatic lesions of an inflammatory myofibroblastic tumor. *Lab Invest*. 2003 Sep; 83(9): 1255-65. PubMed PMID: 13679433.
17. Fragoso AC, Eloy C, Estevão-Costa J, et al. Abdominal inflammatory myofibroblastic tumor: a clinicopathologic study with reappraisal of biologic behavior. *J Pediatr Surg*. 2011 Nov; 46(11): 2076-82. PubMed PMID: 22075336.
18. Solomon BJ, Mok T, Kim DW, et al. first-line crizotinib versus chemotherapy in ALK-positive lung cancer. *N Engl J Med*. 2014 Dec; 371(23): 2167-77. PubMed PMID: 25470694.
19. Shaw AT, Kim DW, Nakagawa K, et al. Crizotinib versus chemotherapy in advanced ALK-positive lung cancer. *N Engl J Med*. 2013 Jun 20; 368(25): 2385-94. PubMed PMID: 23724913.
20. Butrynski JE, D'Adamo DR, Hornick JL, et al. Crizotinib in ALK-rearranged inflammatory myofibroblastic tumor. *N Engl J Med*. 2010 Oct 28; 363(18): 1727-33. PubMed PMID: 20979472.

MAILING ADDRESS

Carlos Filipe C. Abrantes

Centro Hospitalar e Universitário de Coimbra; Serviço de Anatomia Patológica, piso 3; Praceta Mota Pinto; CEP: 3000-075; Coimbra, Portugal.