

Cervical cytopathological changes in Pap smear test in the city of Santa Cruz do Sul, Rio Grande do Sul, Brazil

Alterações citopatológicas em exames de Papanicolaou na cidade de Santa Cruz do Sul, Rio Grande do Sul, Brasil

Édina K. Fredrich; Jane D. P. Renner

Universidade de Santa Cruz do Sul (UNISC), Santa Cruz do Sul, Rio Grande do Sul, Brazil.

ABSTRACT

Objective: To determine the cytopathologic alterations in women who undergo the Papanicolaou exam by the single health system in a laboratory in the city of Santa Cruz do Sul, Rio Grande do Sul, Brazil. **Methodology:** Data were collected from cytopathological reports of the year 2015 by the cancer information system. The variables referring to age and cytopathologic alteration were selected. The analyzes were performed by descriptive statistics, including frequency, mean, standard deviation. The associations between the categorical variables were evaluated by the Qui Quadrado test in SPSS software version 22.0. **Results:** In the year 2015, 2346 women underwent cytopathological examination, where 34.7% were within the limits of normality, 62.6% presented benign cellular alteration, of which 47.5% were inflammatory. Of the alterations, 1.8% were atypical squamous cells of undetermined significance (ASC-US); 0.6% were low-grade squamous intraepithelial lesion (LSIL); 0.2% were atypical squamous cells and it was not possible to exclude high grade squamous intraepithelial lesion (ASC-H); and 0.1% were high-grade intraepithelial lesions (HSIL). Regarding the age of the women, a higher frequency was observed in the age group above 55 years and an average of 46.5 years. **Conclusion:** The benign cellular alterations were the most frequent, with the prevalence of inflammation. The most common precursor lesions of cervical cancer were ASC-US and LSIL.

Key words: cervical cancer; Papanicolaou; cytological changes; human papillomavirus.

RESUMO

Objetivo: Determinar as alterações citopatológicas em mulheres que realizam o exame de Papanicolaou pelo Sistema Único de Saúde (SUS) em um laboratório da cidade de Santa Cruz do Sul, Rio Grande do Sul, Brasil. **Metodologia:** Os dados foram coletados de laudos citopatológicos do ano de 2015 pelo Sistema de Informação do Câncer. As variáveis referentes à idade e à alteração citopatológica foram selecionadas. As análises foram realizadas por estatística descritiva, incluindo frequência, média e desvio padrão. As associações entre as variáveis categóricas foram avaliadas pelo teste de qui-quadrado no software SPSS versão 22.0. **Resultados:** No ano de 2015, 2.346 mulheres realizaram o exame citopatológico. Destas, 34,7% apresentaram resultados dentro dos limites da normalidade; 62,6%, alteração celular benigna (47,5% eram inflamatórias). Das alterações, 1,8% eram células escamosas atípicas de significado indeterminado (ASC-US); 0,6%, lesão intraepitelial de baixo grau (LSIL); 0,2%, células escamosas atípicas, não sendo possível excluir lesão intraepitelial escamosa de alto grau (ASC-H); e 0,1%, lesão intraepitelial de alto grau (HSIL). Em relação à idade, observou-se maior frequência na faixa etária acima de 55 anos, com média de 46,5 anos. **Conclusão:** As alterações celulares benignas foram as mais ocorrentes, com prevalência de inflamação. As lesões precursoras do câncer cervical mais encontradas foram ASC-US e LSIL.

Unitermos: câncer do colo do útero; Papanicolaou; alterações citológicas; papilomavírus humano.

RESUMEN

Objetivo: Determinar los cambios citológicos en mujeres que se hicieron la prueba de Papanicolaou por el sistema público de salud [Sistema Único de Saúde (SUS)] en un laboratorio de la ciudad de Santa Cruz do Sul, Rio Grande do Sul, Brasil. **Métodos:** Los datos fueron recogidos de informes citológicos del año de 2015 por el Sistema de Información de Cáncer. Se eligieron las variables edad y alteración citológica. El análisis fue realizado por estadística descriptiva, utilizando frecuencia, media y desviación estándar. Las relaciones entre las variables categóricas fueron medidas con la distribución ji-cuadrada en el paquete estadístico SPSS versión 22.0. **Resultados:** En el año de 2015, 2.346 mujeres se hicieron la citología vaginal. Entre ellas, 34,7% mostraron resultados dentro de los rangos de normalidad; 62,6%, cambio celular benigno (47,5% eran inflamatorios). Entre los cambios, 1,8% eran células escamosas atípicas de significado incierto (ASC-US); 0,6%, lesión intraepitelial escamosa de bajo grado (LSIL); 0,2%, células escamosas atípicas de alto grado (ASC-H); y 0,1%, lesión intraepitelial escamosa de alto grado (HSIL). En relación con la edad, mayor frecuencia se ha observado en la franja arriba 55 años, con media de 46,5 años. **Conclusión:** Los cambios celulares benignos fueron el hallazgo más frecuente, con prevalencia de inflamación. Las lesiones precursoras de cáncer cervical más comunes fueron ASC-US y LSIL.

Palabras clave: neoplasias del cuello uterino; Papanicolaou; cambios citológicos; virus del papiloma humano.

INTRODUCTION

According to data from the Brazilian National Cancer Institute [Instituto Nacional do Câncer (INCA)]⁽¹⁾, cervical cancer, is considered a public health problem, especially in developing countries – approximately 500,000 new cases of this neoplasm are diagnosed worldwide; from these, about one-third die. For Brazil, 16,370 new cases of the disease are estimated for each year of the 2018-2019 biennium, occupying the seventh position in the world ranking. It is the fourth most common type in the female population. In 2012, there were about 527 thousand new cases worldwide; to date, about 18 thousand new cases of cervical cancer were diagnosed per year in Brazil, and is the second cause of female death in the country⁽²⁾.

Analyzing the incidence of this neoplasm by region, the one that occupies the first position is the Northeast, in a classification by 100 thousand inhabitants. This region has a gross rate of 23.97, followed by the Central-West, Northeast, South and Southeast regions⁽³⁾.

The main cause for cervical cancer results from infection by the oncogenic types of human papillomavirus (HPV), a sexually transmitted virus. There are 30 types of oncogenic HPV, and HPV16 and HPV18 account for 70% of cancers⁽⁴⁾. In addition to infection, virus type, viral load, persistence of infection, sexual behavior, use of oral contraceptives and tobacco, multiple births and other sexually transmitted diseases (STD) are other risk factors for its development⁽⁵⁾.

Cancer of the cervix affects the lower part of the uterus, which evolves from precursor lesions. These can be detected in a period of ten to twenty years, and if treated, progression is prevented. At the onset, these abnormalities are called dysplasia, but with the persistence of the infection and the absence of detection, the lesion evolves into cancer⁽⁶⁻⁹⁾.

The modifications affected in the epithelium are detected by exfoliative cervical cytopathology stained by the Papanicolaou method, offered by the Brazilian Unified Health System [Sistema Único de Saúde (SUS)]; this tool is the most widely used due to its simplicity and low cost. This test detects precursor lesions before they become invasive, which enables proper treatment and prevention of disease onset^(7,10,11).

Cervical cancer is considered rare in women up to 30 years because it develops slowly, and its incidence progressively increases until it reaches its peak in the 45 a 50 age group⁽⁷⁾. Low-grade dysplasia and genital warts are diagnosed most commonly between 20 and 29 years; high-grade dysplasia, in the age group of 30 to 39 years; and invasive carcinoma, between 40 and 49 years⁽¹²⁾.

OBJECTIVE

The objective of this study was to determine the cytopathological changes in women who underwent Pap test by SUS in a laboratory in the city of Santa Cruz do Sul, Rio Grande do Sul, Brazil.

METHOD

The study was developed through a descriptive, retrospective, transversal and observational design of cytopathological screening. Data collection was carried out in the city of Santa Cruz do Sul, one of the main nuclei of the German colonization in Rio Grande do Sul. Its economy is historically linked to tobacco, and is considered the world's tobacco capital.

The reports accessed in the Cancer Information System from Brazil [Sistema de Informação do Câncer (SISCAN)] were the materials used for the development of this scientific research. This system is the web platform version that integrates the Information Systems for Cervical Cancer from Brazil [Sistemas de Informação do Câncer do Colo do Útero (SISCOLO)] and Information Systems for Breast Cancer from Brazil [Sistemas de Informação do Câncer de Mama (SISMAMA)], whose objective is to register the request for cytopathological and histopathological exams of the cervix and breast exams, such as mammography, results of all the requested tests and follow-up of the altered results, besides generating data that subsidize the monitoring and the evaluation of patients.

The study included all reports of women who underwent Pap smear in the year 2015; no results have been discarded. The variables related to age and cytopathological changes were selected and analyzed by descriptive statistics, including frequency, mean and standard deviation. The associations between the categorical variables were evaluated by the chi-square test in the SPSS software version 22.0.

The project was approved by the Research Ethics Committee [Comitê de Ética em Pesquisa (CEP)] of the Universidade de Santa Cruz do Sul (UNISC) under the opinion 2.417.763 and the protocol CAEE 80561817.0.0000.5343, according to resolution 466/12 of the Brazilian National Health Council [Conselho Nacional de Saúde (CNS)].

RESULTS

We evaluated 2,346 reports of cytopathology, in which the mean age of women was 45.76 years (\pm 13.5) and the most frequent age group was older than 55 years (27.2%) (Table 1). The examinations showed a proportional increase in relation to the age group.

The epithelia found in the reports show that 28.6% of the collections presented only the squamous epithelium; 63.2%, squamous and glandular epithelium; 6%, squamous, glandular and metaplastic epithelium; 2.1%, squamous and metaplastic epithelium; and 0.1%, only glandular epithelium (Table 1).

The benign cellular changes were highlighted due to the higher prevalence, with 1469 (62.6%) cases. Considering these changes, 47.5% were inflammation (Table 1). Regarding the cellular atypia, the most frequent was atypical squamous cells of undetermined significance (ASC-US), in 42 reports (1.8%) (Table 1).

Regarding the reports analyzed for microbiology, it can be observed in Figure that cocci (986) showed the highest occurrence, followed by *Lactobacillus* (767).

TABLE 1 – Age and descriptive diagnosis of cytopathological examination

Variables	n (%)
Age	
Younger than 25 years	189 (8.1)
26-35 years	427 (18.2)
36-45 years	500 (21.3)
46-55 years	593 (25.3)
Older than 55 years	637 (27.2)
Epithelium represented in the sample	
Squamous	670 (28.6)
Squamous and glandular	1482 (63.2)
Squamous, glandular, metaplastic	141 (6)
Squamous, metaplastic	50 (2.1)
Glandular	3 (0.1)
Cellular changes	
Normal	810 (34.5)
Atrophy with inflammation	368 (15.7)
Inflammation	1113 (47.5)
Hypotrophy	54 (2.3)
Radiation	1 (0)
Cellular atypia	
Normal	814 (34.7)
Benign cellular change	1469 (62.6)
ASC-US	42 (1.8)
ASC-H	4 (0.2)
LSIL	14 (0.6)
HSIL	3 (0.1)
Total	2346 (100)

ASC-US: atypical squamous cells of undetermined significance; ASC-H: atypical squamous cells, cannot exclude a high-grade squamous intraepithelial lesion; LSIL: low-grade squamous intraepithelial lesion; HSIL: high-grade squamous intraepithelial lesion.

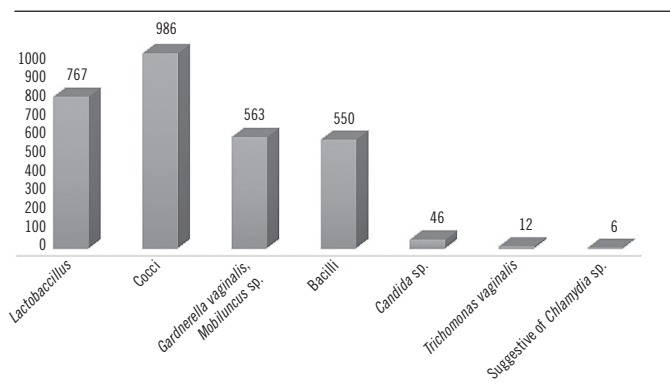


FIGURE – Microorganisms found in cytological examination

Table 2 shows the relationship between the age group and the diagnoses found in the results of Pap smears. Cellular changes were statistically significant when compared with age ($p = 0.001$).

TABLE 2 – Comparison of age and cellular atypia

Age (years)	Normal	Benign cellular change	ASC-US	ASC-H	LSIL	HSIL
Younger than 25 years	73	108	6	0	2	0
26-35 years	157	255	9	1	5	0
36-45 years	207	283	7	0	2	1
46-55 years	241	337	9	2	4	0
Older than 55 years	136	486	11	1	1	2
Total	814	1469	42	4	14	3

ASC-US: atypical squamous cells of undetermined significance; ASC-H: atypical squamous cells, cannot exclude a high-grade squamous intraepithelial lesion; LSIL: low-grade squamous intraepithelial lesion; HSIL: high-grade squamous intraepithelial lesion.

DISCUSSION

The results showed a predominance of women older than 55 years of age undergoing Pap tests. The Brazilian Ministry of Health guides to perform this examination from 25 to 64 years of age, since women in this age group are at a higher risk of developing high-grade lesions. In relation to the mean age, the present study found the value of 45.76 years. In the works of Reis *et al.* (2013)⁽¹³⁾, Tuon *et al.* (2002)⁽¹⁴⁾ and Levi *et al.* (2011)⁽¹⁵⁾, the values found were divergent, with mean of 31.4, 30.2 and 33 years, respectively. A similar value was found in the city of Juiz de Fora, Minas Gerais, Brazil, with mean of 43.5 years⁽¹⁶⁾.

With regard to the epithelium, it is known that the public network⁽¹⁷⁾ does not require the representation of the squamous and glandular and/or metaplastic epithelium to consider

appropriate the examination. The absence of one of the epithelia does not ensure the absence of neoplastic or precursor lesions. The epithelia found in the reports, in the present study, showed that 28.6% presented only the squamous epithelium, tending for possible false negatives due to inappropriate collection. Another research⁽¹⁸⁾ also showed the absence of both types of epithelia in all records of the reports, in which the squamous epithelium represented 80.9% of the cases.

According to the Brazilian Ministry of Health⁽¹⁷⁾, the presence of metaplastic or endocervical cells, representative of the transformation zone that is related to cancer of the cervix, is required to check the quality of the collection. This study pointed out that the frequency of squamous epithelial examinations was superior to that of the metaplastic and glandular epithelia, corroborating the findings of Sousa *et al.* (2017)⁽¹⁸⁾, in which squamous epithelium prevailed.

Pap tests have been used secondarily in the detection of microorganisms. In general, the vaginal microbiota is predominantly composed of *Lactobacillus* spp., but the acidic environment of the vagina, recognized as an important defense mechanism against the proliferation of pathogens, can be sustained by other microorganisms that can remain isolated in the vagina of healthy women. Microbiological findings compatible with cocci and other bacilli are considered normal findings, since they are also part of the vaginal flora and do not characterize infections that require treatment, as well as species of *Gardnerella* and the fungus *Candida*, which can exist in 50% of women without necessarily cause infection^(15,19).

In this study, the microbiota detected in the Pap test reports was represented by the high prevalence of cocci, followed by *Lactobacillus* spp. The supracyttoplasmic bacilli suggestive of *Gardnerella/Mobiluncus*, followed by *Candida* sp., the protozoan *Trichomonas vaginalis* and the bacterium suggestive of *Chlamydia* sp. may have been responsible for inflammation. A study carried out in a Basic Health Unit [Unidade Básica de Saúde (UBS)] in the State of Ceará also presented cocci as a major occurrence (49.2%), as well as infectious agents such as *Gardnerella vaginalis* (65%), *Candida* sp. (23.7%) and *Trichomonas vaginalis* (5.6%)⁽¹⁶⁾.

The results of cellular changes of this study were similar to those of other studies carried out in Aracaju⁽¹³⁾ and Teresina⁽¹⁸⁾, in which inflammations were more frequent, with rates of 84% and 85.5%, respectively. The inflammation may be caused by the action of physical agents (radioactive, mechanical or thermal) or chemical agents (abrasive or chemotherapeutic drugs and vaginal acidity) on the glandular epithelium; may occasionally

be caused by the use of the intrauterine device (IUD) or by the presence of pathogens unidentified in the examination⁽⁷⁾.

When evaluating the changes in the cervical cytopathology performed by the laboratory in 2015, a higher frequency of ASC-US was observed in 1.8%; low-grade squamous intraepithelial lesion (LSIL) in 0.6%; atypical squamous cells, cannot exclude a high-grade squamous intraepithelial lesion (ASC-H) in 0.2% and high-grade squamous intraepithelial lesion (HSIL) in 0.1%. On the other hand, in a similar study conducted in 2014 in Paraná⁽²⁰⁾, from 1,022 altered reports, ASC-US and/or LSIL were found in 81.1%; ASC-H, in 9.3% and HSIL, in 8.3% of the reports. In a study in Uruguaiana⁽²¹⁾, a predominance of ASC-US and LSIL was observed, representing, respectively, 987 (50.28%) and 696 (35.45%) patients.

The squamous cell changes, according to the Brazilian Cytological Classification, can be divided into ASC-US and ASC-H. The frequency of cytological diagnosis of ASC-US ranges from 1.6% to 9%; it is recommended that this value does not exceed two or three times the LSIL frequency⁽²²⁾. About 20% to 40% of patients diagnosed with ASC-US will have any associated neoplasia; in about 5% to 15%, this association will be with HSIL. Although it is a rare event, the smear with ASC-US diagnosis may be associated with the presence of a hidden cancer in about 0.1%⁽²³⁾.

ASC-H, although less frequent, has a greater association with the development of HSIL. Cytryn (2008)⁽²⁴⁾ showed that the prevalence of HSIL in the ASC-H cytology of patients referred from SUS was 19.29% [confidence interval (CI) 95% 9.05%-29.55%] and reported that the possibility of high-degree disease was higher among patients with ASC-H cytology compared to those with ASC-US cytology.

HPV is the major developmental factor for cervical cancer, and is found in more than 85% of high-grade cervical intraepithelial

neoplasia, considered precursors of cervical cancer. For cases of adenocarcinoma, the prevalence of HPV is around 90%⁽²⁰⁾. In this study, only three cases of high-grade lesions and three cases of low-grade lesions were shown.

Based on a retrospective study⁽²⁵⁾ on 532 adolescents aged from 12 to 18 years with LSIL (477) and HSIL (55), cancer progression was observed. The research showed that from the patients previously analyzed with LSIL, 35% presented negative findings at follow-up; 47%, low-grade lesions and 18%, high-grade lesions. After follow-up for three years, 62% regressed the disease; 7% persisted with the neoplasia and 31% evolved the condition. Regarding the HSIL patients, initially, 22% presented negative findings at follow-up; 27%, LSIL and 51%, HSIL. The progression to cervical intraepithelial neoplasia confirmed by biopsy occurred in 31% after follow-up for three years.

A retrospective analysis of 230 cases of patients previously diagnosed with low-grade cervical lesions to cervical squamous carcinomas, for five years, showed that 20.7% of these lesions regressed spontaneously, 48.9% persisted and 30.4% progressed. The spontaneous regression cases presented low-risk HPV (6/11) in 68.4% of the lesions; persistent and progressive cases presented high-risk types. Oncogenic HPV types (16/18) were strongly associated with progression, whereas HPV 31/33/35 types had no significant correlation⁽²⁶⁾.

CONCLUSION

The cytopathological changes found in women who underwent Pap smear examination by SUS, in a laboratory in Santa Cruz do Sul, were benign cellular changes, with a prevalence of inflammation. The most frequent precursor lesions of cervical cancer were ASC-US and LSIL.

REFERENCES

1. Brasil. INCA. Instituto Nacional de Câncer. Estimativa 2018, incidência de câncer no Brasil [accessed: 2 April, 2018]. Available at: <http://www.inca.gov.br/estimativa/2018/estimativa-2018.pdf>.
2. Bruni L, Rosas L, Albero G, et al. ICO information centre on HPV and cancer (HPV information centre). Human papillomavirus and related diseases in Brazil. Sum Rep. 2017.
3. Brasil. INCA. Ministério da Saúde/Instituto Nacional de Câncer José Alencar Gomes da Silva. Estimativa 2016: incidência de câncer no Brasil. Rio de Janeiro: INCA; 2015. 122 p.
4. Valenti G, Vitale SG, Tropeal A, Biondil A, Lagana AS. Tumor markers of uterine cervical cancer: a new scenario to guide surgical practice? *Updates Surg*. 2017; 69(4): 441-9.
5. Chelimo C, Wouldes TA, Cameron LD, Elwood JM. Risk factors for and prevention of human papillomaviruses (HPV), genital warts and cervical cancer. *J Infect*. 2013; 66(3): 207-17.
6. Consolaro M, Engler S. *Citologia clínica cervicovaginal: texto e atlas*. 1 ed. São Paulo: Roca; 2014.
7. Brasil. INCA. Instituto Nacional de Câncer José Alencar Gomes da Silva. Coordenação de prevenção e vigilância. Divisão de detecção precoce e apoio à organização de rede. Diretrizes brasileiras para o rastreamento do câncer do colo do útero. 2 ed rev atual. Rio de Janeiro: Inca; 2016.

8. Pinho AA, Mattos MCFI. Validade da citologia cervicovaginal na detecção de lesões pré-neoplásicas e neoplásicas de colo de útero. *J Bras Patol Med Lab.* 2002; 38(3): 225-31.
9. Schiffman M, Castle PE, Jeronimo J, Rodriguez AC, Wacholder S. Human papillomavirus and cervical cancer. *Lancet.* 2007; 370: 890-907.
10. Brasil. INCA. Periodicidade de realização do exame preventivo do câncer do colo do útero. *Rev Bras Cancerol.* 2002; 48(1): 13-5.
11. Caetano R, Vianna CMM, Thuler LCS, Girianelli VR. Custo-efetividade no diagnóstico precoce do câncer de colo uterino no Brasil. *Rev Saúde Coletiva.* 2006; 16(1): 99-118.
12. Long HJ, Laack NI, Gostout BS. Prevention, diagnosis, and treatment of cervical cancer. *Mayo Clin Proc.* 2007; 82(12): 1566-74.
13. Reis NROG, Costa AMC, Madi RR, Melo CM. Perfil microbiológico e alterações citológicas associadas em material cervicovaginal coletado em consultório de enfermagem, de 2009 a 2011 em Aracaju/SE. *Scientia Plena.* 2013; 9(5).
14. Tuon FFB, Bittencourt MS, Panichi MA, Pinto AP. Avaliação da sensibilidade e especificidade dos exames citopatológico e colposcópico em relação ao exame histológico na identificação de lesões intraepiteliais cervicais. *Rev Assoc Med Bras.* 2002; 48(2): 140-44.
15. Levi AW, Harigopal M, Hui P, Schofield K, Chhieng DC. Comparison of affirm VPIII and Papanicolaou tests in the detection of infectious vaginitis. *Am J Clin Pathol.* 2011; 135: 442-7.
16. Campos AAL, Neve FS, Duque KCD, Leite ICG, Guerra MR, Teixeira MTB. Fatores associados ao risco de alterações no exame citopatológico do colo do útero. *Ver Enfermagem Centro-Oeste Mineiro.* 2018; 8(2330).
17. Brasil. Ministério da Saúde. Secretaria de Atenção à Saúde. Departamento de Atenção Básica. Controle dos cânceres do colo do útero e da mama. 2 ed. Brasília: Ministério da Saúde; 2013. p. 55. Available at: <http://dab.saude.gov.br/portaldab/biblioteca.php?conteudo=publicacoes/cab13> [accessed: 20 May, 2018].
18. Sousa ACO, Passos FFB, Costa GS, Oliveira FP, Rodrigues TS. Análise das alterações citopatológicas registradas no sistema de informação do câncer de colo do útero em Teresina. *Rev Interdisciplinar.* 2017; 10(4): 21-30.
19. Linhares IM, Giraldo PC, Baracat EC. Novos conhecimentos sobre a flora bacteriana vaginal. *Rev Assoc Med Bras.* 2010; 56(3): 370-4.
20. Menetrier JV, Boing A, Medeiros KA. Alterações citopatológicas do colo uterino em mulheres atendidas na 8ª Regional de Saúde do Paraná no ano de 2014. *Ver Saúde Pública Paraná, Londrina.* 2016; 17(2): 169-77. *J Bras Doen Sex Trans.* 2012; 24(3): 167-70.
21. Stohrer DJ, Aramburu TDB, Abad MAS, Nunes VT, Manfredini V. Perfil citopatológico de mulheres atendidas nas unidades básicas do município de Uruguaiana, RS. *J Bras Doenças Sex Trans.* 2012; 24(3): 167-70.
22. Lodi CTC, Lima MIM, Meira HRC, et al. Células escamosas atípicas cervicais: conduta clínica. *Rev Femina.* 2012; 40(1).
23. Sampaio Jr CA, Lima LR, Silva ILC. Células escamosas atípicas de significado indeterminado: revisão da literatura. *Rev Inter Ciências e Saúde.* 2017; 4(1).
24. Cytryn A. Risco de lesão intraepitelial escamosa de alto grau e câncer cervical nas pacientes com diagnóstico citológico de células escamosas [dissertation]. Fundação Oswaldo Cruz, Instituto Fernandes Figueira, Rio de Janeiro; 2008.
25. Wright JD, Davila RM, Pinto KR, et al. Cervical dysplasia in adolescents. *Obstetr Ginecol.* 2005; 106(1).
26. Cavalcanti SMB, Deus FCC, Zardo LG, Frugulhetti ICPP, Oliveira LHS. Human papillomavirus infection and cervical cancer in Brazil: a retrospective study. *Memórias do Instituto Oswaldo Cruz.* 1996; 91(4).

CORRESPONDING AUTHOR

Édina Knod Fredrich  0000-0002-5585-0649
e-mail: ediina.02@gmail.com



This is an open-access article distributed under the terms of the Creative Commons Attribution License.