

# Diagnostic accuracy between fine needle aspiration biopsy (FNA) and pathological examination of the thyroid

## *Acurácia diagnóstica entre punção aspirativa por agulha fina (PAAF) e exame anatomopatológico de tireoide*

Jerso Menegassi<sup>1</sup>; Vanessa Bordin<sup>2</sup>; Saimon Santos Oliveira<sup>2</sup>

### ABSTRACT

**Introduction:** Despite the fact that the fine needle aspiration biopsy (FNA) is commonly used in the initial evaluation and distinction of benign and malignant lesions of thyroid nodules, it may yield variable results, inasmuch as it is contingent on the pathologist's analysis and expertise in collecting appropriate samples. **Objective:** To check the diagnostic accuracy between FNA and pathological examination of thyroid nodules, both performed in a diagnostic pathology service. **Methods:** Retrospective study carried out in a diagnostic pathology service in Chapecó, Santa Catarina, Brazil. All patients who underwent FNA and pathological examination in the period from January 1<sup>st</sup> 2005 to December 31 2010 were included in this study. **Results:** 1,172 FNA were conducted during this period and 265 patients underwent both FNA and pathological examination. Most patients were female (85%), with mean age 47.75 years (standard deviation [SD] = 14.93 years). Cytopathological examinations yielded the following results: benignity (43.77%), suspected malignancy (23.77%), follicular neoplasm (5.28%), atypical follicular lesion of undetermined significance (1.51%) and unsatisfactory sample (1.51%). In the pathological examination, the most predominant diagnoses were colloid goiter (38.87%), follicular adenoma (22.64%) and classic papillary carcinoma (18.87%). In satisfactory samples ( $n = 261$ ), the following results were obtained: diagnostic accuracy (89.66%), sensitivity (82.14%), specificity (93.22%), negative predictive value (91.67%) and positive predictive value (75.19%). **Conclusion:** We concluded that FNA provides a good predictive value for benign thyroid, constituting a reliable and effective tool for diagnosis and surgical indication.

**Key words:** diagnostic accuracy; fine-needle aspiration biopsy; thyroid nodules.

### INTRODUCTION

The nodular thyroid disease is characterized by an abnormal growth of a nodule clinically evident in the gland, causing structural and/or functional alterations. The etiology of the disease is multifactorial, comprising a spectrum from a small nodule found incidentally to a large intrathoracic multinodular goiter<sup>(7)</sup>.

Thyroid nodules, the main clinical manifestation of a number of thyroid diseases, are commonly benign and frequent lesions. Studies show the prevalence of approximately 4% of palpable

thyroid nodules in the general population, of which only 5% are malignant<sup>(15)</sup>.

Currently, there is some research into new ways to reach an accurate diagnosis. Despite the use of common procedures such as gland palpation and modern diagnostic imaging, a new sensitive and specific method is still required in order to ensure cost effectiveness and avoid patient discomfort.

The fine needle aspiration biopsy (FNA) is one of the diagnostic methods of thyroid lesions, consisting of the cytopathological study of morphological alterations in isolated cells obtained by the introduction of a needle into the lesion. FNA guided by ultrasound

First submission on 19/04/13; last submission on 19/04/13; accepted for publication on 27/06/13; published on 20/08/13

1. Pathologist; professor of Medicine at Universidade Comunitária da Região de Chapecó (UNOCHAPECÓ).

2. Graduate medical student at UNOCHAPECÓ.

scan (USS) is the initial method for the assessment of patients with thyroid nodules, with the objective to identify malignant nodules, differentiating them from benign lesions<sup>(14)</sup>.

The use of FNA has reduced the number of thyroidectomies by approximately 50%, while it increased the diagnosis of thyroid cancer<sup>(8)</sup>. Nevertheless, FNA cannot characterize malignant or benign follicular lesions, inasmuch as it is not possible to analyze the capsule of the lesion, which is a determinant factor in the characterization of malignancy.

At present, in cases of suspected malignancy or malignancy assessed by FNA, surgery is recommended. Intraoperative pathological examinations may be performed during surgery through macroscopic and microscopic study of the surgical specimen with the aim to establish a final diagnosis. The pathological exam plays a pivotal role in the definition of risk after surgery<sup>(9)</sup>.

## OBJECTIVE

The objective of this study was to determine the diagnostic accuracy of FNA in relation to the pathological examination of thyroid nodules, both procedures performed in a pathology laboratory in Chapecó, Santa Catarina, Brazil.

## METHODS

We conducted a retrospective study in a reference center for diagnostic pathology in Chapecó-SC by comparing cytology and histopathology (gold standard) from FNA. Data were obtained from the internal information system of procedures performed at Instituto de Patologia do Oeste.

This paper was submitted to the analysis of the Committee of Ethics in Research-Unochapecó on August 12, 2010, meeting the criteria defined in Resolution 196/96 as well as its complements from the National Health Council of the Ministry of Health and being registered under the number 115/10.

We included in the study those patients who had undergone both FNA and pathological examination of the thyroid at Instituto de Patologia do Oeste. The selected cases were supposed to have cytopathological and pathological reports on file. Patients who had undergone only one of the procedures were excluded from the sample.

The research was based on the classification of thyroid nodules proposed by the National Cancer Institute of the United States

(2008), which categorizes the nodules as benign, malignant, atypical lesions of undetermined significance, suspected, follicular neoplasm and unsatisfactory sample.

Data were entered in Microsoft Excel<sup>®</sup> 2007. Data analysis was performed with the Statistical Package for Social Sciences (SPSS) version 18.0<sup>®</sup> and Microsoft<sup>®</sup> Excel 2007. Statistical analysis was based on frequency data and diagnostic agreement of the procedures. We determined sensitivity, specificity, negative predictive value (NPV) and positive predictive value (PPV), in which the sensitivity (vero positive [VP]/vero negative [VN] + false-negative [FN]) establishes the amount of false-positives [FPs]. The specificity (VN/VP + FP) establishes the amount of FNs. PPV (TP/TP + FP), VPN (VN/VN + FN) and diagnostic accuracy (VP + VN/VP + VN + FP + FN) were calculated and the diagnostic accuracy was the proportion of accurate predispositions.

## RESULTS

1,172 fine needle aspiration biopsies were performed in the period from January 1<sup>st</sup> 2005 to December 31 2010. 907 fine needle aspiration biopsies were excluded for not meeting the inclusion criteria. We evaluated a total of 265 patients who underwent both FNA and pathological examination during the study period.

It was observed that 85% of patients were female, with a sex ratio (female: male) of 5.46:1. The mean age was 47.75 years (standard deviation [SD] = 14.93 years), with median age of 48 years (and variation of 2-83 years). The age group with predominant diagnosis was 50-60 years (27.9%).

The FNA findings were the following: benign (43.77%), suspected of malignancy (23.77%), follicular neoplasm (25.28%) and atypical lesions of undetermined significance (1.51%). The sample was unsatisfactory in 1.51% of analyzed biopsies (**Table 1**).

**TABLE 1** – Frequency of thyroid pathologies in patients who underwent FNA (*n* = 265)

Thyroid pathology	Frequency (%)
Benign	43.77%
Follicular neoplasia	25.28%
Suspected malignancy	23.77%
Malignant	4.15%
Atypical lesion of undetermined significance	1.51%
Unsatisfactory sample	1.51%

FNA: *fine needle aspiration biopsy*.

By correlating the types of surgical resection that were performed among the patients, it was noted that total thyroidectomy was the most frequent type of surgery (53%), followed by partial thyroidectomy (45%).

By analyzing the pathological examinations, it was observed that 69% of the findings were benign, of which the colloid goiter was the most frequent pattern, accounting for 57% of benign lesions, followed by follicular adenoma (33%), normal parenchyma and thyroiditis (3% each), hyperplasia and Hurthle cell adenoma (2% each) (**Table 2**). The most prevalent malignant pattern was the classic papillary carcinoma, accounting for 60% of total malignant lesions, followed by follicular variant of papillary carcinoma and follicular carcinoma (11% each), medullary carcinoma (9%), other types of papillary carcinoma (5%), anaplastic carcinoma and a poorly differentiated carcinoma (2% each) (**Table 3**).

**TABLE 2 – Benign findings from the pathological examination of the thyroid ( $n = 182$ )**

Pathological diagnosis	Cases (%)
Colloid goiter	56.59%
Follicular adenoma	32.97%
Normal parenchyma	3.30%
Thyroiditis	3.30%
Hyperplasia	2.20%
Hurthle adenoma	1.65%

**TABLE 3 – Malignant findings from the pathological examination of the thyroid ( $n = 83$ )**

Pathological diagnosis	Cases (%)
Classic papillary carcinoma	60.24%
Follicular variant of papillary carcinoma	10.84%
Papillary carcinoma (other types)	4.82%
Follicular carcinoma	10.84%
Poorly differentiated carcinoma	2.41%
Medullary carcinoma	8.43%
Anaplastic carcinoma	2.41%

In the overall pathological samples, the most prevalent finding was colloid goiter (38.87%), followed by follicular adenoma (22.64%), classic papillary carcinoma (18.87%), follicular carcinoma and follicular variant of papillary carcinoma (3.40% each), medullary carcinoma (2.64%), thyroiditis and normal parenchyma (2.26% each), other types of papillary carcinoma and hyperplasia (1.51% each), Hurthle cell adenoma (1.13%), poorly differentiated carcinoma and anaplastic carcinoma (0.75% each).

Considering only patients with satisfactory samples, it was possible to verify that the diagnostic accuracy was 89.66%,

sensitivity 82.14%, specificity 93.22%, NPV 91.67% and PPV 75.19% (**Table 4**).

**TABLE 4 – Statistical values: diagnostic accuracy between FNA and the pathological examination of the thyroid ( $n = 261$ )**

Statistical values	Results (%)
Sensitivity	82.14%
Specificity	93.22%
PPV	85.19%
NPV	91.67%
Diagnostic accuracy	89.66%

FNA: fine needle aspiration biopsy; PPV: positive predictive value; NPV: negative predictive value.

## DISCUSSION

FNA is a well established diagnostic technique in the selection of patients with thyroid nodules for surgical treatment, reducing the number of unnecessary surgical procedures in cases of non-malignant neoplasms<sup>(1,2,6)</sup>.

Herein, we deployed the cytological classification recommended by the National Cancer Institute of the United States (2008), therefore the FNA findings were included into six different categories. Thus, it was observed that most of these nodules were benign (43.77%), which corroborates literature findings, followed by follicular neoplasia (25.28%), suspected malignancy (23.77%), atypical lesions of undetermined significance and unsatisfactory sample (1.51% each). In a study conducted in the United States in 2007, which used six different possible classifications for FNA results, 64.6% of the findings were benign, followed by sample with undetermined significance (11.6%), unsatisfactory sample (10.4%), malignant (7.6%), atypical lesions (3.2%) and suspected malignancy (2.6%). The follicular lesions were placed in the “atypical lesions” category. Correlating these data, we observed a higher prevalence of malignant findings and suspected malignancy in the present study by contrasting the respective prevalences detected in the cited study<sup>(16)</sup>.

In a Brazilian study from 2003, 44.6% of the findings were considered benign, 16.2% malignant, 29.2% undetermined, and 10% unsatisfactory sample. Herein, the follicular lesion was classified along with undetermined sample. By adding data on follicular neoplasm and atypical lesion of undetermined significance, a total of 26.76% was achieved<sup>(2)</sup>. This difference in classification in various studies may be due to the difficulty in characterizing benign or malignant follicular lesion by FNA. Consequently, some authors prefer to consider it undetermined sample, others apply the follicular neoplasia classification or even classify it as suspected malignant lesion.

The differential diagnosis between follicular adenoma and follicular thyroid carcinoma is hindered owing to the cytological similarity of both lesions and the impossibility of verifying vessel and/or capsule invasion through FNA, which are ultimately the criteria for determining malignancy. The use of the terms “follicular lesion” or “follicular standard” is recommended for these nodules, thus the classification “follicular neoplasia” was adopted herein<sup>(4)</sup>.

As to the pathological findings, there was a prevalence of benign lesions (69%) and malignant lesions (31%) in the present study, consistent with the yielded results from previously mentioned studies. Regarding benign pathological findings, the colloid goiter was the most prevalent diagnosis, accounting for 57% of 182 patients belonging to this group, followed by follicular adenoma (33%), hyperplasia, thyroiditis and normal parenchyma, which accounted for 8% of patients. These results were similar to those yielded at a study carried out in 2001 in a hospital in Porto Alegre-RS<sup>(12)</sup>.

It is known that the papillary carcinoma is the most common form of thyroid cancer, accounting for about 70% of cases. Moreover, it has the best prognosis in comparison with other thyroid malignant neoplasias. In our study, the classic papillary carcinoma appeared as the most prevalent, corresponding to 60% of total malignant pathological findings, followed by the follicular variant of papillary carcinoma and follicular carcinoma (11% each) as well as other types of papillary carcinoma (5%)<sup>(3)</sup>.

As to diagnostic values, the diagnostic accuracy was 89.66% and this value was situated within the variation window in comparison with the results obtained in previous studies. Based on a 2002 study, sensitivity values for FNA ranged from 65% to 99% and specificity from 72% to 100%. Herein, sensitivity and specificity for detecting neoplasias by FNA corresponded to 82.14% and 93.22%, respectively<sup>(10)</sup>.

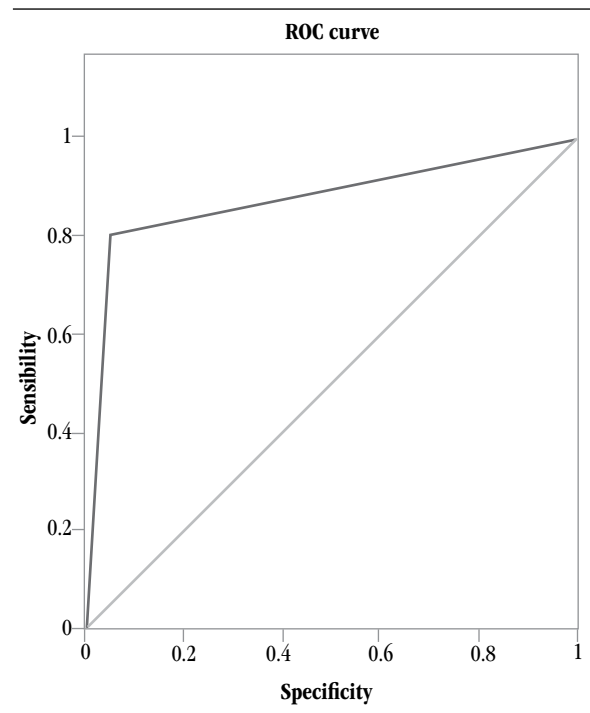
Furthermore, it was observed that the specificity value was higher than the sensitivity value, hence FNB is a reliable predictor of benign thyroid pathology. It is known that the specificity demonstrates the ability of a test to distinguish true negatives in relation to the total number of patients<sup>(5)</sup>.

The way pathologists categorize suspicious lesions and how they define the false-positives and negatives account for this wide variation in sensitivity and specificity results. Although some authors include follicular lesions in the malignancy category, some characterize them in the negative group and others even exclude follicular lesions from the general calculation<sup>(1)</sup>.

A variable that may have contributed to the accuracy results is the participation of both a pathologist conducting FNA and a radiologist guiding the procedure via USS. Although there are few studies comparing the performance of USS-guided FNA and conventional approach (guided by palpation), they concur that the association with USS improves overall accuracy<sup>(13)</sup>.

Regarding NPV and PPV, an individual had 91.67% probability of not having malignant thyroid lesions when the cytopathological examination indicated benign alteration and 75.19% probability of presenting a malignant lesion when the cytological examination revealed malignant alteration.

It is claimed that the accuracy of a diagnostic test is contingent on the reliable distinction between benign and malignant findings. A widespread tool to assess the performance of diagnostic tests is the analysis of Receiver Operating Characteristic curve (ROC), a direct visual representation of a test performance. The accuracy is measured by the area under the ROC curve. An area equal to 1 represents a perfect test, that is to say that all diagnoses have to be accurate. An area equal to 0.5 represents an unreliable test, inasmuch as the simple flip of a coin would lead to a curve close to identity line. Therefore, the higher the value ( $0.5 >$ ), the better the test classification according to its performance. The curve demonstrated in this investigation (**Figure**) is consistent with previous studies, comprising an area of 0.876<sup>(11)</sup>.



**FIGURE** – ROC curve for diagnostic accuracy in FNA and pathological examination of the thyroid (n = 261)  
ROC: receiver operating characteristic.

Taking into account the importance of the interpretation of ROC curves, it is possible to choose the best clinical and surgical procedures based on cutoff points, providing greater safety for both doctor and patient. Nevertheless, even with the availability of these complementary diagnostic tools, it is imperative to address the need for further studies that will add more specific criteria for determining malignant nodules, hence improving the accuracy of FNA, which is deemed to be a cost-effective option.

## CONCLUSION

After comparison of 265 cytopathological and pathological thyroid examinations, we verified that FNA established the diagnosis in 89.66% of cases, generally presenting statistical results compatible with those reported in similar studies.

We concluded that this procedure is consistent and easy to perform and provides reliable prediction of benign thyroid pathologies.

## RESUMO

**Introdução:** A punção aspirativa por agulha fina (PAAF), apesar de ser utilizada na avaliação inicial e na distinção de lesões benignas e malignas de nódulos da tireoide, pode promover resultados variados, uma vez que depende da análise do patologista e da habilidade em coletar amostras adequadas. **Objetivo:** Verificar a acurácia diagnóstica entre a PAAF e o exame anatomopatológico de nódulos tireoidianos, realizados em um serviço de diagnósticos de patologia. **Métodos:** Estudo retrospectivo realizado em um serviço de diagnósticos de patologia em Chapecó, Santa Catarina, Brasil. Participaram do estudo todos os pacientes que realizaram PAAF e exame anatomopatológico no período de 1º de janeiro de 2005 a 31 de dezembro de 2010. **Resultados:** Foram realizadas 1.172 punções no referido período, sendo avaliados, ao total, 265 pacientes que realizaram tanto a PAAF quanto o exame anatomopatológico. Houve predominância de mulheres (85%), com uma média de 47,75 anos de idade (desvio padrão [DP] = 14,93 anos). Nos exames citopatológicos, diagnosticou-se benignidade em 43,77% dos casos, suspeita de malignidade em 23,77%, neoplasia folicular em 25,28%, lesão atípica de significado indeterminado em 1,51% e amostra insatisfatória em 1,51%. No anatomopatológico, os diagnósticos que predominaram foram bócio colóide (38,87%), adenoma folicular (22,64%) e carcinoma papilar clássico (18,87%). Nas amostras satisfatórias (n = 261), verificou-se que a acurácia diagnóstica foi de 89,66%, sensibilidade de 82,14%, especificidade de 93,22%, valor preditivo negativo de 91,67% e valor preditivo positivo de 75,19%. **Conclusão:** Conclui-se que a PAAF proporciona boa predição de patologia benigna da tireoide, sendo um meio confiável e efetivo para diagnóstico e indicação cirúrgica.

**Unitermos:** acurácia diagnóstica; punção aspirativa com agulha fina; nódulo de tireoide.

## REFERENCES

1. AMRIKACHI, M. *et al.* Accuracy of fine-needle aspiration of thyroid. *Arch Pathol Lab Med*, v. 125, n. 4, p. 484-8, 2001.
2. BEZERRA, C. S. F. *et al.* Punção aspirativa por agulha fina em lesão nodular de tireoide. *Rev Col Bras Cir*, v. 30, n. 3, p. 164-9, 2003.
3. CAMANDAROBÁ, M. P. G. *et al.* Carcinoma papilífero da tireoide associado à tireoidite de Hashimoto: uma série de casos. *Rev Bras Cancerol*, v. 55, n. 3, p. 255-61, 2009.
4. CERUTTI, J. M. Nódulos com diagnóstico de padrão folicular: marcadores biológicos são o futuro? *Arq Bras Endocrinol Metab*, v. 51, n. 5, p. 832-42, 2007.
5. FLETCHER, R. H. *Epidemiologia clínica – elementos essenciais*. São Paulo: Editora Artmed, 2006.
6. GOIS, W. A. F. *et al.* Punção aspirativa por agulha fina no diagnóstico de linfadenopatias e tumores sólidos em crianças e adolescentes. *Rev Col Bras Cir*, v. 35, n. 1, p. 5-8, 2008.
7. GRAF, H. Doença nodular de tireoide. *Arq Bras Endocrinol Metab*, v. 48, n. 1, p. 93-104, 2004.
8. KORUN, N. A. *et al.* Total thyroidectomy or lobectomy in benign nodular disease of the thyroid: changing trends in surgery. *Int Surg*, v. 82, n. 4, p. 417-9, 1997.
9. MAIA, A. L. *et al.* Nódulos de tireoide e câncer diferenciado de tireoide: consenso brasileiro. *Arq Bras Endocrinol Metab*, v. 51, n. 5, p. 867-93, 2007.
10. MATEŠA, N. *et al.* Fine needle aspiration of the thyroid. *Acta Clin Croat*, v. 41, n. 2, p. 123-31, 2002.
11. METZ, C. E. *Statistical analysis of ROC data in evaluating diagnostic performance*. Multiple regression analysis: applications in the health

- sciences. In: HEBERT, D.; MYERS, R. New York: American Institute of Physics, 1986. Cap 13; p 365-84.
12. MURUSSI, M. *et al.* Punção aspirativa de tireoide com agulha fina em um hospital geral: estudo de 754 punções. *Arq Bras Endocrinol Metab*, v. 45, n. 6, p. 576-83, 2001.
13. ROCHA, R. P. *et al.* Punção aspirativa por agulha fina guiada por ultra-sonografia para nódulos tireoidianos. *Rev Bras Cir Cabeça Pescoço*, v. 36, n. 4, p. 186-90, 2007.
14. RODRIGUES, G. F. T. *et al.* Nódulo tireoideano: correlação entre achados da punção aspirativa por agulha fina e exame histopatológico. *ACTA ORL/Técnicas em Otorrinolaringologia*, v. 25, n. 3, p. 229-31, 2007.
15. VAISMAN, M. *Rotinas diagnósticas e terapêuticas: serviço de endocrinologia do Hospital Universitário Clementino Fraga Filho, UFRJ.* São Paulo: Editora Atheneu, 2009.
16. YANG, J.; SCHNADIG, V.; LOGRONO, R.; WASSERMAN, P. G. Fine-needle aspiration of thyroid nodules: a study of 4703 patients with histologic and clinical correlations. *Cancer*, v. 111, n. 5, p. 306-15, 2007.

---

**MAILING ADDRESS**

Vanessa Bordin  
Av. General Osório, 305 D, apto 303; Centro; CEP: 89802-210; Chapecó- SC, Brazil; e-mail: vanebordin@unochapeco.edu.br.