

Primary gastric melanoma: a case report of a rare malignancy

Melanoma gástrico primário: relato de caso de uma neoplasia maligna rara

Raquel Ida Ferreira¹; Leonardo C. Dentz²; Emílio Augusto C. P. Assis²; Renato S. Laboissière¹

1. Faculdade de Medicina de Barbacena, Barbacena, Minas Gerais, Brazil.

2. Centro de Investigação Diagnóstica em Anatomia Patológica (CIDAP), Juiz de Fora, Minas Gerais, Brazil.

ABSTRACT

Noncutaneous melanoma is a rare clinical entity, and their primary or secondary nature is often difficult to establish. Few cases of primary gastric melanoma have been described in the literature. We report a case of a 55-year-old male patient with dyspepsia complaints. Esophagogastroduodenoscopy revealed a polypoid mass with blackened areas at the greater curvature of the gastric body, which was histologically compatible with melanoma; positive immunohistochemistry for S100, melan-A, and vimentin. The extensive dermatological exam did not identify a primary lesion.

Key words: melanoma; immunohistochemistry; gastric neoplasms.

RESUMO

Melanoma extracutâneo é uma entidade clínica rara, e sua natureza primária ou secundária é difícil de ser estabelecida. Poucos casos de melanoma gástrico primário são descritos na literatura. Relatamos o caso de um paciente do sexo masculino, 55 anos, com queixas dispépticas. A esofagogastroduodenoscopia revelou lesão polipoide com áreas enegrecidas na grande curvatura do corpo gástrico, histologicamente compatível com melanoma; imuno-histoquímica positiva para proteína S100, melan-A e vimentina. O exame dermatológico extenso não identificou lesão primária.

Unitermos: melanoma; imuno-histoquímica; neoplasias gástricas.

RESUMEN

El melanoma extracutáneo es una entidad clínica rara, y es difícil identificar su naturaleza primaria o secundaria. Hay pocos casos de melanoma gástrico primario descritos en la literatura. Reportamos el caso de un paciente masculino, de 55 años de edad con síntomas dispépticos. La esofagogastroduodenoscopia reveló lesión polipoidea con zonas ennegrecidas en la curvatura mayor del cuerpo gástrico, histológicamente compatible con melanoma; inmunohistoquímica positiva para S100, melan-A y vimentina. El examen dermatológico completo no identificó lesión primaria.

Palabras clave: melanoma; inmunohistoquímica; neoplasias gástricas.

INTRODUCTION

Malignant melanoma is a neoplasm that originates from melanocytes, pigmented dendritic cells located in the basal layer of the epidermis, in the hair bulb, eyes, ears, and meninges^(1, 2). Approximately 92% of melanomas are cutaneous⁽²⁾; only 1.2% of noncutaneous melanomas are located in mucous membranes. The primary gastrointestinal tract involvement is more common at the anorectal site of incidence^(2, 3). Cases of primary gastric melanomas are rare; in the literature, about 15 cases are described^(2, 4).

Environmental, immune, hereditary risk factors and association with other comorbidities are pointed out in the pathogenesis of primary gastric melanoma, however, with no established consensus⁽¹⁾. The worst prognosis of gastric melanoma is caused by late diagnosis due to the need for invasive exams to visualize the lesion, in addition to nonspecific signs and symptoms^(3, 4).

OBJECTIVE

Report a rare case of primary gastric malignant melanoma with unfavorable outcome.

CASE REPORT

Male patient, 55 years old, with a history of epigastric pain after meals for 60 days. Esophagogastroduodenoscopy (EGD) [upper gastrointestinal endoscopy (UGI)] revealed a diffuse rash in the gastric antrum and polypoid lesion with blackened areas in the great curvature of the body. Histological examination of gastric antrum biopsy showed no structural or inflammatory changes. However, the histological study of the lesion of the gastric body showed a little differentiated invasive malignant neoplasia with cells in solid and trabecular arrangement with ulceration, but without the presence of melanocytic pigment (**Figure 1**). Immunohistochemical analysis was positive for cytokeratins 8/18 of low molecular weight, S100 protein, melan-A, vimentin and HMB45, compatible with ulcerated and infiltrative malignant melanoma (**Figure 2**). Genetic analysis revealed a V600E mutation of the *BRAF* gene.

During the complete dermatological investigation, previous and current primary sources for cutaneous melanoma were not found.

The patient underwent total gastrectomy with Roux-en-Y reconstruction. The previous diagnosis of gastric melanoma has

been confirmed. The lymph nodes of the small and large curvature were negative for metastases. Despite the efforts, the patient presented complications inherent to the postoperative period, evolving to death in two weeks.

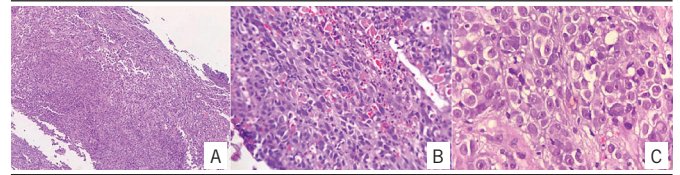


FIGURE 1 – HE staining of gastric body polypoid lesion biopsy, at magnification of 10× (A), 40× (B), and 100× (C)

HE: hematoxylin and eosin.

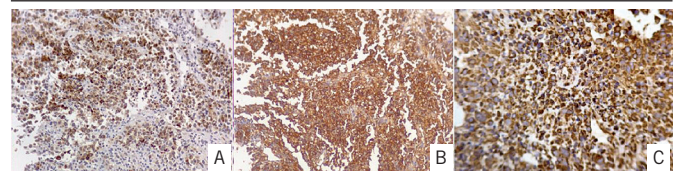


FIGURE 2 – Positive immunohistochemistry for melan-A (A), S100 (B), and vimentin (C)

DISCUSSION

The pathogenesis of primary gastric melanoma is not fully understood, since the normal gastric epithelium does not contain melanocytes⁽³⁾. Different hypotheses about the appearance of primary gastric melanoma are reported^(3, 5). The first theory points to the probable ectopic migration of melanocytic precursors, suggested by the observation of benign melanosis in neoplasms of the gastrointestinal tract⁽⁵⁾. Another possibility is the differentiation of APUD cells to melanocytes, since derivatives of the neural crest can maintain the capacity for differentiation and, consequently, undergo malignant transformation^(3, 5).

The diagnostic criteria for primary gastric melanoma include: 1. a single melanoma lesion in the stomach proven by pathology; 2. absence of lesions elsewhere on the body; 3. negative personal history for melanoma; 4. disease-free survival of at least, 12 months after curative surgery⁽⁶⁾. In the case reported, it was not possible to assess disease-free survival after gastrectomy, as the patient died due to intrinsic complications of the surgical procedure. More than 60% of patients with cutaneous melanomas have gastric metastases, therefore, dermatological evaluation is essential⁽¹⁾.

Manifestations of primary gastric melanoma are similar to those of other gastric tumors, such as anemia, weight loss, nausea, vomiting, abdominal pain and gastrointestinal bleeding^(1, 4, 7). Most patients remain asymptomatic until the

cancer becomes advanced⁽⁴⁾. Upper digestive endoscopy and biopsy are the main diagnostic tests⁽⁴⁾. In the former, it is possible to verify the presence of a blackened lesion, as in our report⁽⁴⁾. In the case of this patient, gastric biopsy was devoid of melanocytic pigment, which made diagnosis difficult under conventional microscopy. Thus, the role of immunohistochemistry is highlighted, since the positive staining for HMB45, S100 and melan-A confirms the presence of melanocytes in the mucosa^(1, 4). Despite this, the preoperative diagnosis is challenging, since melanomas with little or no melanin can mimic other tumors, such as lymphoma and poorly differentiated carcinoma⁽⁷⁾.

Mutations of the *BRAF* gene affect more than 50% of cases of cutaneous melanoma, however, they are rare in mucosal melanomas⁽⁷⁾. Genetic testing in primary gastric melanoma is mandatory, as it allows targeting therapies for specific mutations⁽⁷⁾.

There is no standard protocol for treatment due to few cases reported in the literature^(2, 4, 6, 7). Tumor resection has the best results in reducing symptoms and improving survival^(4, 6, 7). Other therapeutic options such as chemotherapy with interferon or

interleukin-12, radiotherapy and immunotherapy are still being studied⁽²⁾.

Mucous melanomas are more associated with a worse prognosis than cutaneous melanomas due to the frequent delay in reaching the diagnosis, the inherently more aggressive nature of the tumor and the early dissemination by the rich lymphatic and vascular supply of the gastrointestinal mucosa^(1, 4, 8). The main predictors of prognosis at the time of diagnosis are the advanced stage of the tumor, failure to perform surgical resection, positive lymph node status, and age⁽⁵⁾. The median survival time is five months^(1, 2, 7).

CONCLUSION

Primary gastric melanoma is a very uncommon clinical entity and can be underdiagnosed mainly due to its non-specific clinical manifestation. Early detection and surgical intervention are critical for improving survival, although the overall prognosis is poor.

REFERENCES

1. Lagoudianakis EE, Genetzakis M, Tsekouras DK, et al. Primary gastric melanoma: a case report. *World J Gastroenterol* 2006 July 21; 12(27): 4425-7. PubMed PMID: 16865791.
2. Aggarwal R, Dhawan S, Chopra P. Primary gastric melanoma: a diagnostic challenge. *J Gastrointest Cancer*. 2014; 45(S1): 33-5. PubMed PMID: 23912608.
3. Bishop KD, Olszewsk AJ. Epidemiology and survival outcomes of ocular and mucosal melanomas: a population-based analysis. *Int J Cancer*. 2014; 134: 2961-71. PubMed PMID: 24272143.
4. Anupama R. Primary gastric melanoma: a rare cause of upper gastrointestinal bleeding. *Gastroenterol Hepatol*. 2008; 4(11): 795-7. PubMed PMID: 21960901.
5. Augustyn A, Leon ED, Yopp AC. Primary gastric melanoma: case report of a rare malignancy. *Rare Tumors*. 2015; 7: 46-9. PubMed PMID: 25918612.
6. Callaghan GM, Kellher FC, Crowther S, Alakkari A, Ryan BM. A case of primary gastric melanoma exhibiting a rare BRAF V600R mutation. *Eur J Case Rep Intern Med*. 2018; 5(3): 000749. PubMed PMID: 30756014.
7. Song W, Liu F, Wang S, Shi H, He W, He Y. Primary gastric malignant melanoma: challenge in preoperative diagnosis. *Int J Clin Exp Pathol*. 2014; 7(10): 6826-31. PubMed PMID: 2540076.
8. Yamamura K, Kondo K, Moritani S. Primary malignant melanoma of the stomach: report of a case. *Surg Today*. 2012; 42(2): 195-9. PubMed PMID: 22167480.

CORRESPONDING AUTHOR

Raquel Ida Ferreira  0000-0003-1533-8971
e-mail: raquelferreiraida@yahoo.com



This is an open-access article distributed under the terms of the Creative Commons Attribution License.