

Intratesticular and intraovarian epidermoid inclusion cysts: report of two cases

Cistos de inclusão epidérmica intratesticular e intraovariano: relato de dois casos

Guilherme José Morgan¹; Taniela Marli Bes²; Ingrid Berger Severo²; Eduardo de Barros Coelho Bicca³; Heitor Alberto Jannke⁴

ABSTRACT

Two rare cases of intragonadal epidermoid inclusion cysts are described. Their etiology remains controversial and a possible hypothesis is monodermal abortive teratomas, with no mesodermal and endodermal components. As the ultrasound test results were inconclusive, it became difficult to rule out the possibility of neoplasm. Therefore, patients were submitted to radical therapy. The definitive diagnosis for both cases was provided by the anatomopathological examination.

Key words: epidermal cyst; ovary; testis; gonadal disorders.

INTRODUCTION

Ovarian tumors constitute a major challenge to gynecological clinical practice due to the wide variety of histological types (benign and malignant), which are possible owing to the embryological characteristics of the gonad. These tumors contain elements originated from the three embryonic germ layers. Epidermoid cysts are extremely rare among ovarian pathologies^(8, 12), corresponding to approximately 40 cases reported in the literature. They represent less than 1% of gonadal tumors, hence their origin still remains uncertain^(8, 9).

Although 95% of testicular tumors are malignant, the accurate characterization of benign lesions in the pre-operative phase is crucial so that a less aggressive treatment may be provided⁽¹⁰⁾. Epidermoid cysts are uncommon non-germ cell tumors, with approximately 1% prevalence of testicular mass^(4, 6, 11), which present a benign behavior, though they simulate neoplastic lesions. Their histogenesis is also unknown, but the most accepted hypothesis proposes that the ovarian and testicular epidermoid cysts are monodermal variants of teratoma^(1, 4). In both cases, the clinical and radiological diagnoses are unspecific and the traditional approaches are orchiectomy^(4, 6) and oophorectomy, although currently some investigators propose the use of testicular tumorectomy in specific situations.

We report two rare cases of benign epidermoid inclusion cysts simulating neoplasia in both gonads. The objective was to acknowledge the importance of the differential diagnosis of these pathologies arising in the testis and ovary, despite the fact they are infrequent and occur in unusual age groups, inasmuch as their surmise may lead to a more conservative surgery, due to the benignity of the lesions.

CASE REPORT 1

15 year-old male patient presented a 2 cm diameter painless nodule in the left testis for eight months. There was no history of trauma, infection or other systemic symptoms. The ultrasonographic imaging of the scrotum revealed a nodule with irregular borders and heterogeneous echotexture. The laboratory exams yielded the following results: lactate dehydrogenase (LDH) 366 U/l, alpha-fetoprotein 0.69 mg/ml and human chorionic gonadotropin 0.50 mIU/ml. The left orchiectomy was performed. The testis measured 4.8 × 3.2 × 3 cm. The nodular lesion was well defined, peripheral, polar, whitish, matt and friable, measuring 1.5 × 1.5 × 1.4 cm (**Figure 1**). The microscopic exam revealed the presence of a unique epidermoid inclusion cyst filled with keratin and with no evidence of malignity. (**Figure 2**).

First submission on 06/11/12; last submission on 25/02/13; accepted for publication on 25/02/13; published on 20/04/13

1. Medical graduate student at Universidade Católica de Pelotas.

2. Medical graduate student at Universidade Católica de Pelotas.

3. Master's degree in Health and Behavior; associate professor of Pathology at Universidade Católica de Pelotas.

4. Doctor in Pathology; pathologist; professor at Universidade Católica de Pelotas.

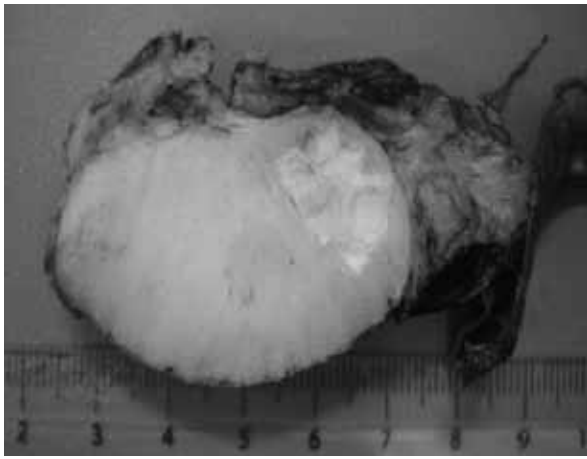


FIGURE 1 – Macrophotograph of testis section displaying polar cyst with pasty and whitish content

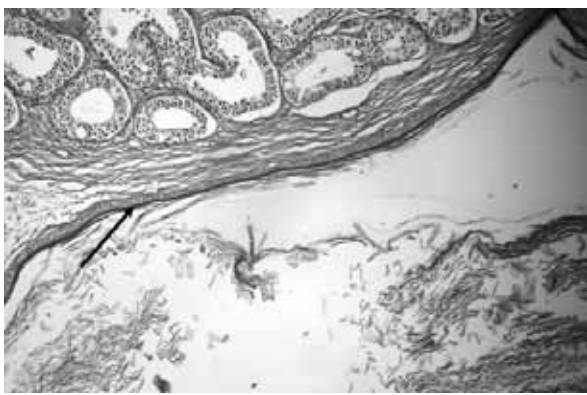


FIGURE 2 – Microphotograph displaying transition of testicular tissue and adjacent cystic formation with squamous lining (arrow) (HE, 100×)
HE: hematoxylin and eosin.

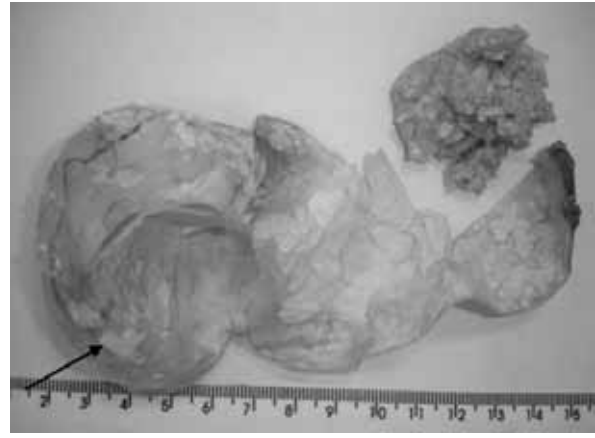

FIGURE 3 – Photograph of uniloculated ovarian cavity cystic formation with keratin residues (arrow)

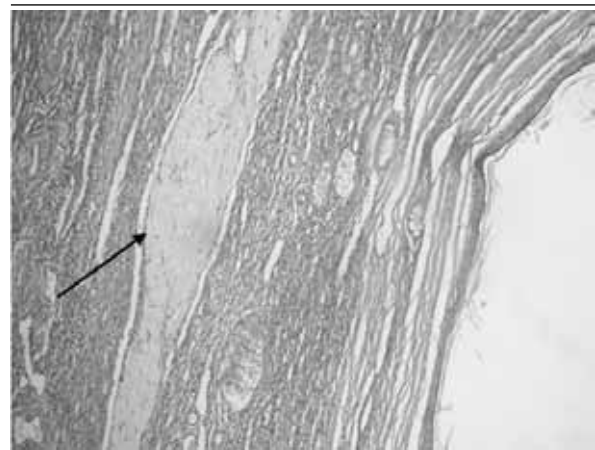


FIGURE 4 – Section of ovarian wall including corpus albicans (arrow) and squamous-lined cyst to the right (HE, 100×)
HE: hematoxylin and eosin.

CASE REPORT 2

34 year-old female patient sought medical treatment due to a painless irregular uterine bleeding, showing no improvement with pharmacological treatment. The pelvic ultrasonographic imaging evinced a cystic mass in the topography of the right uterine appendage. The right salpingo-ooforectomy was performed. The anatomopathological exam of the microscopic section showed a grayish smooth cystic lesion filled with friable and brownish residue in the ovary (**Figure 3**). The internal surface was grayish and squamous. The microscopy revealed a uniloculated cyst covered exclusively with squamous epithelium containing cornoid lamellae and no evidence of malignancy (**Figures 4 and 5**).

DISCUSSION

In most cases, solid testicular masses suggest malignancy, mainly when they are corroborated by ultrasonographic imaging⁽⁴⁾.

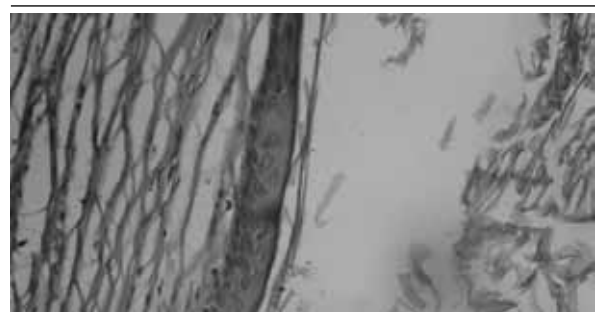

FIGURE 5 – Microphotograph at high magnification displaying squamous epithelium lining and cornoid lamellae to the right (HE, 400×)
HE: hematoxylin and eosin.

However, despite the fact intratesticular benign tumors are rare, their acknowledgment may allow the preservation of the testis⁽⁴⁾. On the other hand, primary squamous cell carcinomas are uncommon. They usually stem from germ cells originated from mature teratomas.

Squamous cell carcinomas not associated with teratomas are extremely rare⁽⁹⁾.

Epidermoid cysts are usually asymptomatic and unilateral. Testicular epidermoid cysts are commonly detected during self-exam or routine physical exam^(1, 4). Most patients are between the second and fourth decades of life^(1, 4, 10), whereas ovarian cysts are more frequent in the fifth decade of life onwards⁽⁹⁾.

The World Health Organization (WHO) classifies the ovarian epidermoid cysts as highly differentiated monodermal teratomas. The main interest in the investigation of this pathology involves its histogenesis, which remains uncertain. Some hypotheses include cystic dilation, squamous metaplasia of surface epithelial inclusion cyst, skin graft during previous surgery, development of monodermal teratoma and mucosa metaplasia of endometriosis cyst⁽²⁾. Nevertheless, the most accepted hypothesis, including the testicular cases, is mature monodermal teratoma, only with expression of ectodermal component^(5, 9-11).

In terms of microscopy, the epidermoid cyst is usually circumscribed, firm, smooth, whitish and with fibrous aspect. The transversal section reveals only one cystic cavity filled with yellowish concentric cornoid lamellae^(9, 11). Some calcium foci may be present⁽¹¹⁾. The criteria that allow the differentiation between simple epidermoid teratoma cyst and dermoid cyst comprise the following aspects: lesion containing keratin in the lumen, keratin without teratoma elements, cyst wall constituted of fibrous tissue with squamous epithelium and the remaining atrophic testicular parenchyma without teratoma elements^(6, 10, 11).

Ultrasonographic imaging remains a diagnostic choice in testicular pathology and it is the most applied non-invasive diagnostic method to assess the ovary⁽⁶⁾. It may show a circumscribed hypochoic lesion with hyperechoic borders due to the laminated keratin inside the cyst. Due to calcification of intraluminal content, there may be echogenic center, hence the echotexture of these masses

may vary from exclusively cystic to echogenic and non homogeneous. Therefore, it is the most applied auxiliary method for varied and unspecific findings^(7, 10).

As to the most import differential diagnosis, specifically testicular teratoma among individuals in post-puberty, abnormalities in chromosome 12p (isochromosome 12p12p [i(12p)] and/or overrepresentation of 12p) are found in most germ-cell tumors and they are also observed in other histological subtypes. Epidermoid cysts do not present these genetic abnormalities. The analysis through fluorescence in situ hybridization (FISH) is the most sensitive method for the detection of i(12p), including paraffin embedded samples^(5, 13). In ovarian cysts, there is also an abnormality in chromosome 12p in germ-cell tumors with exception of pure ovarian teratoma⁽¹³⁾.

Owing to the difficulty in differentiating epidermoid cysts from malignant testicular lesions, orchiectomy was the standard treatment when there was no thorough pathological exam or genetic investigation. When preoperative diagnosis is established, tumorectomy with preservation of the remaining testis is a viable alternative. When the diagnosis is inconclusive until the moment of surgery, the transoperative anatomopathological exam is performed when available^(4, 6, 10, 11). Similarly, oophorectomy is the standard procedure in ovary cysts.

CONCLUSION

The study of both cases highlights the importance of the histopathological diagnosis of epidermoid cysts with a view to differentiate them from teratomas, inasmuch as the benign behavior of the former allows a conservative therapeutic approach, ultimately preserving the reproductive function.

RESUMO

Trata-se de dois casos raros de cistos de inclusão epidérmica intragonadais, cuja etiologia permanece controversa, sendo uma hipótese a de teratomas monodérmicos abortivos, sem componentes mesodérmicos e endodérmicos. Devido a resultados inespecíficos dos exames ultrassonográficos, torna-se difícil afastar a possibilidade de neoplasia e o tratamento padrão permanece sendo, portanto, a terapia radical. O diagnóstico definitivo, em ambos os casos, foi firmado pelo exame anatomopatológico.

Unitermos: cisto epidérmico; ovário; testículos; transtornos gonadais.

REFERENCES

1. ANEIROS-FERNANDEZ, J. *et al.* Intratesticular epidermoid cyst: a rare tumor. *J Clin Med Res*, v. 2, n. 6, p. 281-3, 2010.
2. CHATZISTAMOU, I. *et al.* Retrospective study of teratomas of the ovary reveals a high incidence of epidermoid cysts. *Gynecol Oncol*, v. 101, n. 3, p. 548-52, 2006.
3. CHENG, L. *et al.* Interphase fluorescence in situ hybridization analysis of chromosome 12p abnormalities is useful for distinguishing epidermoid

- cysts of the testis from pure mature teratoma. *Clin Cancer Res*, v. 12, n. 19, p. 5668-72, 2006.
4. CHIONG, E. *et al.* Uncommon benign intrascrotal tumours. *Ann Acad Med Singapore*, v. 33, n. 3, p. 351-5, 2004.
 5. FAN, L. D.; ZANG, H. Y.; ZHANG, X. S. Ovarian epidermoid cyst: report of eight cases. *Int J Gynecol Pathol*, v. 15, n. 1, p. 69-71, 1996.
 6. GUPTA, S. K. *et al.* Epidermoid cysts of the testis: the case for conservative surgery. *Ann R Coll Surg Engl*, v. 82, n. 6, p. 411-3, 2000.
 7. HERNANDEZ, R. J.; BUADU, A. Case report of a testicular epidermoid cyst and review of its typical sonographic features. *J Radiol Case Rep*, v. 4, n. 9, p. 18-23, 2010.
 8. IDRESS, R. *et al.* Epidermoid cyst of the ovary. *J Pak Med Assoc*, v. 57, n. 5, p. 263-4, 2007.
 9. KHEDMATI, F.; CHIROLAS, C.; SEIDMAN, J. D. Ovarian and paraovarian squamous-lined cysts (epidermoid cysts): a clinicopathologic study of 18 cases with comparison to mature cystic teratomas. *Int J Gynecol Pathol*, v. 28, n. 2, p. 193-6, 2009.
 10. KLIEWER, M. A.; CARROLL, B. A. Ultrasound case of the day. *RadioGraphics*, v. 11, n. 1, p. 159-60, 1991.
 11. MILLER, E. V. Benign testis tumor: epidermoid testicular cyst. *J Natl Med Assoc*, v. 67, n. 1, p. 48-9, 1975.
 12. NOGALES, F. F.; SILVERBERG, S. G. Epidermoid cysts of the ovary: a report of five cases with histogenetic considerations and ultrastructural findings. *Am J Obstet Gynecol*, v. 124, n. 5, p. 523-8, 1976.
 13. POULOS, C. *et al.* Analysis of ovarian teratomas for isochromosome 12p: evidence supporting a dual histogenetic pathway for teratomatous elements. *Mod Pathol*, v. 19, n. 6, p. 766-71, 2006.
 14. TERADA, T. Mixed epidermal cyst and mucinous cystadenoma of the ovary: a hitherto unreported entity. *Arch Gynecol Obstet*, v. 285, n. 5, p. 1489-91, 2012.

MAILING ADDRESS

Guilherme José Morgan
Rua Santa Cruz, 1.470, apto 1.505; Centro; CEP: 96015-710; Pelotas-RS, Brazil; e-mail: guilherme_morgan_npi@hotmail.com.