

# Fetal anencephaly with umbilical cord attached to cerebrovasculosa area: autopsy report

## *Anencefalia fetal com cordão umbilical aderido à área cerebrovasculosa: relato da autópsia*

Stephan Philip L. Altmayer<sup>1</sup>; McArthur Alex Barrow<sup>1</sup>; Maiara A. Floriani<sup>1</sup>; Glauco K. Nagata<sup>1</sup>; Matheus Zanon<sup>1</sup>; André C. Cunha<sup>2</sup>; Paulo Renato Krahl Fell<sup>2</sup>; Cristine Dietrich<sup>2</sup>; Paulo Ricardo G. Zen<sup>1,3</sup>; Rafael Fabiano M. Rosa<sup>1,3</sup>

1. Universidade Federal de Ciências da Saúde de Porto Alegre (UFCSA), Porto Alegre, Rio Grande do Sul, Brazil. 2. Hospital Materno-Infantil Presidente Vargas (HMIPV), Porto Alegre, Rio Grande do Sul, Brazil. 3. Santa Casa de Misericórdia de Porto Alegre (SCMCPA), Porto Alegre, Rio Grande do Sul, Brazil.

### ABSTRACT

Our aim was to report the unusual case of an anencephalic fetus that was born with the umbilical cord attached to its cephalic pole. The patient was a 16-year-old pregnant woman. Ultrasound evaluation at 17 weeks revealed a single fetus without cranial vault and brain parenchyma, compatible with anencephaly. Postnatal evaluation, through an autopsy, was consistent with this diagnosis. Moreover, it was observed that the umbilical cord was attached to the area cerebrovasculosa and there was the presence of a fibrous tissue, suggestive of an amniotic band. We have found only one similar case described in the literature.

**Key words:** anencephaly; umbilical cord; amniotic band syndrome.

### RESUMO

*Relatamos um caso incomum de feto com anencefalia nascido com o cordão umbilical aderido à área cerebrovasculosa. A gestante tinha 16 anos de idade. A avaliação pela ultrassonografia, na 17ª semana de gestação, revelou feto sem calota craniana e parênquima cerebral, compatível com anencefalia. A avaliação pós-natal, através da autópsia, foi concordante com esse diagnóstico. Ademais, notou-se que o cordão umbilical estava aderido à área cerebrovasculosa, visto que havia a presença de tecido fibroso, sugestivo de uma banda amniótica. Encontramos apenas um caso semelhante descrito na literatura.*

*Unitermos:* anencefalia; cordão umbilical; síndrome de bandas amnióticas.

### RESUMEN

*Reportamos el caso poco usual de un feto anencéfalo nacido con el cordón umbilical adherido al área cerebrovasculosa. La embarazada tenía 16 años de edad. La ecografía de la semana 17 de gestación mostró un feto sin bóveda craneal y parénquima cerebral, compatible con anencefalia. La evaluación posnatal, mediante autopsia, estaba de acuerdo a ese diagnóstico. Además, se ha notado que el cordón umbilical estaba adherido al área cerebrovasculosa, puesto que había presencia de tejido fibroso, sugestivo de banda amniótica. Encontramos solo un caso descrito en la literatura.*

*Palabras clave:* anencefalia; cordón umbilical; síndrome de banda amnióticas.

## INTRODUCTION

Anencephaly is considered one of the most common and severe congenital malformations of the central nervous system<sup>(1)</sup>. It is characterized by a congenital absence of most of the brain, skull and scalp due to a failure in the closure of the cephalic neural tube. This failure occurs at around four weeks of gestational age<sup>(1,2)</sup>. Its frequency has been estimated in 1 per 1,000 newborns in the United States<sup>(1)</sup>, and 0.7 to 1.3 per 1,000 newborns have been reported in Brazil<sup>(3,4)</sup>. The etiology of anencephaly is associated with genetic or environmental factors, in isolation or interactively<sup>(1)</sup>. Several genes are related to neural tube closure, most of which are associated with folic acid metabolism, such as the 5,10-methylenetetrahydrofolate reductase gene (*MTHFR*). Environmental factors involved include pregestational diabetes, folic acid deficiency and gestational exposure to anticonvulsant drugs (particularly sodium valproate and carbamazepine)<sup>(1,3,5)</sup>. Our report aims to describe an unusual case of an anencephalic fetus that was born with the umbilical cord attached to its cephalic pole.

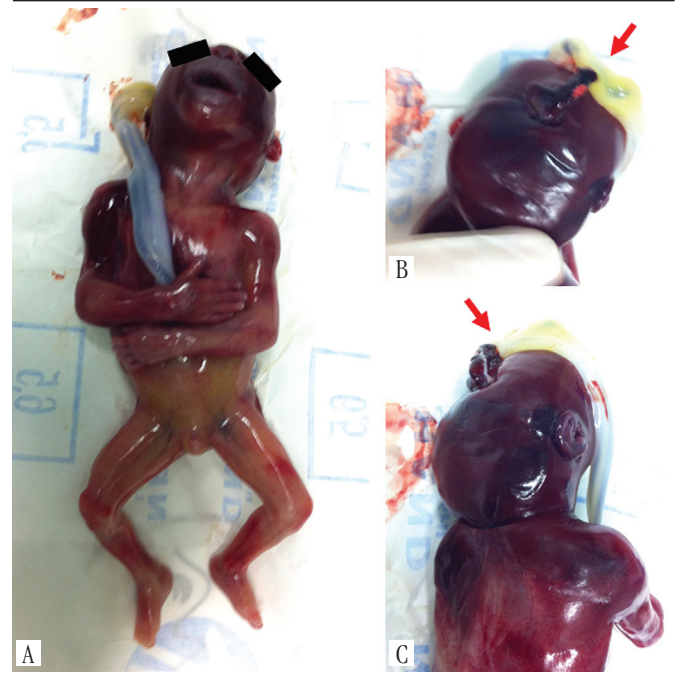
## CASE REPORT

A 16-year-old primiparous pregnant woman was evaluated at the Fetal Medicine Service of a reference hospital due to an obstetric ultrasound (US) suggestive of a defective closure of neural tube at the 16<sup>th</sup> week of gestation. She denied any medical problem and use of medications (including folic acid supplementation) during pregnancy, except for a history of epilepsy treated with phenobarbital until two years before pregnancy. She smoked up to the third month and had occasional alcohol intake during pregnancy. Prenatal serologies were all negative. The partner was a 17-year-old healthy and non-consanguineous man. Family history was positive for a stillbirth with cerebral malformation from her grandmother. There is no description of individuals affected by neural tube defects, including anencephaly.

A new fetal US performed at 17 weeks revealed the presence of a single fetus with absence of the cranial vault and brain parenchyma, what was compatible with anencephaly. In this evaluation, there was no description of the position of the umbilical cord in relation to the fetus. The woman had a legal termination of pregnancy in the week following the diagnosis.

Postnatal autopsy confirmed anencephaly and revealed the fusion of the umbilical cord to the cerebrovasculosa area in the cephalic pole of the fetus. It also identified the presence of a fibrous tissue attached to umbilical cord and the cerebrovasculosa

area suggestive of an amniotic band (**Figure**). There were no other malformations in the fetus. Analysis of the placenta did not reveal any abnormality.



**FIGURE** – Postnatal appearance of the fetus showing the umbilical cord attached to the cephalic pole, in the area cerebrovasculosa (A-C). Along with these structures the presence of a fibrous tissue (see arrow) was also identified, what raised the possibility of an amniotic band (C)

## DISCUSSION

Our prenatal and postnatal findings were indicative of anencephaly. In this defect, the face and skull base bones are almost normal in shape, but the frontal, parietal and occipital bones are present only as rudimentary fragments. Usually this defect is symmetrical with bulging eyes, providing a frog appearance. The brain is seen as disorganized masses of hemorrhagic tissue and cerebrospinal fluid with cavities called cerebrovasculosa area, a vascular mass with disorganized neuroglial tissue<sup>(2)</sup>. The brainstem and cerebellum may be slightly affected or not affected in this condition<sup>(6)</sup>.

In Brazil, the frequency of anencephalic fetuses has decreased due to recent legal termination of pregnancy after the prenatal diagnosis. As the cranial defect is capable of being detected through US, the diagnosis of anencephaly can be readily obtained in the second and third trimesters of pregnancy in almost 100% of cases<sup>(7)</sup>.

Most of the neural tube defects, such as anencephaly, are attributable to genetic, environmental or both factors. It is noteworthy that these defects are associated with epilepsy<sup>(8)</sup>, a condition present in the mother's past history. In our literature review, we found only one case with a similar description, presenting an umbilical cord adhered to the cephalic pole. Harrington *et al.* (1992)<sup>(9)</sup> described a fetus with acrania diagnosed through US. Postnatal evaluation showed the presence of partial cranial destruction secondary to an amniotic band. This structure connected the umbilical cord and a membrane covering the protruded brain.

Amniotic bands have been proposed as the cause of several congenital anomalies that may affect different body structures, including neural tube-like defects<sup>(10)</sup>. The etiology of the amniotic bands is unknown. However, it has been linked to an amnion rupture during early pregnancy that leads to an entrapment and disruption of fetal structures by bands<sup>(11)</sup>. It is also worth noting that the mother of our fetus had a young maternal age and this feature has been related not only to anencephaly<sup>(2)</sup> but also amniotic bands<sup>(12)</sup>. Moreover, the association between anencephaly and amniotic bands, as apparently observed in our patient, has been reported in the literature<sup>(13)</sup>.

Acrania is a rare congenital defect in which the flat bones of the skull are partially or completely absent, with full but abnormal development of the cerebral hemispheres. Because of these features, it is often confused with anencephaly<sup>(14)</sup>. The acrania has been associated with several disorders, including amniotic bands<sup>(15)</sup>. It

is believed that acrania is the result of a failure of the migration of mesenchymal tissue, which leads to lack of development of the calvarial dermal bones of the skull<sup>(16)</sup>. In our case, in contrast to acrania, there was destruction of the brain, due to its exposure, which presented an aspect of hemorrhagic tissue, compatible with the cerebrovasculosa area.

After an infant with anencephaly, the risk of recurrence for a couple in subsequent pregnancies is 2% to 5%<sup>(16)</sup>. Differently from acrania and amniotic bands, most cases of anencephaly may be prevented by adequate folic acid supplementation<sup>(8, 17)</sup>. In the case of amniotic bands, although the etiology is not fully understood, the defects are usually considered sporadic, i.e., the parents of an affected child did not appear to have an increased risk of having another child with the same condition<sup>(9, 10)</sup>.

## CONCLUSION

---

Genetic counseling for this case can be difficult, since it depends on an accurate diagnosis and it may interfere with the couple plans to establish a family in the light of the higher risk of recurrence. Possibly, amniotic bands can explain both the defects of the skull and the rare finding of the umbilical cord attached to the cephalic pole observed in our fetus.

## REFERENCES

---

1. Botto LD, Moore CA, Khoury MJ, Erickson JD. Neural-tube defects. *N Engl J Med.* 1999; 341: 1509-19.
2. Calzolari F, Gambi B, Garani G, Tamisari L. Anencephaly: MRI findings and pathogenetic theories. *Pediatr Radiol.* 2004; 34: 1012-6.
3. Aguiar MJ, Campos AS, Aguiar RA, Lana AM, Magalhães RL, Babeto LT. Neural tube defects and associated factors in liveborn and stillborn infants. *J Pediatr.* 2003; 79: 129-34.
4. Fernández RR, Larentis DZ, Fontana T, et al. Anencephaly: thirteen years of epidemiological study in Pelotas city. *Cien Saude Colet.* 2005; 10: 185-90.
5. Greene ND, Copp AJ. Neural tube defects. *Annu Rev Neurosci.* 2014; 37: 221-42.
6. Johnson SP, Sebire NJ, Snijders RJ, Tunkel S, Nicolaidis KH. Ultrasound screening for anencephaly at 10-14 weeks of gestation. *Ultrasound Obstet Gynecol.* 1997; 9: 14-6.
7. Cameron M, Moran P. Prenatal screening and diagnosis of neural tube defects. *Prenat Diagn.* 2009; 29: 402-11.
8. Yerby MS. Clinical care of pregnant women with epilepsy: neural tube defects and folic acid supplementation. *Epilepsia.* 2003; 44 Suppl 3: 33-40.
9. Harrington BJ, Horger EO, Edwards JG. A counseling dilemma involving anencephaly, acrania and amniotic bands. *Genet Couns.* 1992; 3: 183-6.
10. Levy PA. Amniotic bands. *Pediatr Rev.* 1998; 19: 249.
11. Pettorini B, Abbas N, Magdum S. Amniotic band syndrome with tethering of the spinal cord: a case-based update. *Childs Nerv Syst.* 2011; 27: 211-4.
12. Werler MM, Louik C, Mitchell AA. Epidemiologic analysis of maternal factors and amniotic band defects. *Birth Defects Res A Clin Mol Teratol.* 2003; 67: 68-2.
13. Pelizzari E, Valdez CM, Picetti JS, et al. Characteristics of fetuses evaluated due to suspected anencephaly: a population-based cohort study in southern Brazil. *São Paulo Med J.* 2015; 133(2): 101-8.

14. Bianca S, Ingegrosi C, Auditore S, et al. Prenatal and postnatal findings of acrania. *Arch Gynecol Obstet.* 2007; 271: 256-8.
15. Chandran S, Lim MK, Yu VY. Fetal acalvaria with amniotic band syndrome. *Arch Dis Child Fetal Neonatal Ed.* 2000; 82: F11-3.
16. Weissman A, Diukman R, Auslender R. Fetal acrania: five new cases and review of the literature. *J Clin Ultrasound.* 1997; 25: 511-4.
17. Gorgal R, Ramalho C, Brandão O, Matias A, Montenegro N. Revisiting acrania: same phenotype, different aetiologies. *Fetal Diagn Ther.* 2011; 29: 166-70.

**CORRESPONDING AUTHOR**

---

Rafael Fabiano Machado Rosa  0000-0003-1317-642X  
e-mail: rfmrosa@gmail.com



This is an open-access article distributed under the terms of the Creative Commons Attribution License.