

Adenocarcinoma of the female urethra: a case report

Adenocarcinoma de uretra feminina: relato de caso

José de Carvalho Neto¹; Sydney C. Leão²; Ricardo Fakhouri¹; Roberto Gurgel¹; Julia Maria G. Dias¹; Nivaldo F. Vieira¹

1. Universidade Federal de Sergipe (UFS), Sergipe, Brazil. 2. Universidade Federal de São Paulo (Unifesp), São Paulo, Brazil.

ABSTRACT

The urethral adenocarcinoma is a rare malignant tumor that affects predominantly women. Its incidence is higher after the age of 50 in this group. The knowledge about this disease is limited due to its low frequency and is mainly based on case reports. Although rarely presenting distant metastasis, the clinical consequences of treating this condition may bring an important negative impact on patient's quality of life. This is mainly due to mutilating surgery and the need to use permanent urinary catheter. It is presented a case report of a patient with urethral adenocarcinoma and its therapeutic management.

Key words: adenocarcinoma; urethral neoplasms; women's health; case reports.

INTRODUCTION

The urethral adenocarcinoma is a rare neoplasm, more prevalent among women than in men, accounting for 0.02% of malignant tumors in females⁽¹⁻³⁾. Lack of knowledge about this disease is notorious, the transmission of knowledge is made only by case reports^(2, 4). In Brazil there are few reports of the disease, due to its low incidence. As any cancer, early diagnosis is necessary, which would reduce the risk of metastasis so that the patient does not need a more aggressive surgical approach to control the progression of the disease⁽⁵⁾. Furthermore, as a result of the surgery, the patient may become dependent on the urinary catheter. In this paper, we report the case of a 54 years old woman, with this tumor that evolved invading the vagina and clitoris. A special feature is that this case reinforces the suspected relationship between urethral adenocarcinoma with the smoking habit, observed in other reports⁽⁴⁾.

CASE REPORT

M. Z. R. S., 54 years old divorced merchant, presenting pain and burning sensation in the urethra and stranguria, urinary retention and sero-bloody discharge with stoppers of mucopurulent material.

The patient was treated for urinary tract infection carrier for one year with recurrent use of ciprofloxacin, without improvement. After one year of symptoms, she underwent surgery followed by biopsy on suspicion of caruncle, but she had recurrent urethral pain. The biopsy performed in this surgery was inconclusive. Then, a second surgery after the biopsy was performed, in which urethral adenocarcinoma was diagnosed.

After diagnosis, the patient underwent surgery with extended radical vulvectomy and ureterectomy, evolving with the use of indwelling urinary catheter, as well as two sessions of radiotherapy. Currently, she remains free of recurrence after two years of follow up. As pathological history, the patient is a smoker, has a family history of breast and cervical cancer. Regarding gynecological history, she had five pregnancies – three births and two abortions, her menarche was at 10 years old and menopause was at 44 years old.

Regarding the macroscopic observation, the lesion was whitish and with vegetative aspect at the urethral meatus, involving the entire urethra. In the histological sections, the tumor tissue showed stromal infiltrated by mucous-secreting malignant signet-ring cells (**Figure 1**), with moderate pleomorphism, low mitotic index, releasing large amounts of mucin into the interstitial space (**Figure 1**); presenting focal tubular arrangements (**Figure 2**). There was no blood or lymphatic vascular infiltration by the

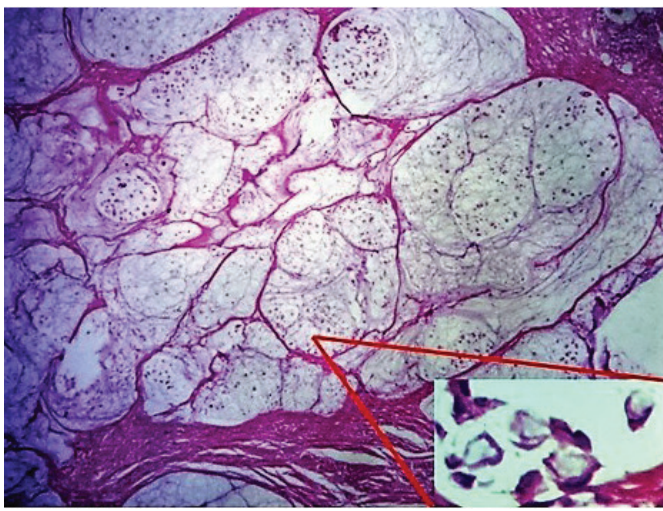


FIGURE 1 – Photomicrograph showing areas with mucinous differentiation in urethral adenocarcinoma (100×). In detail (right and below), neoplastic cells with signet-ring appearance (400×)

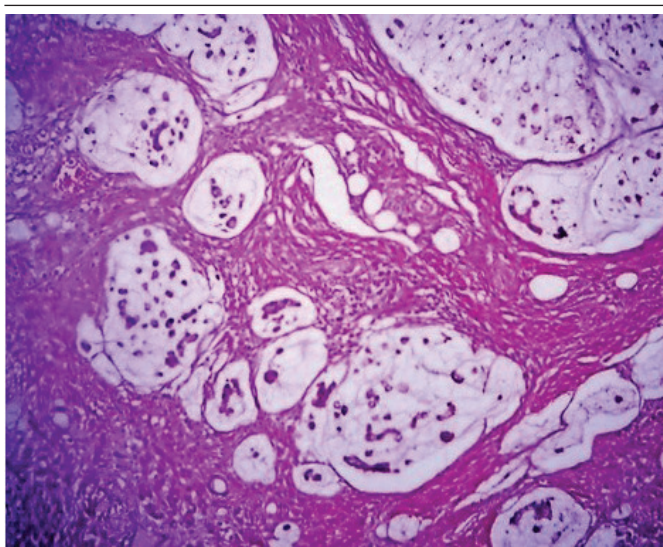


FIGURE 2 – Photomicrograph showing solid areas and areas with mucinous differentiation in urethral adenocarcinoma (200×)

tumor, but there was perineural infiltration. Also, there was no periurethral drilling, however, this region was infiltrated by the tumor. It was also observed impaired adventitia in a focus of tumor with metastasis by contiguity to the vagina. No lymph nodes were identified in the surgical specimen and the surgical resection margins were free of neoplastic involvement. The pathological stage was pT3, pNx, pMx.

The immunohistochemical study was positive for low molecular weight cytokeratin, CDX-2, cytokeratin-7 and PAX-8; however the staining for prostate specific antigen (PSA), p16 and cytokeratin 20 were negative⁽⁴⁾.

DISCUSSION

The female urethral carcinoma is a disease with low prevalence, which corresponds to 0.02% of all cases of malignant tumors in women; and accounting for 5% of cases among urological tumors in women^(2, 3). Urethral (adeno)carcinomas are usually classified by the cell presentation type. Our case can be classified as a variant type of mucin-secreting cells. In terms of overall prevalence, among men and women, urothelial carcinoma (transitional cell) is the most common histological type, accounting for 54%-65% of cases; the squamous cell corresponds to 16%-22% of cases; and adenocarcinoma accounts for 10%-16% of cases of urethral carcinoma⁽⁶⁾. Surveys on urethral carcinoma in women in the Netherlands performed by the National Cancer Registry of the Netherlands, demonstrated prevalence in that country of urothelial carcinomas (transitional cell) in 45% of cases, adenocarcinoma in 29%, and squamous cell carcinoma in 19% of new cases⁽⁷⁾. These data contrast with a previous research, pointing squamous cell carcinoma as the most common among women⁽⁸⁾.

Primary urethral adenocarcinoma in women has been divided into two primary histologic subtypes: clear-cell and mucinous or intestinal type⁽³⁾. Mucinous urethral adenocarcinoma usually contains abundant extra cellular mucin, resembling mucinous carcinoma of the colon and rectum^(7, 8). Mucinous primary adenocarcinoma of the female urethra is very rare, with less than 30 cases reported in the literature⁽⁶⁻⁸⁾. The clear-cell adenocarcinoma is the rarest, occurring most commonly in women than in men and its embryologic origin has not yet been clarified^(4, 9, 10). It is suggested that the clear-cell adenocarcinoma is derived from more than one tissue and, despite high levels of mitosis and necrosis is the one with the best prognosis among urethral cancers.

Urethral adenocarcinoma, both the variant mucin-secreting cells as the clear cell variant, may be originated from Skene glands and paraurethral ducts, homologous with the prostate gland in males, because it was found immunohistochemical expression of PSA in some cases^(4, 9). The PSA marker is found in one of every twelve cases. There is no evidence that all adenocarcinomas have this origin, since 90% of tumors that present PSA continue to present it, no matter how lush is the atypia⁽¹⁰⁾. The presence of reactivity of mAbDAS-1 marker indicates relationship of female urethral adenocarcinoma to the intestinal metaplasia, which is related to a chronic inflammation of the urethral glands (glandular urethritis)⁽¹¹⁾. Furthermore, there is an hypothesis that the urethral adenocarcinoma can be derived from the mesonephric duct or intermediate mesoderm remnants⁽⁹⁾.

Studies indicate a higher incidence of female urethral adenocarcinoma after 50 years of age. But there are some case reports with lower age⁽⁴⁾. Regarding the association of risk factors,

there is a great suggestion that this type of cancer is related to smoking^(4, 12). Other authors also suggest other risk factors for urethral adenocarcinoma such as: wattles, diverticula, polyps, multiparity, human papillomavirus (HPV) and other viruses^(7, 13).

Signs and symptoms of urethral adenocarcinomas are not pathognomonic and appear at an advanced stage of the disease. Among the symptoms are reported hematuria^(4, 9), perineal pain, dysuria, urinary retention^(2, 3), and overflow incontinence⁽⁵⁾. Furthermore, it is possible the occurrence of purulent and malodorous discharge and secondary infections in necrotic tissue. In the asymptomatic stage of the disease, it may appear hard lumps in the labia, bladder neck, vagina and perineum, sites for which metastasis is more common⁽⁵⁾. Metastasis to distant sites are rare^(2, 4).

In middle-aged women or even senile, metaplasia occurs by chronic injury by chemical or mechanical inflammation⁽¹⁴⁾. Intestinal metaplasia is also observed in patients with wattle or polyps in posterior urethra⁽¹⁵⁾. Chronic exposure of the urothelium to urethritis and urinary retention may lead to urethral diverticulum, which in turn may result in intestinal metaplasia, adenoma or adenocarcinoma. The evolution to adenocarcinoma occurs in 6% of cases of urethral diverticulum⁽¹⁶⁾.

Small and distal tumors suggest a better prognosis, in contrast to large tumors in the proximal portion, suggesting an poor prognosis⁽²⁾. Lymphadenopathy secondary to proximal urethral adenocarcinoma (near the bladder neck) is commonly observed and refers to the possibility of recurrence and metastasis to distant sites, such as lung or colorectal. Urethral adenocarcinoma of recurrent cases is causing increased mortality⁽⁴⁾.

The most suitable method for collecting material for biopsy is the urethrocystoscopy. This method, when properly performed can inform tumor extent, location and histology⁽⁵⁾. Magnetic resonance imaging (MRI) is the most commonly used imaging test for staging. Distance staging is recommended primarily for the detection of lesions in the liver and chest (chest and abdomen computed tomography [CT]) if there is an increased satellite nodule⁽¹⁷⁾. For post-surgical staging, the best investigation is the excretory urography⁽¹⁸⁾.

A major challenge is to differentiate between the urethral adenocarcinoma as primary tumor and the metastatic adenocarcinoma of colonic origin. To dispel this doubt, immunohistochemistry is used. The primary urethral adenocarcinoma presents positive immunohistochemistry for cytokeratin-7, which does not occur in the urethral adenocarcinoma of colonic origin. Furthermore, immunohistochemistry for villin is positive in adenocarcinoma of the colon and negative in urothelial adenocarcinoma^(19, 20). Other differential diagnoses for urethral adenocarcinoma are: urothelial carcinoma of the urinary bladder with urethral extension and nephrogenic metaplasia (important differential diagnosis with clear-cell variant)⁽²⁰⁾.

It is difficult to establish a consensus on the optimal therapy due to the rarity of case studies^(2, 4). The managements in vogue are surgical such as tumor excision, radical nephro-ureterectomy or anterior pelvic exenteration with radiotherapy or chemotherapy complementary^(3, 4). The radical nephro-ureterectomy with the excision of the entire adjacent bulbocavernosus muscle is the only medical conduct that also presents evidence satisfactory to control the disease in T1 and T2 stages, with absence of local spread⁽⁵⁾.

CONCLUSION

This case report illustrates the fact that in patients with symptoms of refractory urinary tract infection recurrent with antibiotic therapy or urethral obstruction, the differential diagnosis of this cancer may be considered. Other reports add that hematuria, whether micro or macroscopic, after ruling out other etiologies, should jointly serve as a warning sign. No less important is to keep in mind the age group in which this type of cancer is more prevalent.

FINAL CONSIDERATIONS

During the publishing process, the patient died due a sepsis of urinary focus by *Klebsiella pneumoniae*.

RESUMO

O adenocarcinoma de uretra é uma rara neoplasia maligna, que ocorre predominantemente em mulheres. Nesse grupo, sua incidência é maior a partir dos 50 anos. O conhecimento acerca da doença é limitado pela sua infreqüência e baseia-se, sobretudo, em relatos de caso. Apesar de raramente apresentar metástase a distância, as consequências clínicas do tratamento dessa condição podem trazer forte impacto negativo na vida da portadora, em decorrência de cirurgias mutiladoras e da necessidade de uso de sonda vesical permanente. Apresenta-se um relato de caso de uma paciente com adenocarcinoma uretral e sua condução terapêutica.

Unitermos: adenocarcinoma; neoplasias uretrais; saúde da mulher; relatos de caso.

REFERENCES

1. Amin MB, Young RH. Primary carcinomas of the urethra. *Semin Diagn Pathol.* 1997; 14: 147-60.
2. Libby B, Chao D, Schneider B. Non-surgical treatment of primary female urethral cancer. *Rare tumors.* 2010; 2(3): e55.
3. Maier U, Dorfinger K, Susani M. Clear cell adenocarcinoma of the female urethra. *J Urol.* 1998; 160(2): 492-3.
4. Miller J, Karnes R. Primary clear-cell adenocarcinoma of the proximal female urethra: case report and review of the literature. *Clin Genitourin Cancer.* 2008; 6(2): 131-3.
5. Karnes RJ, Breau RH, Lightner DJ. Surgery for urethral cancer. *Urol North Am.* 2010; 37(3): 445-57.
6. Visser O, Adolfsson J, Rossi S, et al; The Rarecare Working Group. Incidence and survival of rare urogenital cancers in Europe. *Eur J Cancer.* 2012; 48(4): 456-64.
7. Derksen JW, Visser O, De La Riviere GB, Meuleman EJ, Heldewag EA, Lagerveld BW. Primary urethral carcinoma in females: an epidemiologic study on demographical factors, histological types, tumour stage and survival. *World J Urol.* 2013; 31(1): 147-53.
8. Meis JM, Ayala AG, Johnson DE. Adenocarcinoma of the urethra in women: a clinicopathologic study. *Cancer.* 1987; 60: 1038-52.
9. Trabelsi A, Abdelkrim S, Rammeh S, et al. Clear cell adenocarcinoma of a female urethra: a case report and review of the literature. *N Am J Med Sci.* 2009; 1(6): 321-3.
10. Murphy DP, Pantuck AJ, Amenta PS, et al. Female urethral adenocarcinoma: immunohistochemical evidence of more than 1 tissue of origin. *J Urol.* 1999; 161: 1881-4.
11. Chan YM, Ka-Leung Cheng D, Nga-Yin Cheung A, Yuen-Sheung Ngah H, Wong LC. Female urethral adenocarcinoma arising from urethritis glandularis. *Gynecol Oncol.* 2000; 79: 511-4.
12. Thyaviahally Y, Wuntkal R, Bakshi G, Uppin S, Tongaonkar H. Primary adenocarcinomas of the female urethra: single center experience of 18 cases. *Jpn J Clin Oncol.* 2005; 35(2): 84-7.
13. Grisby P, Herr H. Urethral tumours. In: Vogelzang N, Shipley WU, Scardino PT, Coffey DS, editors. *Comprehensive textbook of genitourinary oncology.* 2nd edition. Philadelphia: Lippincott Williams & Wilkins; 2000. p. 1133-9.
14. Jarvi OH, Marin S, De Boer WG. Further studies of intestinal heterotopia in urethral caruncle. *Acta Pathol, Microbiol Immunolo Scandina A.* 1984; 92: 469-74.
15. Jaidane M, Hidoussi A, Slama A, Hmida W, Ben Sorba N, Mosbah F. Gastric metaplasia of posterior urethral polyp: a case report. *Cases J.* 2009; 2: 9119.
16. Thomas AA, Rackley RR, Lee U, Goldman HB, Vasavada SP, Hansel DE. Urethral diverticula in 90 female patients: a study on emphasis of neoplastic alterations. *J Urol.* 2008; 180: 2463-7.
17. Gourtsoyianni S, Hudolin T, Sala E, Goldman D, Bochner BH, Hricak H. MRI at the completion of chemoradiotherapy can accurately evaluate the extent of disease in women with advanced urethral carcinoma undergoing anterior pelvic exenteration. *Clin Radiol.* 2011; 66(11): 1072-8.
18. Picozzi S, Ricci C, Gaeta M, et al. Upper urinary tract recurrence following radical cystectomy for bladder cancer: a meta-analysis on 13185 patients. *J Urol.* 2012; 188(6): 2046-54.
19. Tamboli P, Mohsin SK, Hailemariam S, Amin MB. Colonic adenocarcinoma metastatic to the urinary tract with glandular differentiation: a report of 7 cases and investigation using a limited immunohistochemical panel. *Arch Pathol Lab Med.* 2002; 126: 1057-63.
20. Leite KR, Mitteldorf CA, Srougi M, et al. CDX-2, cytokeratin 20, thyroid transcription factor 1 and prostatic specific antigen expression in unusual subtypes of prostate cancer. *Ann Diagn Pathol.* 2008; 12: 260-6.

CORRESPONDING AUTHOR

Sydney Correia Leão
Universidade Federal de São Paulo (Unifesp); Departamento de Patologia; Rua Botucatu, 740; Vila Clementino; CEP: 04038-061; São Paulo-SP, Brasil; e-mail: sydneyleao@hotmail.com.