

Brunner's gland cyst: rare differential diagnosis of dyspeptic symptoms

Cisto da glândula de Brunner: diagnóstico diferencial raro de sintomas dispépticos

Flávio H. Ivano¹⁻³; Victor K. Ivano²⁻³; Larissa Miyashiro²⁻³; Danielle G. Sakamoto⁴; Ana C. L. Sobral⁵

1. Hospital Sugisawa, Curitiba, Paraná, Brazil. 2. Pontifícia Universidade Católica do Paraná (PUCPR), Curitiba, Paraná, Brazil.
3. Santa Casa de Misericórdia de Curitiba, Curitiba, Paraná, Brazil. 4. Laboratório de Patologia Byori, Curitiba, Paraná, Brazil.
5. Faculdade Evangélica Mackenzie do Paraná, Curitiba, Paraná, Brazil.

ABSTRACT

A 60-year-old woman was under investigation of dyspeptic symptoms. The upper gastrointestinal endoscopy showed a cystic subepithelial lesion in the second portion of the duodenum, measuring 8 mm in its longest diameter. The biopsy showed dilated Brunner's gland lobular ducts with scattered stromal elements, what characterized a Brunner's gland cyst. Brunner's gland cyst should be included in the differential diagnosis of gastrointestinal bleeding, dyspepsia, gastroesophageal reflux disease (GERD), malabsorption syndrome, anemia, among others. The correct nomenclature is important to facilitate research for articles specifically related to each duodenal cystic lesions and better understanding of these diseases, as some may have malignant potential.

Key words: duodenal diseases; duodenum; Brunner glands.

RESUMO

Paciente do sexo feminino, 60 anos, com queixas dispépticas. A endoscopia digestiva revelou lesão subepitelial localizada na segunda porção do duodeno com aspecto cístico (sinal da tenda positivo), de 8 mm no seu maior diâmetro. Biópsia da lesão foi realizada. A análise histopatológica mostrou dilatação dos ductos lobulares das glândulas de Brunner, acompanhada por elementos estromais dispersos, caracterizando um cisto da glândula de Brunner. É um diagnóstico diferencial de sangramento intestinal, dispepsia, doença do refluxo gastroesofágico (DRGE), má absorção e anemia. A nomenclatura é importante tanto para a pesquisa de artigos específicos de cada lesão cística no duodeno quanto para melhor caracterização dessas lesões, uma vez que algumas podem apresentar potencial maligno.

Unitermos: duodenopatias; duodeno; glândula de Brunner.

RESUMEN

Paciente femenina, de 60 años de edad, tenía quejas dispépticas. La endoscopia digestiva reveló lesión subepitelial ubicada en la segunda porción del duodeno con aspecto quístico (signo de la tienda de campaña), de 8 mm en su mayor diámetro. Se realizó biopsia de la lesión. El análisis histopatológico mostró dilatación de los ductos lobulares de las glándulas de Brunner, acompañada por elementos estromales dispersos, identificando un quiste de las glándulas duodenales. Es un diagnóstico diferencial de sangrado intestinal, dispepsia, enfermedad por reflujo gastroesofágico (ERGE), malabsorción y anemia. La nomenclatura es importante tanto para buscar artículos específicos de cada lesión quística en el duodeno como para mejor caracterizar esas lesiones, puesto que algunas pueden tener potencial maligno.

Palabras clave: enfermedades duodenales; duodeno; glándulas duodenales.

INTRODUCTION

Brunner's glands are mainly located in the proximal duodenum and are specialized in producing mucin in the mucosa and submucosa, creating a protection against the gastric acid and pancreatic enzymes. They can rarely be found in the pylorus and/or jejunum. At light microscopy, the cells of Brunner's gland are eosinophilic with their nuclei located in the basal portion^(1,2).

Brunner's gland cyst (BGC) can be defined as a cystic dilation of the main duct of a Brunner's gland. Its pathogenesis is still unknown, but the most accepted hypothesis is an obstruction of the main duct, preventing drainage to the crypts of Lieberkühn. The cyst is usually discovered accidentally in upper gastrointestinal endoscopy (UGE) as a submucosal lesion that collapses when it is biopsied^(3,4).

CASE REPORT

A 60-year-old woman, smoker, with fibromyalgia and anxiety under treatment, in December, 2016, presented dyspeptic complaints and symptoms suggesting gastroesophageal reflux disease (GERD), with a normal physical exam. The UGE reported "antral gastritis and subepithelial lesion in the second portion of the duodenum. Elevated and round lesion, covered with normal mucosa, soft texture when pinched, of 8 mm in diameter". The patient was referred to gastroenterology.

In a routine consultation in November, 2017, the dyspeptic complaints persisted, in spite of a normal physical examination and self-medication with pantoprazole. The patient missed a medical appointment, but returned in December, 2017, with a new UGE, colonoscopy, abdominal ultrasound and laboratory tests. The reports were: "normal colonoscopy with grade II internal hemorrhoids; superficial erosive gastritis mainly in the gastric body covered with hematin. Subepithelial lesion in the second portion of the duodenum with a cystic aspect (tent sign) and the same diameter as the previous exam (**Figure 1**). Urease negative". In this appointment, she was medicated with esomeprazole 40 mg, received dietary orientation and had follow-up visits with endoscopic exams arranged.

The histopathological analysis (**Figures 2 and 3**) showed: dilation of Brunner's gland lobular ducts with scattered stromal elements. Duodenal surface with habitual aspect.

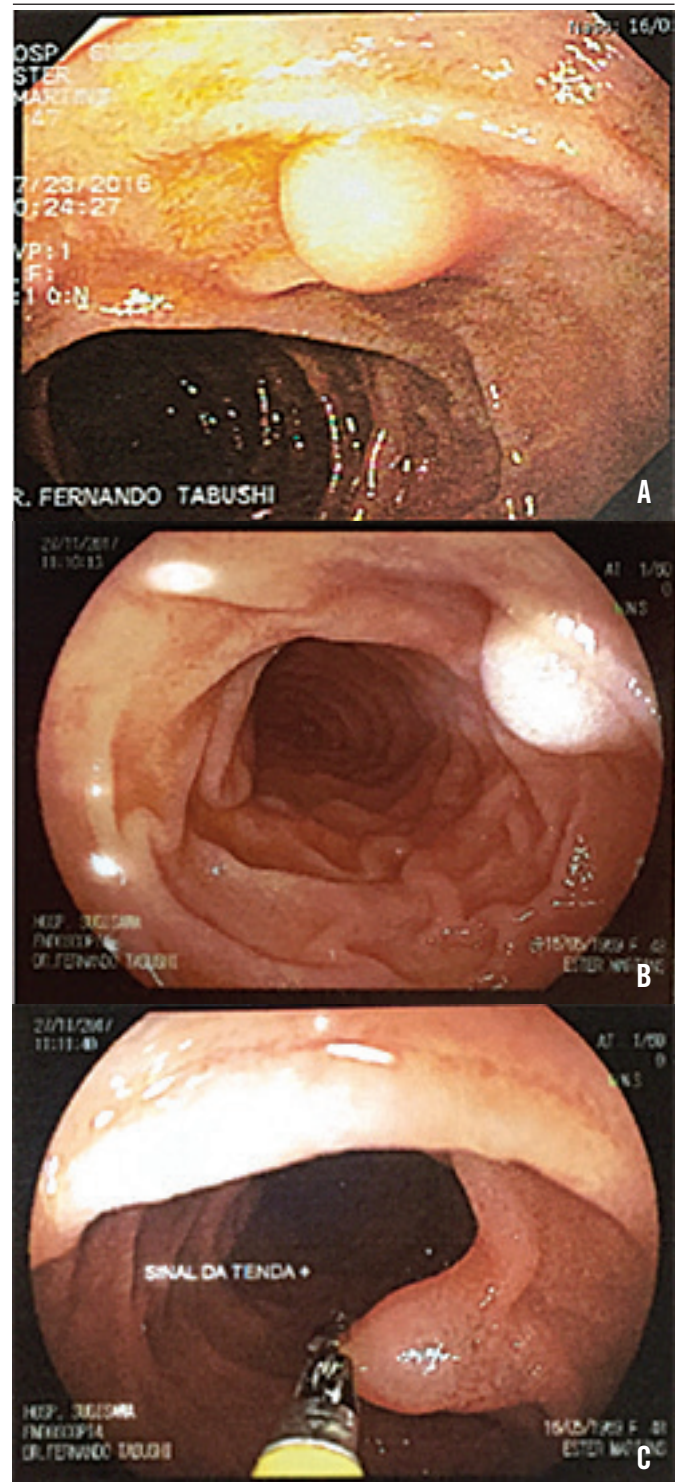


FIGURE 1 – A) duodenal cyst in 2016; B) duodenal cyst in 2017; C) duodenal cyst in 2017

We performed different searches in the US National Library of Medicine (PubMed) and Literatura Latino-Americana e do Caribe em Ciências da Saúde (LILACS) using terms related to *Brunner*, *Brunner's gland*, *Brunner's gland cyst*. The results were case

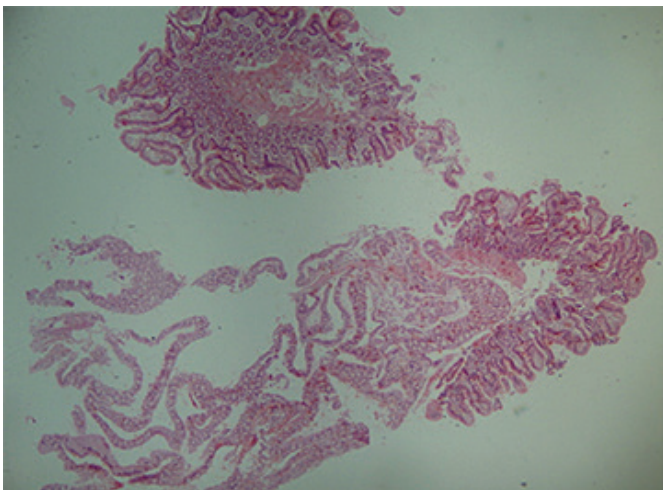


FIGURE 2 – Dilation of Brunner's gland lobular ducts with scattered stromal elements. Duodenal surface with habitual aspect (HE, 40×)

HE: hematoxylin and eosin.

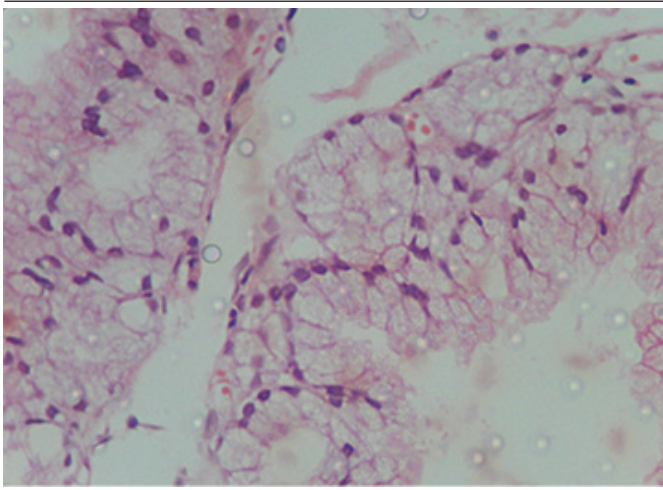


FIGURE 3 – Brunner's gland cysts covered with mucosecretory columnar epithelium without atypia (HE, 400×)

HE: hematoxylin and eosin.

reports and others descriptions of cystic lesions of the Brunner's glands. There were no Brazilian reports of BGC. This study was conducted according to the ethic guidelines for clinical studies of the Ministry of Health. The local ethics committee approved the protocol. The patient was not directly asked because the whole information was obtained from medical reports, protecting the patient's anonymity and ensuring confidentiality of the collected data.

DISCUSSION

The Brunner's gland lesions in the duodenum, characterized as masses, nodules and polyps, are rare. The main causes are

Brunner's gland adenoma, hyperplasia or hamartoma. These lesions may occasionally lead to obstructive symptoms and haemorrhagic cases, but they are in general diagnosed during investigation of dysphagia, odynophagia, iron-deficiency anemia, abdominal pain, steatorrhea, and retrosternal burning sensation⁽⁵⁾.

Specifically, the BGC may present as a sessile formation or pedunculated polyp and at times, as a duodenal mass⁽⁶⁾. They follow a benign course and can be treated endoscopically or with surgery according to size, location, patients' comorbidities or clinical condition⁽³⁾.

The nomenclature of Brunner's gland lesions is not well established, due to constant confusion between terms: Brunner's gland cyst, Brunner's cyst, mucocele of a Brunner's gland, cystic Brunner's gland hamartoma, cystic adenoma^(1, 5, 6). This variety of terms has led to misdiagnosis and obstacles to research, since many authors consider all these terms the same entity. However, with the correct histological definition, we can observe that they are different lesions, each with its particularities. For example, the cystic Brunner's gland lesions were first described as benign, but recent reports showed that the hamartoma, specifically, may have a malignant potential. On the other hand, the BGC has no reports of unfavorable characteristics or atypias. Therefore, the correct definitions should be: hyperplasia is defined as multiple small polypoid or nodular lesions composed of excessive Brunner's glands separated by fibrous septa⁽¹⁾. The hamartoma is a solitary mass made up of a mixture of acini, ducts, smooth muscle, adipose tissue, lymphoid tissue, respiratory epithelium and occasionally heterotopic pancreatic acini and ducts^(1, 6). The adenoma is a term now in disuse because there were no reports of atypias and it is histologically similar to the hamartoma. The BGC is defined as a cystic dilation of the main duct of a Brunner's gland⁽¹⁾. A mild dilation may be present in other cystic lesions, but the most characteristic findings of hamartoma, adenoma or hyperplasia are hyperplastic acini lobes without cystic dilation.

Most articles are case reports of few patients. The largest case study of BGC has 25 patients from Queensland University, Brisbane, Australia. That report had a median age of 67.5 years and the sex ratio was approximately equal (56% in men). The diagnoses were made in three patients during UGE due to epigastralgia, two patients with Barret's esophagus follow-up, three patients with reflux complaints, three investigations of anemia, two patients with duodenal thickening in computed tomography (CT)-scan, and two patients with adenoma follow-up. The lesions varied from 1 mm to 10 mm (mean 4.2 mm), 18 lesions were unilocular, but all surrounded by native Brunner's glands. The authors inform that the cyst is an accidental finding and does not require a

follow-up with biopsy or any further investigation, even if it is not completely removed. Furthermore, Brown and Miller (2017)⁽²⁾ believe that the cyst may be underdiagnosed, because almost 28% of the 25 cases were demonstrated in deeper levels beyond the routinely cut. Another explanation could be from the collapse of the cyst during biopsy.

This case report corroborates the inclusion of BGC in differential diagnosis by gastroenterologists, endoscopists and pathologists. Besides, we emphasize the use of the correct nomenclature to facilitate further research for each cystic lesion and its better characterization, since some may have malignant potential.

REFERENCES

1. Patel ND, Levy AD, Mehrotra AK, Sobin LH. Brunner's gland hyperplasia and hamartoma: imaging features with clinicopathologic correlation. *AJR Am J Roentgenol.* 2006; 715-22. PubMed PMID: 16928936.
2. Brown IS, Miller GC. Brunner's gland cyst: a clinicopathological study of 25 cases highlighting an underappreciated lesion. *Pathology.* 2017; 1-3. PubMed PMID: 28663083.
3. Galiatsatos P. Clinical challenges and images in GI: a case of mistaken lipoma. *YGAST.* Elsevier Inc.; 2011; 141(4): 1159, 1160, 1533.
4. Hatley W. Case reports. Cyst of Brunner's glands. 1968; *Br J Radiol.* 41(485): 384-5. PubMed PMID: 5648003.
5. Powers M, Sayuk GS, Wang HL. Case report Brunner gland cyst: report of three cases. *Int J Clin Exp Pathol.* 2008; 536-8. PubMed PMID: 18787635.
6. Varnholt H, Gang DL, Desilets DJ, Pantanowitz L. Brunner gland cyst. *Int J Surg Pathol.* 2007; 64-5. PubMed PMID: 17172500.

CORRESPONDING AUTHOR

Flávio Heuta Ivano  0000-0002-6006-2380
e-mail: flavio.ivano@yahoo.com.br



This is an open-access article distributed under the terms of the Creative Commons Attribution License.