

Evaluation of the fetal urine sample through vesicocentesis: an approach to diagnostic and therapeutic application

Avaliação da urina fetal por meio da vesicocentese: uma abordagem com aplicação diagnóstica e terapêutica

Andressa S. Santos¹; Naiane C. Bassani¹; Maiara A. Floriani¹; Paulo Renato Krahl Fell²;
Cristine Dietrich²; Ernani B. Rosa¹; Jamile D. Correia¹; Paulo Ricardo G. Zen^{1,3}; Rafael Fabiano M. Rosa^{1,3}

1. Universidade Federal de Ciências da Saúde de Porto Alegre (UFCSPA), Rio Grande do Sul, Brazil. 2. Hospital Materno-Infantil Presidente Vargas (HMIPV), Rio Grande do Sul, Brazil. 3. Complexo Hospitalar Santa Casa de Porto Alegre (CHSCPA), Rio Grande do Sul, Brazil.

ABSTRACT

We report the case of a fetus with mega-bladder and suspected lower urinary tract obstruction (LUTO). The 20-week pregnancy ultrasound scan showed absence of amniotic fluid (anhydramnios), enlarged bladder, and narrowing of the urethra in the proximal region. At 21 weeks of gestational age, vesicocentesis was performed for relief of obstruction and analysis of biochemical of the fetal urine and karyotyping was carried out, which presented normal result (46,XY). This technique is indicated in cases of severe oligohydramnios or difficulty of placental access and has diagnostic and therapeutic function.

Key words: karyotype; urethral diseases; nephropathy; urological diagnostic techniques.

CASE REPORT

V. G. was a 21-year-old pregnant woman for the first time referred for the high-risk prenatal care due to an alteration in obstetrical ultrasound. There was an image suggestive of mega-bladder. The 20-week ultrasonography (USG) examination showed absence of the amniotic fluid (anhydramnios) and an enlarged bladder with narrowing of the urethra in the proximal region, suggestive of lower urinary tract obstruction (LUTO). At 21 weeks of gestation the fetal bladder was punctured for relief of obstruction, and biochemical and karyotype analysis of the material was performed. The volume of fetal urine removed was 282 ml. There were no complications during or after the procedure. The karyotype was normal (46,XY). The biochemical analysis showed the following results: potassium: 3 mEq/l (reference value: < 3 mEq/l); sodium: 109 mEq/l (reference value: < 100 mEq/l), and chlorides: 93 mEq/l (reference value: < 90 mEq/l), indicative of renal damage. Second-trimester ultrasound showed absence of amniotic fluid; increased echogenicity of the renal parenchyma, and distended bladder with “keyhole signal” (**Figure 1**). Fetal echocardiography

was normal. The 25-week ultrasound also showed severe ascites, pericardial effusion, fetal bladder walls thickening, and the right kidney with diminished dimensions (**Figure 2**). The infant was born through vaginal delivery, at 27 weeks of pregnancy, weighing 1,960 grams and Apgar scores of 1 at first and fifth minutes. The infant had a significant abdominal distention and upper and lower limb deformities (**Figure 3**). He presented respiratory distress and evolved to death about 2 hours after birth.

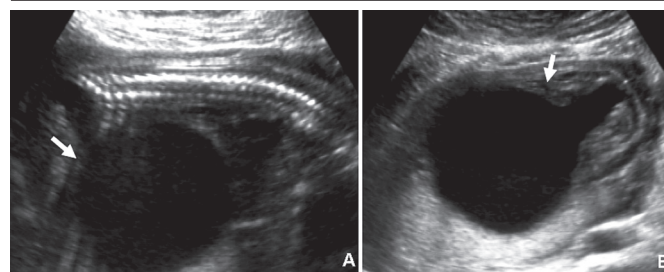


FIGURE 1 – 22-week ultrasound scan showing distended bladder (A) and the keyhole sign (B), suggestive of the LUTO (see white arrows)

LUTO: lower urinary tract obstruction.

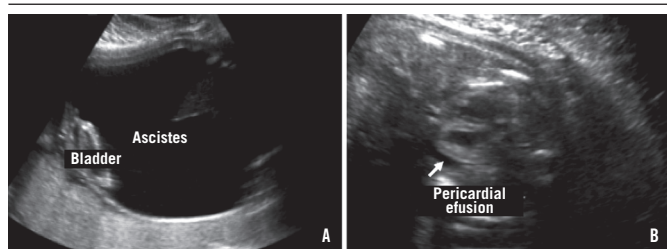


FIGURE 2 – 25-weeks ultrasound scan images showing severe ascites (A) and pericardial effusion (B) (see white arrows)

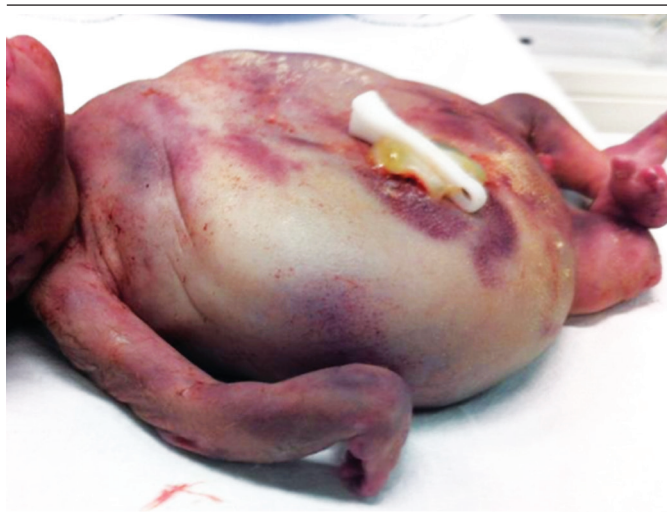

FIGURE 3 – Postnatal physical aspect of the infant showing significant distension of the abdomen and upper and lower limb abnormalities

LUTO comprises a heterogeneous group of pathologies associated with early-onset severe oligohydramnios. Chromosomal abnormalities associated with LUTO include Down syndrome (trisomy 21) and Edwards syndrome (trisomy 18)⁽¹⁻³⁾. Posterior urethral valve (PUV) is considered one of the most common causes of LUTO. PUV can be defined as the presence of membranes that obstruct the urethral lumen, leading to urinary retention and renal damage. It presents an incidence of 1 for every 5,000 to 8,000 live male births. The severity and degree of obstruction caused by PUV depends on the relation between the membrane and the urethra. Prenatal diagnosis

of PUV is based on maternal ultrasound, with evidence, for example, of the “keyhole signal”⁽⁴⁾. Oligohydramnios when associated with LUTO has an estimated mortality rate of 95%. This occurs due to pulmonary hypoplasia caused by the fetal compression secondary to the oligohydramnios. The mortality rate in cases of PUV is directly related to pulmonary insufficiency in 45% of the cases⁽¹⁾.

Fetal urine analysis is an important part of the follow-up after the procedure, as the rate of renal insufficiency among survivors is estimated to be 50%-66%⁽¹⁾. Vesicocentesis is usually performed between the 16th and 32nd gestational weeks using an 18-22G needle guided by USG. The technique is indicated in cases of intense oligohydramnios (impossibility of amniocentesis) or difficulty in access the placenta (impossibility of placental biopsy)⁽⁵⁾. Decreased solute reabsorption, protein catabolism, increased loss of substances in fetal urinary output and the degree of urine hypertonicity have been associated with the extent of the damage. Usually, hypotonic fetal urine becomes concentrated, and elevated levels of sodium, chloride, potassium, phosphate and osmolality have been associated with renal failure and worse outcome. Elevated levels of β 2-microglobulin suggest tubular dysfunction, and is the most sensitive and specific predictor of outcome⁽⁶⁾. Ruano *et al.* (2015)⁽⁷⁾ found that fetuses with severe forms of LUTO and poor renal function do not produce adequate urine output to fill the bladder within two days after the relief puncture.

Fetal urine can also be used to study chromosomes using the karyotype technique⁽⁵⁾. The cell pellet from fetal urine can be cultured and analyzed in a similar way to the technique for amniocytes. The technique includes preparation of the biological material (~ 15-20 ml of fetal urine) for culture, washing cells with the culture medium, incubation and collection of cells to obtain metaphase chromosomes and analysis of the chromosomes. The results should be obtained in 20 days, on average, and the culture performed in 10 to 14 days⁽⁸⁾. Vesicocentesis should be performed several times a week to maintain decompression for treatment purposes, but it presents risks of infection, abortion, rupture of membranes and premature delivery⁽⁵⁾. Therefore, the performance of fetal bladder puncture in these cases has diagnostic and therapeutic function. This procedure can improve the survival through lung development preservation⁽³⁾.

RESUMO

Relatamos o caso de um feto com megabexiga e suspeita de obstrução do trato urinário inferior (LUTO). O exame ultrassonográfico realizado com 20 semanas de gestação mostrou líquido amniótico ausente (adramnia), bexiga com aumento de volume e estreitamento na região da uretra proximal. Na 21ª semana de gestação, foi realizada a vesicocentese para alívio e análise bioquímica e cariotípica da urina fetal, que apresentou resultado normal (46,XY). Essa técnica é indicada em casos de grave oligodramnia ou dificuldade de acesso placentário e tem função diagnóstica e terapêutica.

Unitermos: cariótipo; doenças uretrais; nefropatias; técnicas de diagnóstico urológico.

REFERENCES

1. Wu S, Johnson MP. Fetal lower urinary tract obstruction. *Clin Perinatol.* 2009; 36(2): 377-90.
2. Kilby MD, Morris RK. Fetal therapy for the treatment of congenital bladder neck obstruction. *Nat Rev Urol.* 2014; 11(7): 412-9.
3. Clayton DB, Brock III JW. Lower urinary tract obstruction in the fetus and neonate. *Clin Perinatol.* 2014; 41(3): 643-59.
4. Nasir AA, Ameh EA, Abdur-Rahman LO, Adeniran JO, Abraham MK. Posterior urethral valve. *World J Pediatr.* 2011; 7(3): 205-16.
5. Haeri S, Ruano SH, Farah LMS, Joffe R, Ruano R. Prenatal cytogenetic diagnosis from fetal urine in lower urinary tract obstruction. *Congenital Anomalies.* 2013; 53(2): 89-91.
6. Ralston SJ, Craigo SD. Ultrasound-guided procedures for prenatal diagnosis and therapy. *Obstet Gynecol Clin N Am.* 2004; 31(1): 101-23.
7. Ruano R, Safdar A, Au J, et al. Defining and predicting 'intrauterine fetal renal failure' in congenital lower urinary tract obstruction. *Pediatr Nephrol.* 2015; 31(4): 605-12.
8. Miron PM. Preparation, culture, and analysis of amniotic fluid samples. *Curr Protoc Hum Genet.* 2012. Chapter 8, Unit 8.4.

CORRESPONDING AUTHOR

Rafael Fabiano Machado Rosa

UFCSPA; Rua Sarmiento Leite, 245, sala 403; Centro; CEP 90050-170; Porto Alegre-RS, Brasil; Phone: +55 (51) 3303-8771; e-mail: rfmrosa@gmail.com.