

Errata

O artigo "Solitary plexiform neurofibroma determining pyloric obstruction: a case report", publicado no volume 50, número 3, do Jornal Brasileiro de Patologia e Medicina Laboratorial [JBPML. 2014; 50(3): 238-41], sofreu as seguintes alterações nas Figuras 2 e 3:

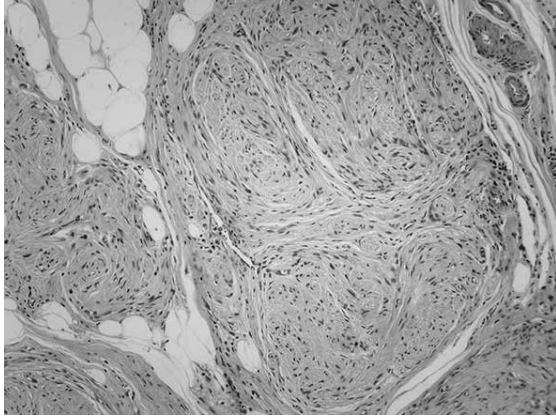


FIGURE 2 – *Plexiform neurofibroma: a benign soft tissue tumor composed of cells which have oval to elongate normochromatic nuclei, expanding the nerve fascicle, HE, 200×*
HE: hematoxylin and eosin stain.

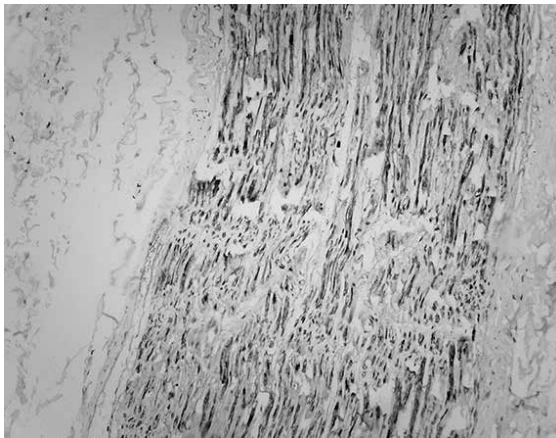


FIGURE 3 – *Plexiform neurofibroma: positive immunoreexpression for S100 antibody, streptavidin-biotin, 200×*