



Management of pericardial cyst in the mediastinum: a single-port approach

Dario Amore¹, Antonio Mazzella¹, Alessandro Izzo², Antonio Cennamo², Fabio Perrotta²

TO THE EDITOR:

Pleuropericardial cysts are relatively infrequent lesions, benign in most cases, representing 7% of all mediastinal tumors.⁽¹⁾ The diagnosis is incidental on chest X-rays in more than 50% of the cases, since clinical symptoms are scarce.⁽²⁾

Pericardial cysts are usually identified in the fourth or fifth decade of life, and they are more frequently located at the right costophrenic angle (in 70% of the cases); the left costophrenic angle (in 10-40%); and the vascular hila, superior mediastinum, or left heart border (in 5-10%).⁽³⁾ The gold standard treatment for the management of those cysts is surgical resection and video-assisted thoracic surgery (VATS), the latter being the best option for these patients.

We report the case of a 55-year-old male admitted to our hospital with an incidental radiological diagnosis of a mass in the anteroinferior mediastinum, measuring 45 mm and developing on the right side. The clinical history of the patient was totally negative, and he referred no clinical symptoms linked to the cyst. In order to diagnose the mass and prevent the risk of complications, the patient underwent complete surgical resection of the cyst by single-port VATS (Figure 1). Under general anesthesia and single-lung ventilation, he the patient was placed in semi-supine position, with a long gel roll placed under the right shoulder. Internal intercostal nerve blocks and continuous elastomeric pump infusion loaded with morphine were used to achieve optimal analgesia.

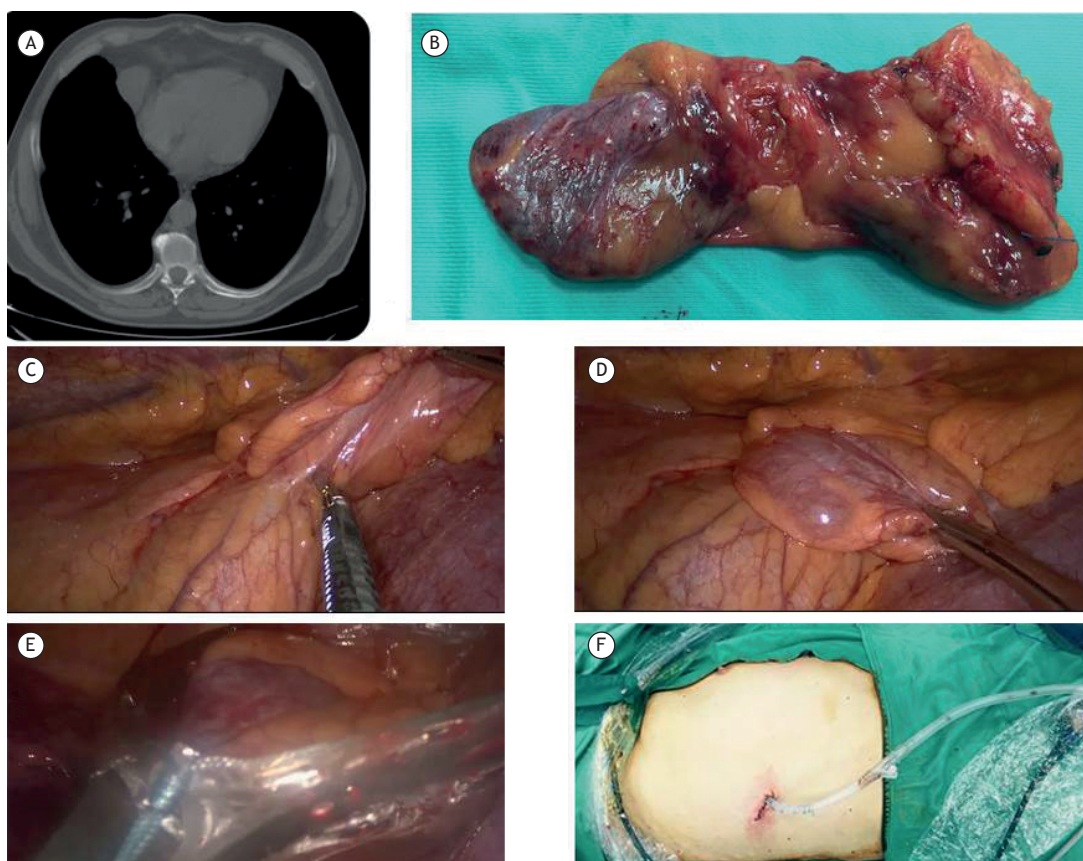


Figure 1. In A, a CT scan revealing anterior mediastinal collection. In B, a photograph of the specimen. In C, a photograph showing the dissection of the cyst with the electronic device. In D, a photograph showing the suspension of the cyst with a ring clamp. In E, a photograph showing the removal of the cyst with the endobag. In F, a photograph showing the 4-cm skin incision with the chest tube inserted.

1. Divisione di Chirurgia Toracica, A.O. dei Colli 'Ospedale Monaldi', Napoli, Italia.

2. Dipartimento di Scienze Cardio-Toraciche e Respiratorie, Seconda Università degli Studi di Napoli, Napoli, Italia.

A 4-cm incision in the sixth intercostal space, on the mid-axillary line, was performed on the right side. A 10-mm, 30° thoracoscope was introduced into the pleural cavity. The complete resection of the cyst and the surrounding mediastinal fat was carried out thanks to the endoscopic instruments and electronic surgical device. The specimen was completely retrieved using an endobag and a 20 Fr chest tube placed at the level of the incision wound (Figure 1); surgical time was 35 minutes. The chest tube was removed on the second postoperative day, and the patient was discharged on the following day.

Macroscopically, the pathological examination revealed a pericardial cyst, measuring 45 × 35 mm.

Pericardial cysts are caused by an incomplete coalescence of fetal lacunae during the development of the pericardium; they might also be acquired after cardiothoracic surgery.⁽⁴⁾ They are usually solitary and adjacent to the pericardium, communicating with it in 20% of the cases. The best treatment is surgical resection, and VATS should be considered as a major method of treatment.

Single-port VATS is gaining more and more importance in thoracic surgery practice. This approach has been described in the literature for the management of primary pneumothorax, as well as for performing wedges, lobectomies, or more invasive procedures, such as sleeve lobectomies.⁽⁵⁾ A recent study demonstrated, in a cohort of 29 patients, the safety of this technique in the management of anterior mediastinal masses.⁽⁶⁾

In our case, the single-port approach allowed perfect control of mediastinal structures, as well as of the right lung, followed by the cyst excision. A ring clamp permitted the suspension of the cyst for its dissection and entire removal, avoiding damage to the capsule, which subsequently might cause fluid spilling into the thorax. The minimal invasiveness of this technique, together with the precise endoscopic dissection, avoided postoperative pleural collection, as well as allowing immediate chest tube removal, and fast discharge of the patient.

When compared with other types of approach, the benefits of uniportal VATS include various aspects: the involvement of only one intercostal space, no spreading of ribs, less postoperative pain, and better aesthetic results.^(5,7,8) The 4-cm skin incision allowed easy introduction and mobilization of all instruments (30° thoracoscope, ring clamp ring, and electronic dissection device). The absence of intraoperative and postoperative complications, as well as of intraoperative blood loss, together with less pain in the early postoperative period, less pulmonary function impairment, and better cosmetic result demonstrate the safety and the superiority of the single-port approach for the treatment of such diseases. However, the correct choice of the approach (thoracotomy, three-port thoracoscopy, or single-port thoracoscopy) depends on the experience of the surgeon and their being comfortable with the technique. In conclusion, single-port VATS might represent the best therapeutic option in the management of pericardial cysts in the mediastinum.

REFERENCES

1. Patel J, Park C, Michaels J, Rosen S, Kort S. Pericardial cyst: case reports and a literature review. *Echocardiography*. 2004;21(3):269-72. <http://dx.doi.org/10.1111/j.0742-2822.2004.03097.x>
2. Nina VJ, Manzano NC, Mendes VG, Salgado Filho N. Giant pericardial cyst: case report. *Rev Bras Cir Cardiovasc*. 2007;22(3):349-51. <http://dx.doi.org/10.1590/S0102-76382007000300013>
3. Yuncu G, Cakan A, Ors Kaya S, Sevinc S, Ucvet A, Ermete S. Atypically located pericardial cysts. *J Cardiovasc Surg (Torino)*. 2001;42(2):275-8.
4. Satur CM, Hsin MK, Dussek JE. Giant pericardial cysts. *Ann Thorac Surg*. 1996;61(1):208-10. [http://dx.doi.org/10.1016/0003-4975\(95\)00720-2](http://dx.doi.org/10.1016/0003-4975(95)00720-2)
5. Gonzalez-Rivas D, Fieira E, Delgado M, de la Torre M, Mendez L, Fernandez R. Uniportal video-assisted thoracoscopic sleeve lobectomy and other complex resections. *J Thorac Dis*. 2014;6(Suppl 6):S674-81.
6. Wu CF, Gonzalez-Rivas D, Wen CT, Liu YH, Wu YC, Chao YK, et al. Single-port video-assisted thoracoscopic mediastinal tumour resection. *Interact Cardiovasc Thorac Surg*. 2015;21(5):644-9. <http://dx.doi.org/10.1093/icvts/ivv224>
7. Mazzella A, Izzo A, Amore D, Cerqua FS, Perrotta F. A new perspective on the treatment of complicated giant emphysematous bulla. A case report. *Ann Ital Chir*. 2016;87(ePub). pii: S2239253X16024816.
8. Mazzella A, Izzo A, Amore D, Cennamo A, Cerqua FS, Perrotta F. Single port VATS resection of a sessile solitary fibrous tumour of the visceral pleura. A case report. *Ann Ital Chir*. 2015;86(ePub). pii: S2239253X15024457.