

Case Report

Dendriform pulmonary ossification*

ANDREZZA ARAÚJO DE OLIVEIRA DUARTE¹, JORGE NAKATANI², MOACYR PEZATI RIGUEIRO³, TÂNIA SAAD⁴

ABSTRACT

Diffuse pulmonary ossification is a rare condition of unknown pathogenesis in which mature bone is found in the pulmonary parenchyma. It is almost invariably discovered as an incidental finding at autopsy. Most commonly, it affects middle-aged men and is asymptomatic. We present the case of a 75-year-old man in which the chest X-ray showed diffuse interstitial infiltrate. Diagnosis was based on histopathological examination by open-lung biopsy, which revealed interstitial fibrosis with pulmonary ossification.

Keywords: Ossification, heterotopic; Lung diseases; Lung/radiography; Pulmonary fibrosis/pathology; Case reports [publication type]

INTRODUCTION

Pulmonary ossification is a rare condition in which metaplastic bone is found in the connective tissues of the interalveolar, interlobular and subpleural spaces, as well as in the pulmonary alveoli.⁽¹⁾The condition rarely produces symptoms, and radiographic findings tend to be masked by underlying pulmonary diseases. Therefore, most of the cases have been diagnosed at autopsy.⁽²⁻³⁾ Since it was first described by Luschka in 1856,⁽⁴⁻⁸⁾ fewer than 100 cases have been reported.

CASE REPORT

A 75-year-old male smoker (50 pack-years) and former metal worker sought treatment presenting

progressive dyspnea for four months. His condition had worsened one week prior, and, upon examination, he presented dyspnea upon exertion. The patient reported right-sided chest pain and dry cough. He had a history of diabetes mellitus, non-dialysis dependent chronic renal insufficiency, systemic arterial hypertension, and ischemic cardiomyopathy.

Physical examination revealed dyspnea (respiratory frequency of 30 breaths per minute), tachycardia (heart rate of 120 beats per minute), Velcro rales in the bases, hypophonesis of the heart sounds, and edema (+/4+) in the lower limbs.

A chest X-ray (Figure 1) showed retractile interstitial infiltrate in the lung bases, rectification of the hemidiaphragm with ill-defined borders, diffuse increase in pulmonary transparency in the upper and middle lobes, and enlarged cardiac image, as well as

*Study carried out at the Santa Marcelina Hospital; and at the Universidade Federal de São Paulo (UNIFESP, Federal University of São Paulo), São Paulo, São Paulo, Brazil

1. Resident in Pulmonology of the Santa Marcelina Hospital, São Paulo, São Paulo, Brazil

2. Adjunct Professor in Pulmonology at the Universidade Federal de São Paulo (UNIFESP, Federal University of São Paulo); Chief of the Pulmonology Department of the Santa Marcelina Hospital, São Paulo, São Paulo, Brazil

3. PhD in Pathology from the Universidade Federal de São Paulo (UNIFESP, Federal University of São Paulo); Pathologist at the Santa Marcelina Hospital, São Paulo, São Paulo, Brazil

4. Preceptor for the Pulmonology Department of the Santa Marcelina Hospital, São Paulo, São Paulo, Brazil

Correspondence to: Andrezza Araújo de Oliveira Duarte. Av. Sena Madureira, 1.123, Apt. 171, Vila Clementino - CEP 04021-051, São Paulo, SP, Brazil. Phone: 55 11 5575-5474. E-mail: andrezzaemarcio@aol.com

Submitted: 29 January 2005. Accepted, after review: 3 August 2005.

an aorta affected by ectasia and atheromatosis.

A high-resolution computed tomography scan of the chest (Figure 2) revealed the presence of retractile reticular interstitial infiltrate in the lower lobes, as well as thickening of the interlobular septa accompanied by an evident calcium component to the left, centrilobular emphysema in the upper lobes, left pleural thickening, an aorta affected by ectasia/atheromatosis, and normal cardiac region.

Spirometry revealed mixed respiratory disorder. Laboratory tests presented the following results: leukocyte count: 13,000 8/67/0/0/16/9; creatinine: 1.83 mg/dl; calcium: 8.8 mg/dl; phosphate: 4.2 mg/dl. Arterial blood gas analysis on room air revealed the following: pH: 7.4; arterial oxygen tension: 78 mmHg; bicarbonate: 27.1 mmHg; arterial carbon dioxide tension: 35.9 mmHg; arterial oxygen saturation: 96.3%.

An echocardiogram revealed an ejection fraction of 0.38, as well as diffuse hypocontractility in the left ventricle without signs of pulmonary hypertension.

The patient received treatment for uncompensated congestive cardiac insufficiency as well as antibiotic therapy for ten days, and there was clinical improvement. However, radiological findings of interstitial involvement and calcifications persisted.

Common causes of interstitial pulmonary diseases

such as collagenosis, occupational diseases, and hypersensitivity pneumonia were ruled out.

The patient was submitted to fiberoptic bronchoscopy, which was suspended due to desaturation of the patient, and transbronchial biopsy was not performed. The culture of the bronchoalveolar lavage fluid was negative for acid-fast bacilli. The patient was then submitted to an open lung biopsy, which revealed acute interstitial fibrosis, without histological patterns of usual or nonspecific interstitial pneumonia, as well as dendriform pulmonary ossification (Figure 3).

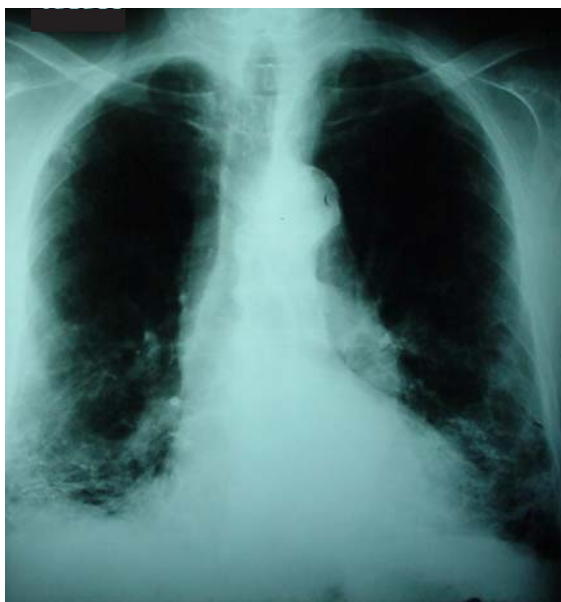

Figure 1 - Chest X-ray with retractile interstitial infiltrate in the lung bases and diffuse increase in pulmonary transparency in the upper and middle lobes. Enlarged cardiac region and an aorta affected by ectasia and atheromatosis

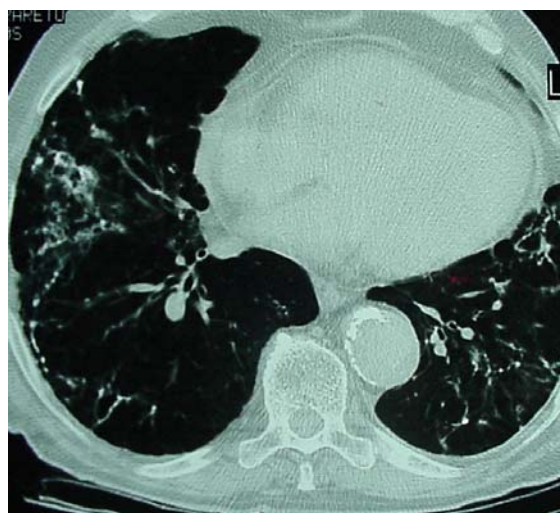


Figure 2 - High-resolution computed tomography scan of the chest revealing retractile reticular interstitial infiltrate in the lower lobes, as well as thickening of the interlobular septa associated with an evident calcium component to the left (tomographic view 2.1 and 2.2)

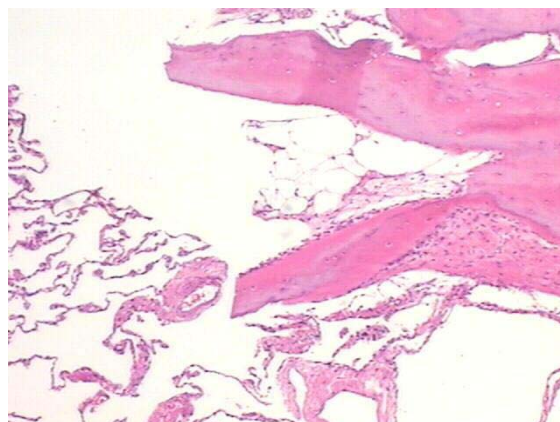


Figure 3 - Pulmonary parenchyma without fibrosis or ossification. Note the medullary space in the center of the bone fragment (H&E $\times 40$)

DISCUSSION

Pulmonary ossification manifests as two histological types (circumscribed or nodular) and can be racemose, ramiform or dendriform. The circumscribed type consists of small nodules of mature lamellar bone in the alveolar spaces, most often found in the subpleural areas of the lower lobes. The bone deposited does not usually contain spinal cord elements.

This type is frequently associated with venous pulmonary hypertension, especially mitral stenosis. The racemose form is composed of linear and ramified bone trabeculae within the alveolar septum and usually contains spinal cord tissue. Most of the cases reported are associated with chronic inflammation, such as organizing interstitial pneumonia.⁽⁹⁾

The histopathological type described herein is the dendriform pulmonary ossification one, also known as: pulmonary osteopathy, idiopathic disseminated pulmonary ossification, ossifying pneumonitis, bone metaplasia of the lung, racemose or reticular osteoplastic pulmonary disease, and arboriform ossification.^(4,10)

Dendriform pulmonary ossification is found associated with several conditions, such as histoplasmosis, chronic therapy with busulfan, pulmonary metastases of osteogenic sarcoma, pulmonary amyloidosis, areas of dystrophic calcifications,^(1,11) and Goodpasture's syndrome.⁽²⁾

The cause most frequently implicated is chronic pulmonary inflammation,^(9,12) which some authors consider to be a special form of idiopathic pulmonary fibrosis.⁽¹²⁾

Other conditions less frequently associated are interstitial pneumonia, lung abscess,⁽¹³⁾ myositis ossificans, cystic fibrosis, hemodialysis, diabetes mellitus, acromegaly, gastric adenocarcinoma, and melanoma.⁽¹⁴⁾ Dendriform pulmonary ossification is also related to recurrent lung damage, such as that resulting from bronchopneumonia and anthracosis.⁽¹⁵⁾

Although ossification of the bronchial cartilage in tuberculosis scars or other scars is a common process, diffuse forms of such ossification are rare.⁽¹⁶⁾ Dendriform pulmonary ossification is more frequently found in men in their 40s, 50s, and 60s. The lower lobes are most often affected.⁽¹²⁾ It has also been described in younger men and in women.⁽⁶⁾

Serum levels of calcium, phosphate, and alkaline phosphatase are normal. There is no evidence of parathyroid diseases or other conditions causing metastatic calcinosis.⁽⁴⁾ Pulmonary function test results show a restrictive pattern, with a decrease in the diffusing capacity. The definite diagnosis is made through open lung biopsy.⁽⁶⁾

Imaging results show reticular infiltrates of calcified density (dendriform type) throughout the bronchovascular distribution. These infiltrates are commonly interpreted as scars, fibrosis, bronchiectasis, or multiple subpleural calcifications (nodular type) smaller than 1 cm, which are mistaken for scars resulting from infectious diseases.⁽⁴⁾

Ossifications have been histologically described six months after the onset of the congestive symptoms, although the process might only be seen radiographically after three to five years.⁽²⁾ The lesions are indolent, with slow progression over the years, and may remain unchanged for many years.

Regression has not been described.⁽⁴⁾

The pathogenesis of the disease is unknown.

Some theories have been put forth in order to explain the finding of bone tissue in the pulmonary parenchyma.

The interaction, in an acid medium under anoxic conditions, of interstitial fibroblasts and fibrins and intra-alveolar platelets that exude into the intra-alveolar space, due to the destruction and alteration of the permeability of the alveolar capillaries, would result in metaplasia from fibroblasts to osteoblasts and the subsequent transition of collagen to the bone matrix.^(3,10)

Some authors have reported metaplasia in pre-existing interstitial fibrosis as well as the fact that it may occur without preceding calcification.⁽¹¹⁾ Others have described calcification as a precursor factor of ossification.⁽¹⁶⁾ Others suggest a transition of cartilage to the bone.⁽¹⁷⁾ Others believe that pulmonary congestion and small recurring hemorrhages with deposit of hemosiderin are some of the main causes of the disease.

It has been reported that the transforming growth factor, one of the post inflammatory mediators, can induce the proliferation of fibroblasts with the synthesis of collagen and other proteins of the extracellular matrix.

The transforming growth factor presents a sequence of proteins that are homologous to those

found in the bone morphogenesis, with a possibility of ectopic bone formation.⁽⁸⁾

The occurrence of the same type of dendriform pulmonary ossification in two members of the same family has been observed, which suggests a strong genetic involvement in the progression of the ossification.⁽¹⁷⁾ There is no known treatment for the disease.^(6,8)

In the present case, the radiographic and anatomopathological findings were consistent with a rare form of dendriform pulmonary ossification. The accompanying diseases that were found in this patient, and which are described in the literature, were interstitial fibrosis, diabetes mellitus, and congestive heart failure.

Although the patient had chronic renal insufficiency, this disease was under control, with normal levels of phosphate and calcium, and there was no need for dialysis.

In agreement with findings in the literature, the patient was asymptomatic and, it was only due to a cardiac decompensation and pulmonary infection, which led to the radiographic findings that culminated with the lung biopsy, that the pulmonary ossification was diagnosed while the patient was still alive.

REFERENCES

1. Pear BL. Idiopathic disseminated pulmonary ossification. *Radiology*. 1969;91(4):746-8.
2. Green JD, Harle TS, Greenberg SD, Weg JG, Nevin H, Jenkins DE. Disseminated pulmonary ossification. A case report with demonstration of electron-microscopic features. *Am Rev Respir Dis*. 1970;101(2):293-8.
3. Ikeda Y, Yamashita H, Tamura T. Diffuse pulmonary ossification and recurrent spontaneous pneumothorax in a patient with bronchial asthma. *Respir Med*. 1998;92(6):887-9.
4. Felson B, Schwartz J, Lukin RR, Hawkins HH. Idiopathic pulmonary ossification. *Radiology*. 1984;153(2):303-10.
5. Joines RW, Roggliv VL. Dendriform pulmonary ossification. Report of two cases with unique findings. *Am J Clin Pathol*. 1989;91(4):398-402.
6. Rajjoub S, Altmeyer RB. A case report of idiopathic pulmonary ossification. *W V Med J*. 1998;94(3):143-5.
7. Jaderborg JM, Dunton RF. Rare clinical diagnosis of dendriform pulmonary ossification. *Ann Thorac Surg*. 2001;71(6):2009-11.
8. Trejo O, Xaubet A, Marin-Arguedas A, Torres A, Ramirez J, Luburich P. [Dendriform pulmonary ossification associated with idiopathic pulmonary fibrosis]. *Arch Bronconeumol*. 2002;38(8):399-400. Spanish.
9. Chow LT, Shum BS, Chow WH, Tso CB. Diffuse pulmonary ossification-A rare complication of tuberculosis. *Histopathology*. 1992;20(5):435-7.
10. Ndimbie OK, Williams CR, Lee MW. Dendriform pulmonary ossification. *Arch Pathol Lab Med*. 1987;111(11):1062-4.
11. Popelka CG, Kleinerman J. Diffuse pulmonary ossification. *Arch Intern Med*. 1977;137(4):523-5.
12. Muller KM, Friemann J, Stichnoth E. Dendriform pulmonary ossification. *Pathol Res Pract*. 1980;168(1-3):163-72.
13. Steinmetz D, Flatau E, Daharan M. Pulmonary ossification. *Isr J Med Sci*. 1985;21(8): 703-5.
14. Cordoba A, Jauregui I, Monzon F, Martinez-Peñuela JM. [Dendriform diffuse pulmonary ossification. Report of 2 cases]. *Rev Clin Esp*. 1996;196(11):751-3. Spanish.
15. Fried ED, Godwin TA. Extensive diffuse pulmonary ossification. *Chest*. 1992;102(5):1614-5.
16. Wells HG, Dunlap CE. Disseminated ossification of the lungs. *Arch Pathol Lab Med*. 1943; 35: 420-46.
17. Azuma A, Miyamoto H, Enomoto T, Usuki J, Kudoh S. Familial clustering of dendriform pulmonary ossification. *Sarcoidosis Vasc Diffuse Lung Dis*. 2003;20(2):152-4.