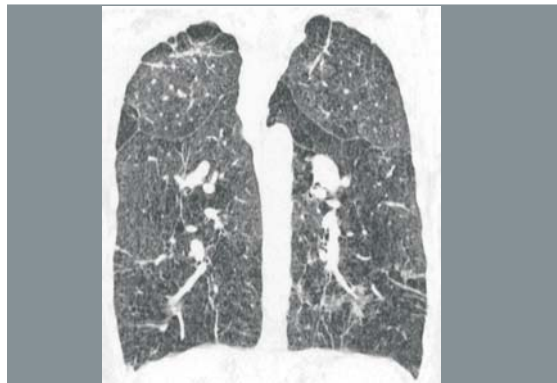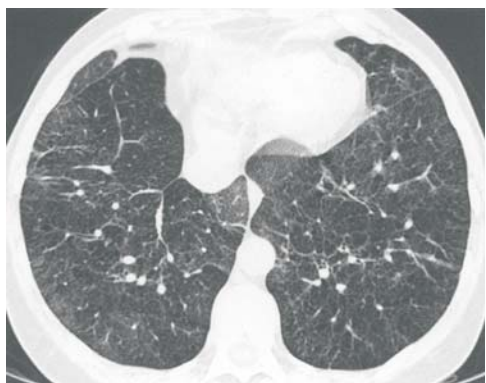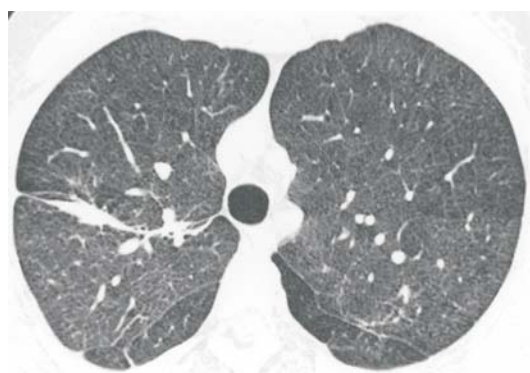


Radiological Diagnosis

We ask: What is the diagnosis?

- 42-year-old Female
- Severe progressive dyspnea
 - Illicit drug user



ISABELA S. SILVA, NESTOR MÜLLER

Department of Radiology, Vancouver General Hospital, University of British Columbia

This section is intended to encourage a diagnostic approach based on clinical and radiographic findings. We invite all of our readers to participate. Submit your diagnosis by completing the form you will find on our website (www.jornaldepneumologia.com.br) or by sending an e-mail to jpneumo@terra.com.br. Remember to include the full name of your institution. In the next issue of the journal, we will publish the diagnosis for this case, along with the names of those who submitted correct responses. The images shown above are those that were most relevant in making the final diagnosis.