

Letter to the Editor

Successful thoracoscopic thymectomy in an infant

Timectomia toracoscópica bem sucedida em um lactente

Damian Palafox, Brenda Tello-López, Miguel Angel Vichido-Luna,
Walid Leonardo Dajer-Fadel, José Palafox

To the Editor:

Minimally invasive surgery is gaining worldwide acceptance for the treatment of mediastinal tumors in children. It has been shown to have several advantages over conventional open surgical approaches. For instance, Lawal et al. showed that thoracoscopy, in comparison with thoracotomy, was associated with significantly fewer midterm musculoskeletal sequelae and a better cosmetic outcome.⁽¹⁾ The authors also found that chest asymmetry in the horizontal plane was significantly less frequent after video-assisted thoracic surgery (VATS) than after conventional surgery (mean relative difference, 0.996 ± 0.003 vs. 0.964 ± 0.008 ; $p < 0.001$), as was scoliosis (9% vs. 54%; $p < 0.001$).⁽¹⁾ Another group of authors demonstrated that undesirable comorbidities, such as rib fusion, deformities of the thorax, and scoliosis, can be avoided using thoracoscopic procedures.⁽²⁾ For anterior mediastinal masses in children, less invasive approaches are preferred, because of the wide spectrum of clinical manifestations associated with such masses.⁽³⁾ Here, we present the case of an eighteen-month-old infant who underwent thoracoscopic thymectomy, which proved to be safe and provided a satisfactory clinical outcome. We believe that it is of the utmost importance that the thoracoscopic approach be promoted to pediatric pulmonologists and thoracic surgeons.

An eighteen-month-old male infant presented with a six-month history of recurrent respiratory infections. He had previously been diagnosed with bronchiolitis, which had been treated with bronchodilators and symptomatic management. However, poor results had been obtained. There was no record of any previous hospitalization, and no imaging studies had been performed before he was referred to our facility. He was hospitalized during an acute episode of severe dyspnea. Simple X-rays showed a widened mediastinum and a mass in the anterior mediastinum. Therefore, CT was performed. The presence of an anterior

mediastinal mass was confirmed. The mass was solid, without any cystic or calcified areas. The results of all laboratory tests were normal, including those for tumor markers. We decided to perform elective surgery based on his history of infections and progressive dyspnea. Other causes of enlarged mediastinum and dyspnea, such as bronchogenic cysts, were ruled out.

We decided to use a thoracoscopic approach. The tumor was found to be thymus-dependent and the surgery therefore consisted of thoracoscopic thymectomy. The patient was anesthetized, and a double-lumen endotracheal tube was used in order to perform single-lung ventilation, which has been shown to be a safe procedure.⁽⁴⁾ We used a left-sided approach. The surgical technique was performed in accordance with one of our previous reports.⁽⁵⁾ In brief, the surgical technique involves the use of three ports; one is placed in the fourth intercostal space in the anterior axillary line; another is placed in the fifth intercostal space in the posterior axillary line; and the third is placed in the seventh space in the anterior axillary line. The camera can be moved from one port to another during the surgery. We begin the procedure with the identification of the phrenic nerve, followed by the dissection of the right inferior pole of the thymus and the placement of vascular clips (one to three) on the thymic veins close to the venous brachiocephalic trunk. We then dissect the left pole in a similar fashion (Figure 1). We continue with gentle cephalic-to-caudal traction of the right superior lobe, placing clips deep into the cervical tissue. Then, the left superior lobe is also dissected in order to complete the excision of the gland (Figure 2). Finally, we resect the mediastinal adipose tissue from the cardiophrenic angle up to the pretracheal and perivascular fat. A chest tube was placed intraoperatively and removed after the first 24 h. The histopathological examination of the tissue confirmed thymoma. The postoperative course

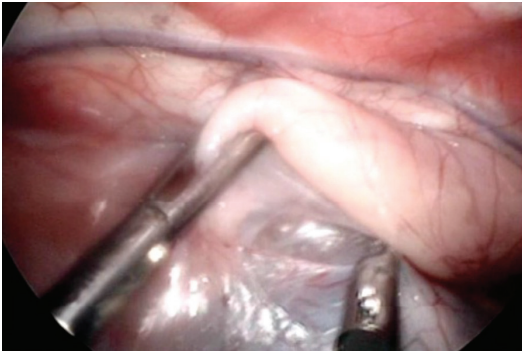


Figure 1 - Placement of vascular clips on the thymic veins prior to the dissection of the left inferior pole.

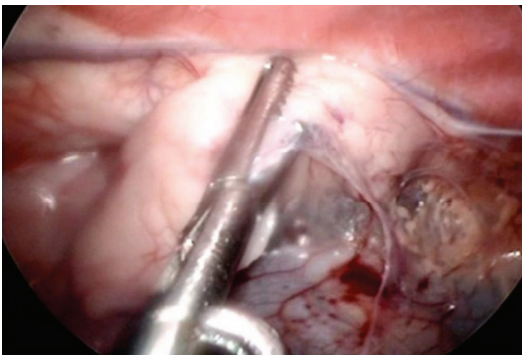


Figure 2 - Clips placed deep into the cervical tissue, with gentle cephalic-to-caudal traction of the right superior lobe applied for the excision of the thymus.

was uneventful, and patient was discharged on the third postoperative day. At this writing (seven months after discharge), the patient remained asymptomatic.

To our knowledge, there have been no randomized controlled trials or controlled clinical trials comparing minimally invasive surgery with open surgery for the treatment of thoracic neoplasms in children.⁽⁶⁾ Therefore, we agree with De Lijster et al.,⁽⁶⁾ who stated that no definitive conclusions or statements can be made regarding the role of minimally invasive thoracic surgery in infants. However, there have been several reports of cases in which minimally invasive thoracic surgery provided positive outcomes in infants. In fact, Ure et al. conducted a state of the art study on the use of VATS for the treatment of thoracic conditions in children.⁽⁷⁾ In general terms, thoracoscopic thymectomy has long been successfully performed in young patients with myasthenia, and the

results have been satisfactory.⁽⁸⁻¹⁰⁾ Regarding the side of the surgical approach, in general terms, left thoracoscopic thymectomy is associated with a lower risk of vena cava injury during surgical manipulation and while gaining access to the aortopulmonary window. However, it has been reported that right thoracoscopy allows better surgical manipulation because of the larger dimensions of the right pleural cavity and easier identification of the innominate vein. We particularly prefer the left-sided approach, because it provides adequate visualization of vascular and nervous structures. The decision to perform or not perform the procedure should be made only after careful study of the case in question. An enlarged thymus alone does not constitute an indication for surgery. In our experience with pediatric patients, thoracoscopy and VATS have both ultimately been related to less postoperative pain, less thoracic trauma, shorter hospital stays, better cosmetic results, and less midterm musculoskeletal sequelae, making it possible to perform the resection of the gland safely, with similar clinical results and better acceptance by patients and parents alike.

Damian Palafox

Resident in Surgery, General Hospital of Mexico, Mexico City, Mexico

Brenda Tello-López

Resident in Pediatrics, Federico Gómez Children's Hospital of Mexico, Mexico City, Mexico

Miguel Angel Vichido-Luna

Resident in Pediatrics, National Institute of Pediatrics, Mexico City, Mexico

Walid Leonardo Dajer-Fadel

Resident in Cardiothoracic Surgery, General Hospital of Mexico, Mexico City, Mexico

José Palafox

Chief, Thoracic Surgery Unit, Center for Respiratory and Allergic Diseases, Xalapa, Mexico

References

1. Lawal TA, Gosemann JH, Kuebler JF, Glüer S, Ure BM. Thoracoscopy versus thoracotomy improves midterm musculoskeletal status and cosmesis in infants and children. *Ann Thorac Surg.* 2009;87(1):224-8.
2. Fuchs J, Kirschner HJ, Warmann SW, Schellinger K, Baden W, Szavay P. Thoracoscopic anatomical lung resection in children [Article in German]. *Zentralbl Chir.* 2007;132(3):247-50.
3. Garey CL, Laituri CA, Valusek PA, St Peter SD, Snyder CL. Management of anterior mediastinal masses in children. *Eur J Pediatr Surg.* 2011;21(5):310-3.
4. Bataineh ZA, Zoeller C, Dingemann C, Osthaus A, Suempelmann R, Ure B. Our experience with single lung ventilation in thoracoscopic paediatric surgery. *Eur J Pediatr Surg.* 2012;22(1):17-20.
5. Palafox D, Palafox J. The usefulness of thoracoscopic thymectomy for myasthenia gravis [Article in Spanish]. *Rev Med Hosp Gen Mex.* 2012;75(1):9-13
6. de Lijster MS, Bergevoet RM, van Dalen EC, Michiels EM, Caron HN, Kremer LC, et al. Minimally invasive surgery versus open surgery for the treatment of solid abdominal and thoracic neoplasms in children. *Cochrane Database Syst Rev.* 2012;1:CD008403.
7. Ure BM, Schmidt AI, Jesch NK. Thoracoscopic surgery in infants and children. *Eur J Pediatr Surg.* 2005;15(5):314-8.
8. Wagner AJ, Cortes RA, Strober J, Grethel EJ, Clifton MS, Harrison MR, et al. Long-term follow-up after thymectomy for myasthenia gravis: thoracoscopic vs open. *J Pediatr Surg.* 2006;41(1):50-4; discussion 50-4.
9. Segquier-Lipszyc E, Bonnard A, Evrard P, Garel C, De Ribier A, Aigrain Y, et al. Left thoracoscopic thymectomy in children. *Surg Endosc.* 2005;19(1):140-2.
10. Sardenberg RA, Abadalla RZ, Abreu IR, Evaristo EF, Younes RN. Robotic thymectomy for myasthenia gravis. *J Bras Pneumol.* 2011;37(5):694-6.