

Case Report

Cystic lymphangioma of the mediastinum*

Linfangioma cístico do mediastino

Filipa Maria Arruda Viveiros Correia¹, Bárbara Seabra¹, Ana Rego¹, Raquel Duarte², José Miranda³

Abstract

Cystic lymphangioma is a rare congenital benign tumor. It results from focal proliferation of well-differentiated lymphatic tissue originating from abnormal development of the lymphatic system. Most cystic lymphangiomas occur in the primitive lymph sacs of children or young adults. They generally appear in the neck (75%) and axillary region (20%). Only 1% are located in the mediastinum. Acquired lymphangiomas, which are principally seen in middle-aged adults, are caused by a process of chronic lymphatic obstruction secondary to surgery, chronic infection, or radiation. Here, we present the case of a 50-year-old male with cystic lymphangioma of the mediastinum, detected on a routine chest X-ray.

Keywords: Lymphangioma, cystic; Mediastinum; Incidental findings.

Resumo

O linfangioma cístico é um tumor congênito benigno e raro. Resulta da proliferação focal de tecido linfático bem diferenciado com origem num anormal desenvolvimento do sistema linfático. A maioria ocorre em crianças ou adultos jovens nos sacos linfáticos primordiais. Geralmente ocorrem no pescoço (75%) e na região axilar (20%). Apenas 1% desses são localizados no mediastino. Os linfangiomas adquiridos, principalmente encontrados em adultos de meia-idade, são conseqüentes a um processo de obstrução linfática crônica secundária a cirurgia, infecção crônica ou radiação. Os autores apresentam um caso clínico de linfangioma cístico do mediastino num indivíduo do sexo masculino de 50 anos, detectado por achado em radiografia de tórax de rotina.

Descritores: Linfangioma cístico; Mediastino; Achados acidentais.

Introduction

Cystic lymphangioma, first described in the literature in 1951, is a rare benign congenital tumor.^(1,2) It results from focal proliferation of well-differentiated lymphatic tissue originating from abnormal development of the lymphatic system.⁽²⁻⁴⁾ Most cystic lymphangiomas occur in the primitive lymph sacs of children or young adults.⁽²⁻⁴⁾ Nearly 90% of the cases are diagnosed at approximately two years of age.^(1,4) They generally appear in the neck (75%) and axillary region (20%). Only 1% are located in the mediastinum.^(1-3,5) They can also be found in the retroperitoneum, pelvis, and chest wall.⁽²⁾ Acquired lymphangiomas, which are principally seen in middle-aged adults,⁽²⁾ are caused by a process of chronic lymphatic obstruction secondary to surgery, chronic infection, or radiation.⁽⁴⁾ Malignant transformation of cystic lymphangiomas has not been described.⁽⁵⁾

Case report

A 50-year-old male smoker (30 pack-years), a car salesman with a history of arterial hypertension and dyslipidemia, sought medical attention. The patient was under regular treatment with simvastatin (20 mg), valsartan (80 mg), lansoprazole (30 mg), and brotizolam (0.25 mg). The patient was referred to a pulmonologist due to the finding of right paratracheal lesion with enlargement of the upper mediastinum on a routine chest X-ray (Figure 1).

The patient was asymptomatic and presented no significant alterations upon physical examination—normal pulmonary auscultation and normal peripheral oxygen saturation. In addition, there was no jugular swelling at 45°. Pulmonary function tests revealed no alterations, and echocardiography was normal. Computed tomography of the chest revealed a right paratracheal mediastinal tumor,

* Study carried out at the Vila Nova de Gaia/Espinho Hospital Center, Porto, Portugal.

1. Assistant Intern in the Department of Pulmonology. Vila Nova de Gaia/Espinho Hospital Center, Porto, Portugal.

2. Attending Physician in the Department of Pulmonology. Vila Nova de Gaia/Espinho Hospital Center, Porto, Portugal.

3. Attending Physician in the Department of Cardiothoracic Surgery. Vila Nova de Gaia/Espinho Hospital Center, Porto, Portugal.

Correspondence to: Filipa Viveiros. Rua Sarmento Beires, 280, Bloco E, hab. 4.11, CP 4250-448, Porto, Portugal.

Tel 351 22 786-5100. E-mail: filipaviveiros@gmail.com

Financial support: None.

Submitted: 18 February 2008. Accepted, after review: 19 March 2008.

4.5 cm in diameter, in contact with the right tracheal wall and causing anterior deviation of the brachiocephalic vein and superior vena cava. The mass had regular borders and spontaneous low density, was homogeneous, and showed no enhancement after administration of contrast medium (Figure 2).

Fiberoptic bronchoscopy, which was chosen in an attempt to investigate the radiological alterations detected, revealed that the trachea was normal, with no signs of extrinsic compression of the right lateral wall, and the carina was unaltered. In addition, the right and left tracheobronchial trees were normal. Bronchoalveolar lavage was also performed to test for neoplastic cells, bacteria, and mycobacteria. All results were negative.

The treatment consisted of a right lateral thoracotomy to excise the right paratracheal cystic lesion, and the surgical sample was sent for anatomicopathological examination. The macroscopic examination of the surgical sample revealed a thin-walled, nodular cystic lesion measuring 4.5 cm in its largest dimension. The lesion presented a smooth external surface, a whitish trabecular lining, and light yellow serous content. Under microscopy, it presented a fibrotic cystic wall and inflammatory infiltrate forming lymphoid follicles, with endothelial lining and with immunoreactivity to anti-CD34 serum (Figure 3).

The postoperative clinical evolution was satisfactory, without complications and without recurrence, as documented by control imaging studies.

Discussion

Cystic lymphangioma of the mediastinum is an extremely rare benign tumor that is underdiagnosed.^(4,5) It presents slow growth and is usually asymptomatic until it reaches dimensions large enough to cause compression of adjacent structures or be a target for secondary infection.^(2,4,5) Its rapid growth can also cause hemorrhage.^(5,6) In symptomatic neonates or children, respiratory impairment can result from compression of the tracheobronchial tract.⁽⁵⁾ In adults, it can present as pneumonia, superior vena cava syndrome, chylothorax, or chylopericardium.^(1,5) Alternatively, it can be an incidental finding in imaging studies.^(1,4,5)

The presumed diagnosis is made based on the detection of a cystic lesion on a chest X-ray or a computed tomography scan of the chest.⁽⁵⁾ On

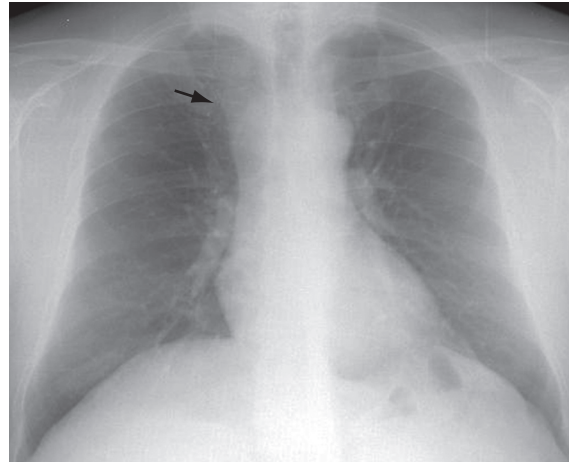


Figure 1 - Chest X-ray showing a right paratracheal opacity (arrow).

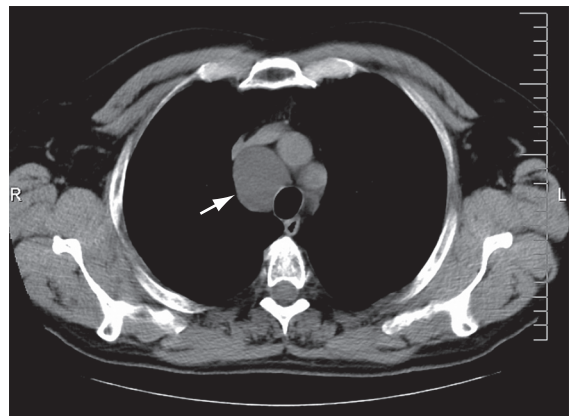


Figure 2 - Computed tomography scan of the chest showing an extensive mediastinal lesion (arrow) in contact with the right tracheal wall and causing anterior deviation of the brachiocephalic vein and superior vena cava.

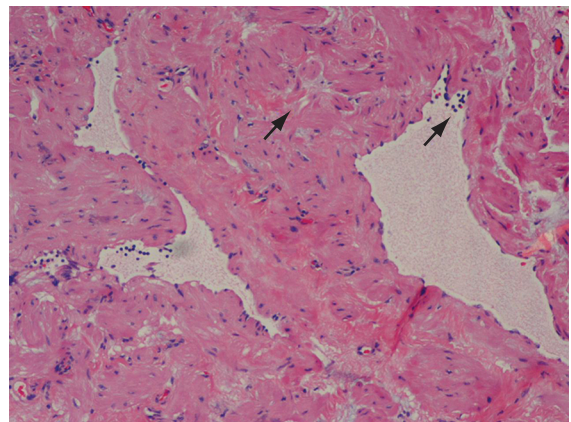


Figure 3 - Photomicrograph of the mediastinal mass, with inflammatory infiltrate forming lymphoid follicles and endothelial lining (arrows).

X-rays, lymphangiomas of the mediastinum appear as well-circumscribed, round masses of homogeneous density,⁽⁵⁾ and computed tomography of the chest demonstrates the involvement or deviation of natural structures, absence of calcification, and various high attenuation areas within the lesion.⁽²⁾

The differential diagnosis should include lymphoma (namely Castleman's lymphoma), thymic cyst, pericardial cyst, bronchogenic cyst, cystic teratoma, cystic thymoma, and aneurysm of the brachiocephalic trunk.^(1,4,5) The definitive diagnosis is made through histopathological examination.^(1,5)

In cases of cystic lymphangioma of the mediastinum, surgical excision is the treatment of choice.^(1,2,5) Although other types of adjuvant treatment, such as radiotherapy or injection of sclerosing agents (OK-432 or bleomycin), have been proposed, they are still controversial.^(1,2)

With complete tumor resection, the prognosis is good, although cases of local recurrence have

been described, especially after partial resection.^(2,3,5) Postoperative complications can include infection, chylothorax, and fistula formation, as well as injury to the phrenic nerve, vagus nerve, lungs, or major vessels.^(2,5)

References

1. Saleiro S, Magalhães A, Moura CS, Hespanhol V. Linfangioma cístico do mediastino. *Rev Port Pneumol.* 2006;12(6):731-5.
2. Yildirim E, Dural K, Kaplan T, Sakinci U. Cystic lymphangioma: report of two atypical cases. *Interact Cardiovasc Thorac Surg.* 2004;3(1):63-5.
3. Bossert T, Gummert JF, Mohr FW. Giant cystic lymphangioma of the mediastinum. *Eur J Cardiothorac Surg.* 2002;21(2):340.
4. Faul JL, Berry GJ, Colby TV, Ruoss SJ, Walter MB, Rosen GD, et al. Thoracic lymphangiomas, lymphangiectasis, lymphangiomatosis, and lymphatic dysplasia syndrome. *Am J Respir Crit Care Med.* 2000;161(3 Pt 1):1037-46.
5. Bilgin M, Akçalı Y, Oğuzkaya F, Öktem T. Mediastinal cystic lymphangioma: a rare mediastinal tumour. *Turkish Respiratory Journal.* 2004;5(3):187-8.
6. Iannicelli E, Alamberger M, Rossi G. Linfangioma cístico del collo in un neonato. *Radiol Med.* 2002;103(4):414-7.