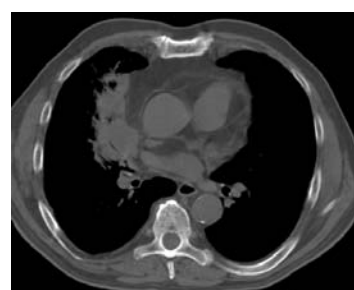
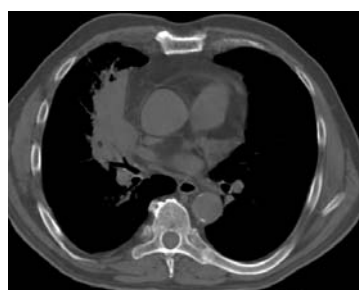
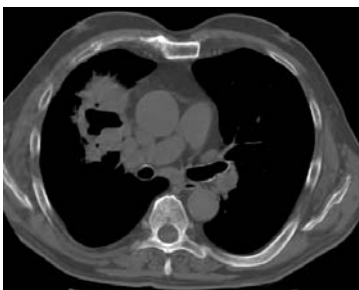
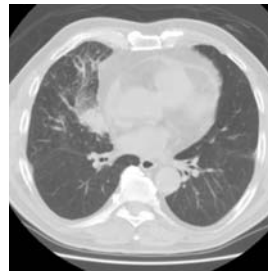
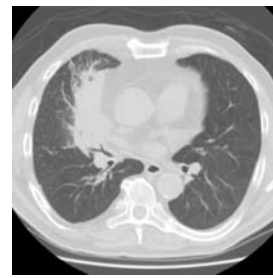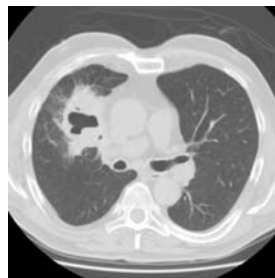

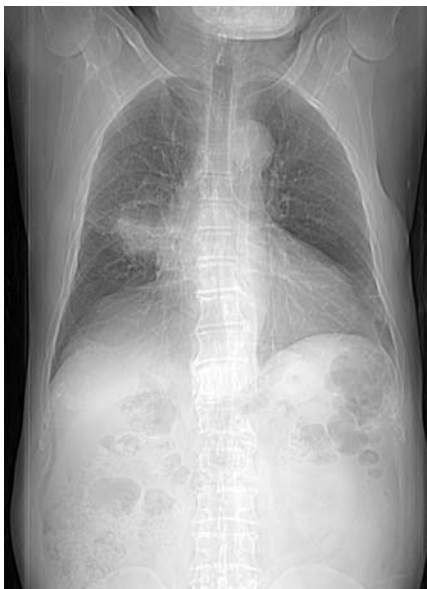
Radiological Diagnosis

We ask: What is the diagnosis?

DANY JASINOWODOLINSKI¹, GILBERTO SZARF², NESTOR L MÜLLER³

Male ex-smoker (40 pack/years),
complaining of productive cough, a 4-kg weight loss in 1 month
and nocturnal fever (37.4°C); no other symptoms.



This section is intended to encourage a diagnostic approach based on clinical and radiographic findings. We invite all of our readers to participate.

Submit your diagnosis by completing the form you will find on our website (www.jornaldepneumologia.com.br) or by sending an e-mail to jpneumo@terra.com.br. Remember to include the full name of your institution. The images shown here are those that were most relevant in making the final diagnosis. The diagnosis for this case, along with the names of readers who submitted correct responses, will be published in the next issue of the journal.

1. Radiologist at the Fleury Diagnostic Medicine Center, São Paulo (SP) Brazil

2. Doctoral student in Radiology at the Universidade Federal de São Paulo (UNIFESP, Federal University at São Paulo), São Paulo (SP) Brazil

3. Full Professor of Radiology at the University of British Columbia, Vancouver, BC, Canada