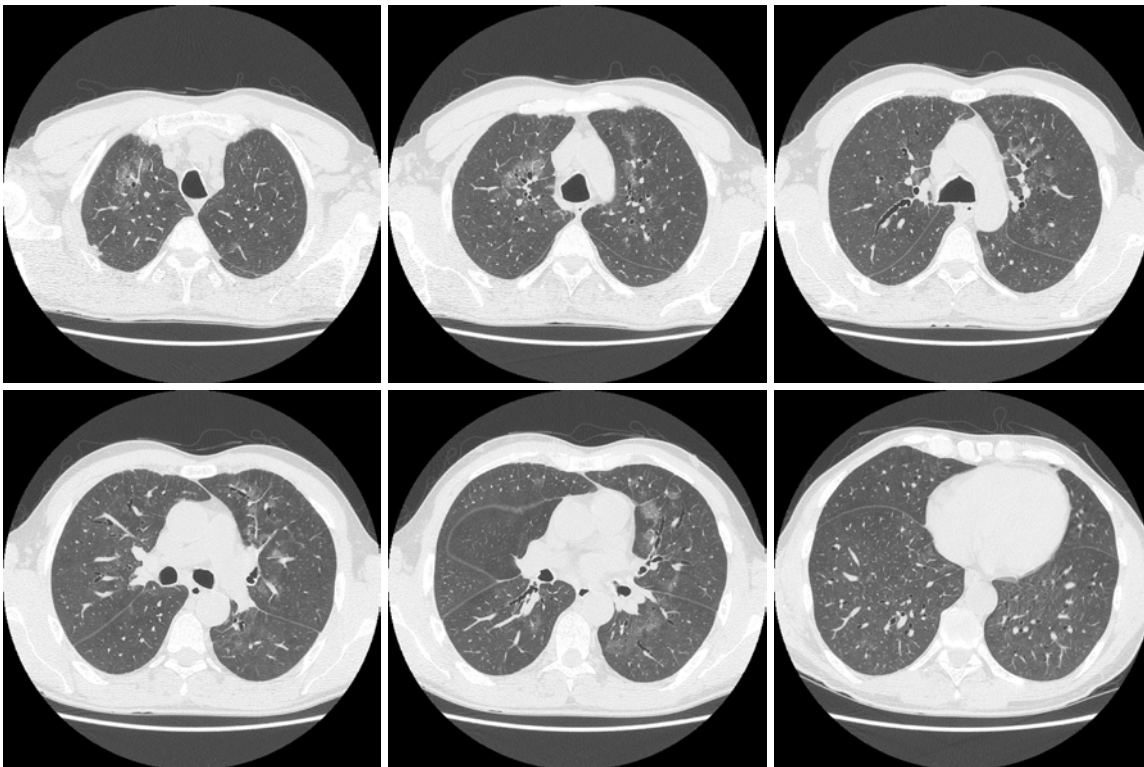


Radiological Diagnosis

We ask: What is the diagnosis?

Dany Jasinowodolinski¹, Gustavo de Souza Portes Meirelles², Nestor L Müller³

A 60-year-old male patient with history of smoking (20 pack-years) reporting myalgia, adynamia, and weight loss of 10 kg in the last 6 months, with progressive dyspnea for 60 days, accompanied by dry cough and without fever. Patient previously healthy, reports no use of medication or exposure to mold/birds.



This section is intended to encourage a diagnostic approach based on clinical and radiographic findings. We invite all of our readers to participate.

Submit your diagnosis by completing the form you will find on our website (www.jornaldepneumologia.com.br) or by sending an e-mail to jpneumo@terra.com.br. Remember to include the full name of your institution. The diagnosis for this case, along with the names of readers who submitted correct responses, will be published in the next issue of the journal. The images shown here are those that were most relevant in making the final diagnosis.

1. Radiologist at the Fleury Center for Diagnostic Medicine, São Paulo, Brazil.

2. PhD in Radiology from the Universidade Federal de São Paulo – UNIFESP, Federal University of São Paulo – São Paulo, Brazil.

3. Full Professor of Radiology at the University of British Columbia, Vancouver, British Columbia, Canada.