

Case Report

Carcinomatous lymphangitis as the initial manifestation of ovarian adenocarcinoma*

Mariane Gonçalves Martynychen¹, Lêda Maria Rabelo²,
Rodney Luiz Frare e Silva², Dante Luiz Escuissato³

Abstract

Carcinomatous lymphangitis accounts for approximately 8% of all cases of metastatic pulmonary tumors. The most common primary sites are breast, lung, stomach, prostate and pancreas. We describe herein the case of a 42-year-old woman in whom the first manifestation of an ovarian adenocarcinoma was carcinomatous lymphangitis of the lung, an unusual presentation of the disease.

Keywords: Lymphangitis; Lung neoplasms; Ovarian neoplasms; Lymphatic metastasis; Hypertension, pulmonary.

Introduction

Carcinomatous lymphangitis accounts for less than 10% of metastatic lung cancers. It is characterized by its distribution throughout the lymphatic vessels, without lung parenchyma remodeling. It is most commonly associated with breast, lung, stomach, colon, pancreas, and prostate cancer. In ovarian adenocarcinoma, carcinomatous lymphangitis occurs in only 6% of cases, typically in cases of recurrences or advanced tumors. We report the case of a 42-year-old female patient who presented pulmonary carcinomatous lymphangitis as the initial manifestation of ovarian adenocarcinoma.

Case report

A 42-year-old white woman reporting chest pain upon breathing and rapidly progressive dyspnea was hospitalized five months after the onset of symptoms. She also reported

dry cough, wheezing, and weight loss of 8 kg since the onset of symptoms. The patient denied a personal or family history of such symptoms. She worked as a teacher, did not smoke, and did not present a history of significant occupational or environmental exposure to smoke. The physical examination revealed tachypnea and tachycardia upon moderate respiratory effort, and pulmonary auscultation revealed diffuse rales and crackles in the lung bases.

The blood workup and metabolic profile were normal. Arterial blood gas analysis on room air revealed the following: pH, 7.40; arterial carbon dioxide tension (PCO₂), 32.2 mmHg; arterial oxygen tension (PO₂), 51 mmHg; bicarbonate (HCO₃), 21; and arterial oxygen saturation (SaO₂), 86.8%. With supplemental oxygen delivered via face mask at 5 L/min, the following values were observed: pH, 7.405; PCO₂, 43.5 mmHg; pO₂, 137.4 mmHg; HCO₃, 26.7; and SaO₂, 98.7%.

* Study carried out at the *Universidade Federal do Paraná* – UFPR, Federal University of Paraná – *Hospital de Clínicas*, Curitiba (PR) Brazil.

1. Resident Physician in the Pulmonology Sector of the *Universidade Federal do Paraná* – UFPR, Federal University of Paraná – *Hospital de Clínicas*, Curitiba (PR) Brazil.

2. Masters in Medicine. Clinical Medicine Department of the *Universidade Federal do Paraná* – UFPR, Federal University of Paraná – *Hospital de Clínicas*, Curitiba (PR) Brazil.

3. PhD in Radiology. Clinical Medicine Department of the *Universidade Federal do Paraná* – UFPR, Federal University of Paraná – *Hospital de Clínicas*, Curitiba (PR) Brazil.

Correspondence to: Mariane Gonçalves Martynychen. Avenida Sete de Setembro, 4214, cj. 1501, CEP 80250-210, Curitiba, PR, Brasil.

Tel 55 41 3233-8083 Fax 55 41 3233-8083. E-mail: marianegm@hotmail.com

Submitted: 30 May 2006. Accepted, after review: 3 October 2006.

Imaging tests carried out three months before in another facility (Figure 1) and during hospitalization (Figure 2) revealed thickening of the interlobular septa and of the bronchovascular cuffs, with multiple nodules distributed perilymphatically. During this interval, there was significant worsening of the pulmonary lesions. Spirometry revealed mixed respiratory disorder. The echocardiogram showed normal heart chambers, and the pulmonary artery systolic pressure was 47 mmHg.

The patient was submitted to fiberoptic bronchoscopy, and the bronchoalveolar lavage fluid tested negative for bacteria, acid-fast bacilli, and fungi. The transbronchial biopsy report noted a well-differentiated adenocarcinoma, with bronchial alveolar characteristics and multiple vascular emboli.

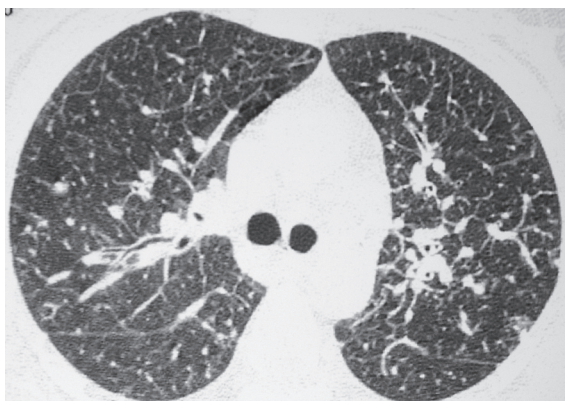


Figure 1 - High-resolution computed tomography slice at the carina shows signs of thickening of the central lung interstitium and interlobular septa. Some small nodules with perilymphatic distribution are also observed.

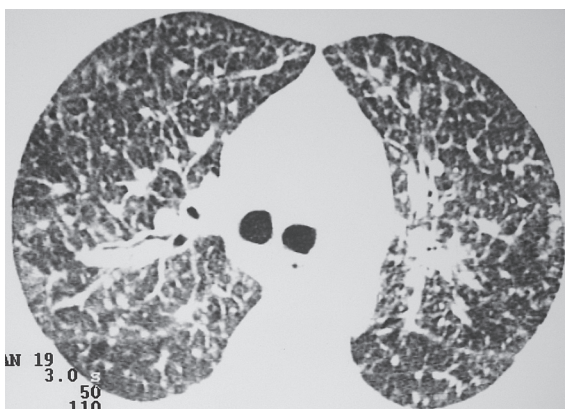


Figure 2 - High-resolution computed tomography slice at the carina shows progression of the alterations described in Figure 1.

In view of this finding, a search for the primary focus of the neoplasia was initiated, and transvaginal pelvic echography showed an expansive, solid, heterogeneous lesion, measuring 5.9 cm x 4.6 cm, in the right paraovarian region, confirmed by a pelvic tomography (Figure 3), suggesting an ovarian neoplasm. Subsequently, immunohistochemical tests showed that the transbronchial biopsy was positive for cancer antigen 125, confirming the ovary as the primary site of the neoplasia.

Chemotherapy with paclitaxel and carboplatin was initiated. The patient was submitted to two cycles of chemotherapy, due to the severity of the clinical profile. After the initiation of chemotherapy, the patient showed progressive improvement, was discharged after a 50-day hospitalization, with peripheral oxygen saturation of 94% on room air, and was referred for outpatient treatment.

Discussion

The first report of pulmonary metastasis dates from 1939 and referred to solitary metastasis of a renal carcinoma.⁽¹⁾ Today, it is known that pulmonary metastases can originate from any primary site, and that 30% of all patients with malignancies will present pulmonary involvement during the evolution of the disease.

Carcinomatous lymphangitis accounts for 6 to 8% of all metastatic lung cancers and is characterized as a diffuse infiltrating neoplasm, with a histological pattern of lymphatic distribution. It typically results from hematological dissemination

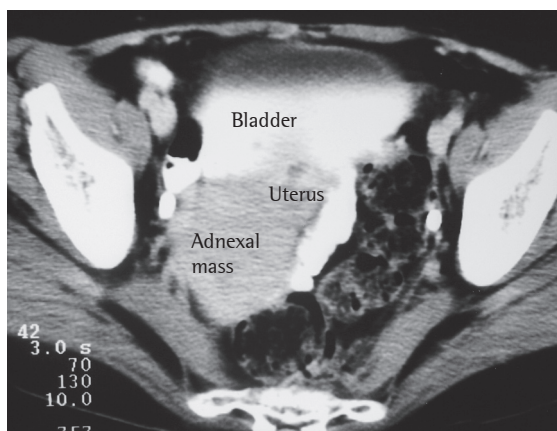


Figure 3 - Computed tomography slice of the pelvis shows a discretely heterogeneous mass in the right ovary, located next to the uterus.

of the primary neoplasia, extending from the capillaries to the lymphatic system, although retrograde dissemination from mediastinal and hilar lymph nodes toward the parenchyma can occur.⁽²⁾

Clinically, there can be dry cough, dyspnea and wheezing, with rapid evolution of symptoms. Tomography scans of the chest reveal thickening of the interlobular septa and bronchovascular cuffs, together with nodules distributed throughout the lymphatic vessels, corresponding, histologically, to the infiltration of internal neoplastic cells. The pulmonary architecture is preserved, with no evidence of lung parenchyma remodeling.⁽³⁾ Pulmonary function tests are useful in making the differential diagnosis and usually show mixed respiratory disorder without diffusional alteration, as well as hypoxemia at rest, without hypercapnia. The diagnosis is typically based on specimens from a transbronchial biopsy or bronchoalveolar lavage.⁽⁴⁾

Carcinomatous lymphangitis typically originates from primary neoplasms in the breast, lung, stomach, colon, prostate, or pancreas. The differential diagnosis should be made with other diseases that preferably present lymphatic dissemination, such as sarcoidosis, lymphoma, leukemia, paracoccidioidomycosis, Kaposi's sarcoma, diffuse pulmonary lymphangiomas, and lymphangiectasia.⁽³⁾

Ovarian adenocarcinoma is not a common primary site of pulmonary carcinomatous lymphangitis, and is even less common when carcinomatous lymphangitis is found as the initial manifestation of the disease. This neoplasia, which accounts for 40% of all cases of cancer, typically presents peritoneal dissemination through metastatic cells in the free peritoneum. Distant metastases rarely occur in the absence of intra-abdominal diseases, and when they are found, they are typically located in the pleura, liver, or lung. Only 8% of patients present metastases at the moment of diagnosis.⁽⁵⁾

Metastases to the chest are very common, generally in advanced stages of the disease. One study reported that 44% of the patients presented some type of intrathoracic involvement, and that pleural effusion occurred in 75% of the cases. Nodules were observed in 28% of the cases, lymph node involvement was seen in 11%, solid pleural lesions were found in 7.5%, and there was involvement of the costal arches in 4%. Carcinomatous lymphangitis

only occurs in 6% of cases. It is typically found in the late phase of the disease and in cases of post-treatment recurrence. Although pulmonary involvement is common, respiratory complaints are rare, constituting the initial symptom in less than 2% of patients.⁽⁶⁾

The prognosis of the disease is poor, with a mean survival of less than two months in patients without treatment.⁽⁷⁾ Therapy aims at improving quality of life and prolonging survival. Currently, chemotherapy includes platinum analogs (cisplatin and carboplatin) and taxanes (paclitaxel and docetaxel).^(8,9) Complete remission occurs in over 50% of patients with advanced disease, although most present recurrence within the first few years after the end of treatment. Survival exceeds 5 years in only 10 to 30% of patients.^(10,11)

References

1. Barney JD, Churchill EJ. Adenocarcinoma of the kidney with metastasis to the lung: cured by nephrectomy and lobectomy. *J Urol.* 1939;(42):269-76.
2. Burt ME. Pulmonary Metastasis. In: Fishman AP, editor. *Fishman's Pulmonary Diseases and Disorders.* 3rd ed. New York: McGraw Hill; 1998. p. 1851-60.
3. Marchiori E, Irion KL, Souza AS. Neoplasias Pulmonares Difusas - Correlação da tomografia computadorizada de alta resolução com a anatomopatologia. *Radiol Bras.* 2002;35(4):225-33.
4. Hominal S, Falchero L, Perol M, Guérin JC. [Carcinomatous lymphangitis]. *Presse Med.* 1999; 28(18): 979-84. Review. French.
5. Cormio G, Rossi C, Cazolla A, Resta L, Loverro G, Greco P, et al. Distant metastases in ovarian carcinoma. *Int J Gynecol Cancer.* 2003;13(2):125-9.
6. Kerr VE, Cadman E. Pulmonary metastases in ovarian cancer. *Cancer.* 1985;56(5):1209-13.
7. Hauser TE, Steer A. Lymphangitic carcinomatosis of the lungs: six case reports and a review of the literature. *Ann Intern Med.* 1951;34(4):881-98.
8. McGuire WP, Hoskins WJ, Brady MF, Kucera PR, Partridge EE, Look KY, et al. Cyclophosphamide and cisplatin compared with paclitaxel and cisplatin in patients with stage III and stage IV ovarian cancer. *N Engl J Med.* 1996;334(1):1-6.
9. Piccart MJ, Bertelsen K, James K, Cassidy J, Mangioni C, Simonsen E, et al. Randomized intergroup trial of cisplatin-paclitaxel versus cisplatin-cyclophosphamide in women with advanced epithelial ovarian cancer: three-year results. *J Natl Cancer Inst.* 2000;92(9):699-708.
10. Ozols RF, Bundy BN, Greer BE, Fowler JM, Clarke-Pearson D, Burger RA, et al. Phase III trial of carboplatin and paclitaxel compared with cisplatin and paclitaxel in patients with optimally resected stage III ovarian cancer: a Gynecologic Oncology Group study. *J Clin Oncol.* 2003;21(17):3194-200.
11. Cannistra SA. Cancer of the ovary. *N Engl J Med.* 2004;351(24):2519-29.